

Short communication

Tumour necrosis factor (TNF) inhibitor therapy in Susac's syndrome

T.A. Hardy^{a,e}, R.J. Garsia^b, G.M. Halmagyi^a, S.J.G. Lewis^{a,c}, B. Harrisberg^d, M.J. Fulham^a, M.H. Barnett^{a,c,*}

^a Department of Neurology, Royal Prince Alfred Hospital, Missenden Rd, Camperdown, NSW, 2050, Australia

^b Department of Immunology, Royal Prince Alfred Hospital, Missenden Rd, Camperdown, NSW, 2050, Australia

^c Brain & Mind Research Institute, 100 Mallett St, Camperdown, NSW, 2050, Australia

^d Department of Ophthalmology, Royal Prince Alfred Hospital, Missenden Rd, Camperdown, NSW, 2050, Australia

^e Department of PET and Nuclear Medicine, Royal Prince Alfred Hospital, Missenden Rd, Camperdown, NSW, 2050, Australia

ARTICLE INFO

Article history:

Received 17 September 2010

Received in revised form 2 November 2010

Accepted 18 November 2010

Available online 17 December 2010

Keywords:

Susac's syndrome

TNF-inhibitor

Corpus callosum

Monoclonal antibody

PET

Pregnancy

ABSTRACT

Susac's syndrome is the clinical triad of encephalopathy, branch retinal artery occlusions and sensorineural hearing loss (Susac 1994) [1]. It occurs predominantly in young females and is believed to be an immune-mediated endotheliopathy of small vessels of the brain, retina and cochlea (Neumayer et al. 2009) [2]. Early, aggressive, and sustained immunosuppressive therapy has been recommended for Susac's syndrome and anecdotal evidence has suggested a therapeutic role for monoclonal antibodies (Rennebohm et al. 2008, Lee and Amezcua 2009) [3,4]. We report a case of Susac's syndrome in which the patient improved immediately after tumour necrosis factor (TNF) inhibition with the monoclonal antibody, infliximab.

© 2010 Elsevier B.V. All rights reserved.

1. Introduction

A 23 year-old female of Turkish descent presented with a seventeen-day history of retro-bulbar headache, photophobia, vomiting and lethargy. Ten days prior to presentation she underwent voluntary termination of pregnancy at seven weeks gestation. Her only past medical history was of asthma. There was no history of oro-genital ulceration and family history was non-contributory. Physical examination revealed that she was normotensive with a BP of 109/73 mm Hg and no fever or meningism. She was encephalopathic and unable to perform serial 7s or follow multi-step commands. Reflexes were brisk in the lower limbs but there were no localizing abnormalities.

Brain MRI showed multiple punctate foci of restricted diffusion and abnormal T2 signal in the deep white matter of both frontal lobes (Fig. 1C); and a larger lesion in the splenium of the right corpus callosum (Fig. 1D). CSF contained 8 lymphocytes and markedly elevated protein (1.83 g/L, normal <0.45). CSF polymerase chain reaction (PCR) for herpes simplex virus and varicella-zoster virus was negative. An ANA (titre 1:160, mitotic spindle apparatus pattern) was identified but

assays for dsDNA, ENA and ANCA were negative. Mycoplasma IgM was positive on two occasions eight weeks apart but other infective serology including HIV and quantiferon gold assay for tuberculosis was negative.

On day six of the admission, she deteriorated with worsening cognition, drowsiness, urinary incontinence and a generalized seizure. Repeat MRI showed progressive white matter disease and nodular areas of leptomeningeal enhancement, particularly over the cerebellum. Repeat CSF examination yielded a grossly elevated protein (2.9 g/L) and 8 lymphocytes. A pulse of intravenous methylprednisolone 1 g was given for presumed cerebral vasculitis. Four-vessel cerebral angiography was normal. The following day, her level of alertness had improved dramatically with resolution of headache and restoration of orientation. She received another two pulses of 1 g methylprednisolone on consecutive days and then on the following day was commenced on oral prednisolone 50 mg daily.

Formal neuropsychological testing in the ensuing days revealed severe global cognitive impairment with difficulties in working memory, learning, reading, writing and visuospatial abilities placing her below the 5th percentile for age on several measures e.g. Mini Mental State Examination score (MMSE) = 22/30; Addenbrooke's Cognitive Examination-R (ACE-R) score = 54/100. Brain PET showed marked hypermetabolism in the right lateral cerebellar hemisphere and in the left parahippocampal gyrus (Fig. 1E). Biopsy of the cerebellum and overlying meninges showed mild, non-specific perivascular inflammation.

She remained stable on prednisone 50 mg and was discharged on day twenty-six of her admission (having received 15 days of prednisone

* Corresponding author. Brain & Mind Research Institute, Level 4, 94 Mallett Street, Camperdown NSW 2050, Australia. Tel.: +61 2 93510730; fax: +61 2 93510653.

E-mail addresses: thardy@med.usyd.edu.au (T.A. Hardy), roger.garsia@email.cs.nsw.gov.au (R.J. Garsia), michael@icn.usyd.edu.au (G.M. Halmagyi), simonl@med.usyd.edu.au (S.J.G. Lewis), bharrisberg@bigpond.com (B. Harrisberg), mfulham@med.usyd.edu.au (M.J. Fulham), mbarnett@mail.usyd.edu.au (M.H. Barnett).

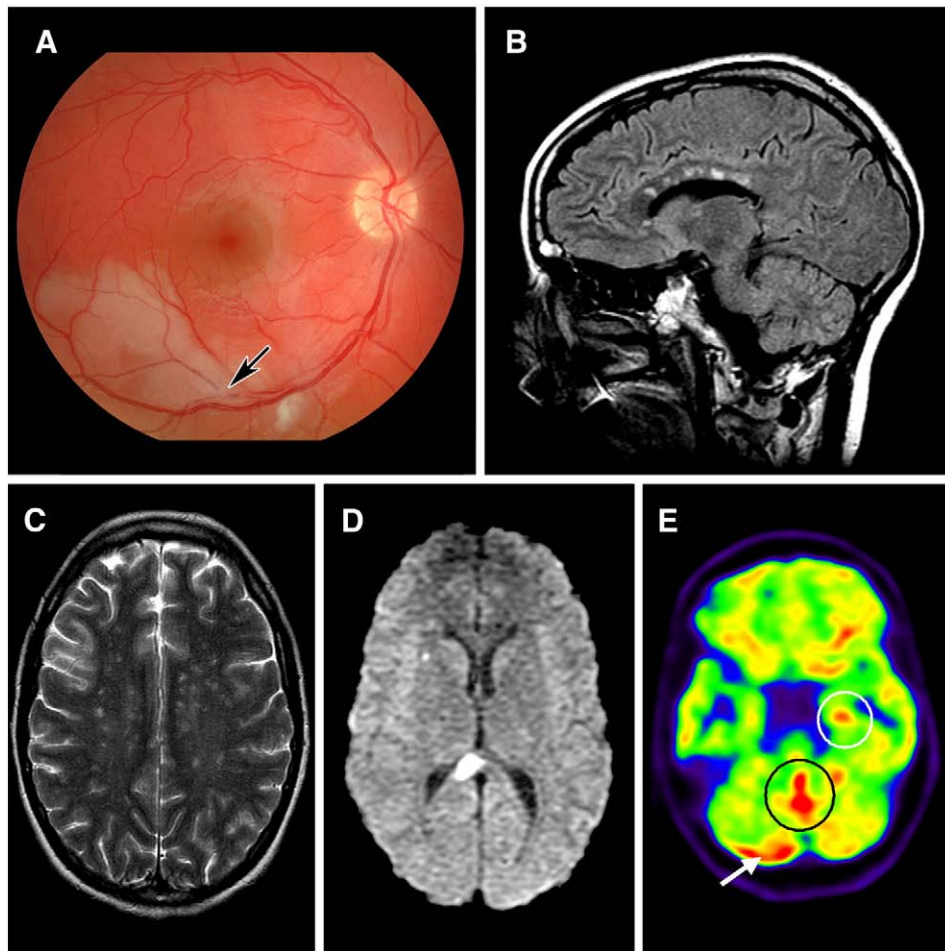


Fig. 1. Susac's syndrome. Right fundus photograph (A) shows branch retinal artery occlusion (arrow) and associated retinal infarction. Brain MRI sequences showing typical 'snowball' corpus callosal lesions (B), numerous foci of increased T2 increased signal in the deep white matter of both hemispheres (C) and a large right splenial lesion (D) exhibiting restricted diffusion in keeping with acute infarction. FDG-PET imaging (E) shows hypermetabolism in right lateral cerebellar hemisphere (white arrow), the cerebellar vermis (black circle) and the left parahippocampal gyrus (white circle).

50 mg daily prior to discharge). In total she received five weeks of prednisone 50 mg daily both in hospital and as an outpatient. She was on no other immunomodulatory therapy. She then re-presented on day fifty-two from the time of her initial presentation, on prednisone 45 mg which had been reduced from 50 mg daily one week previously. She was Cushingoid with headache, worsening cognition, ataxia and new upper motor neurone signs. Repeat MRI showed more extensive white matter disease and involvement of the left callosum. She subsequently complained of deafness and tinnitus. Audiometry demonstrated bilateral moderate low frequency hearing loss. Ophthalmic examination and fluorescein angiography revealed sporadic segmental retinal arterial occlusions in both eyes (Fig. 1A) confirming Susac's syndrome. Sagittal FLAIR MRI sequences showed typical 'snowball' lesions in the corpus callosum (Fig. 1B).

Therapy was escalated to include an additional agent to try to halt disease progression and minimize the adverse effects of ongoing corticosteroids. The patient received a single dose of infliximab 5 mg/kg and exhibited dramatic improvement within 24 h. Headache and ataxia resolved rapidly although her difficulty with calculation remained. She received no immunomodulatory therapy other than oral prednisone 45 mg prior to treatment with infliximab. Forty-eight hours after infliximab she was treated with intravenous immunoglobulin (IVIg) 0.4 g/kg/day for 5 days and, following the last dose of IVIg, a pulse of intravenous cyclophosphamide 1 g. Aspirin and the calcium channel blocker, nifedipine, were added. In total she received 5 cycles of intravenous cyclophosphamide at monthly intervals over the next five

months. The patient was then unhappy to continue with further cyclophosphamide due to concerns about potential infertility. Her prednisone was gradually tapered during this time. She did not receive further IVIg.

At six months a repeat MRI showed considerable improvement. The multiple periventricular and corpus callosal lesions had decreased in number, size and T2 signal intensity. Azathioprine 75 mg daily was added at eleven months from her initial presentation. At twelve months, her tinnitus and hearing loss persisted, but her cognition continued to improve with some ongoing deficits in spontaneous recall, working memory and verbal fluency (MMSE score 30/30; ACE-R 86/100). At fifteen months, she is taking prednisone 10 mg daily, azathioprine 100 mg daily, aspirin and nifedipine.

2. Discussion

Diagnosis of Susac's syndrome can be difficult, particularly in its earliest stages when the clinical triad is incomplete. In retrospect, the MRI in this case showed *pathognomonic* microinfarcts in the *central* fibers of the corpus callosum, a finding that may be overlooked unless T2-weighted sagittal sequences are obtained [5,6].

Our patient was in the first trimester of pregnancy when she developed the headache that marked the onset of Susac's syndrome. It is not clear whether the pregnancy itself was the trigger for the onset of the disease. Other authors have noted that Susac's syndrome appears to worsen in the post-partum period [7]. This phenomenon is

commonly observed in a number of autoimmune conditions including rheumatoid arthritis and thyroid disease [8,9]. Notably, our patient's symptoms flared in the week following termination of pregnancy when she became markedly encephalopathic and presented to hospital.

It is clear she abruptly deteriorated despite high dose corticosteroid, a well-described phenomenon [1]. Appropriate therapy in this setting is uncertain. Anti-TNF therapy has the advantage of disabling a final common pathway of inflammation, irrespective of the initiating process; and the potential for rapid onset of effect, thus providing a window for the action of definitive immunosuppression.

To our knowledge, this is the first report of anti-TNF alpha therapy in Susac's syndrome. Improvement after treatment with infliximab was immediate and striking, supporting a significant inflammatory, and potentially reversible, pathophysiology. Subsequent therapy with intravenous immunoglobulin and pulse cyclophosphamide likely effected a sustained benefit.

A single case report has suggested a potential role for another monoclonal antibody, rituximab, in Susac's syndrome [3,4]. This agent, which targets CD-20 expressing cells, is useful in dermatomyositis, a condition which appears to have a similar immunopathogenesis to Susac's syndrome [2,10]. Muscle disease may also be a subclinical feature of Susac's syndrome. In one series of five patients with Susac's syndrome who underwent muscle biopsy, three showed evidence of arteriolar microangiopathy [11]. Interestingly, infliximab also has efficacy in refractory juvenile dermatomyositis [12].

3. Conclusion

Early consideration of Susac's syndrome in patients with encephalopathy and corpus callosal lesions is paramount, as irreversible cerebral damage may accrue without prompt, aggressive, and sustained immu-

nosuppressive therapy. Infliximab may be a useful adjunct in patients with rapid deterioration in whom the effects of definitive immunosuppression are likely to be delayed. If the infusion of infliximab, which blocks the pro-inflammatory cytokine TNF alpha, was responsible for this patient's immediate and dramatic improvement, this might shed important light on the immunopathogenesis of this rare disease.

References

- [1] Susac J. Susac's syndrome: the triad of microangiopathy of the brain and retina with hearing loss in young women. *Neurology* 1994;44:591–3.
- [2] Jarius S, Neumayer B, Wandinger K, Hartmann M, Wildemann B. Anti-endothelial serum antibodies in a patient with Susac's syndrome. *J Neurol Sci* 2009;285:259–61.
- [3] Rennebohm R, Egan R, Susac J. Treatment of Susac's syndrome. *Curr Treat Options Neurol* 2008;10:67–74.
- [4] Lee M, Amezcua L. Treatment of Susac's syndrome with rituximab: a case report. *Neurology* 2009;72:A203.
- [5] Susac J, Murtagh F, Egan R, Berger J, Bakshi R, Lincoff N, Gean A, Galetta S, Fox R, Costello F, Lee A, Clark J, Layzer R, Daroff R. MRI findings in Susac's syndrome. *Neurology* 2003;61:1783–7.
- [6] Susac J, Egan R, Rennebohm R, Lubow M. Susac's syndrome: 1975–2005 microangiopathy/autoimmune endotheliopathy. *J Neurol Sci* 2007;15(257):270–2.
- [7] Aubart-Cohen F, Klein I, Alexandra J, Bodaghi B, Doan S, Fardeau C, Lavallée P, Piette J, Hoang P, Papo T. Long-term outcome in Susac syndrome. *Medicine* 2007;86:93–102.
- [8] de Man Y, Dolhain R, van de Geijn F, Willemsen S, Hazes J. Disease activity of rheumatoid arthritis during pregnancy: results from a nationwide prospective study. *Arthritis Rheum* 2008;59:1241–8.
- [9] Weetman A. Immunity, thyroid function and pregnancy: molecular mechanisms. *Nat Rev Endocrinol* 2010;6:311–8.
- [10] De Bleeker J, De Paepe B, Vanwallegghem I, Schröder J. Differential expression of chemokines in inflammatory myopathies. *Neurology* 2002;58:1779–85.
- [11] Petty G, Engel A, Younge B, Duffy J, Yanagihara T, Lucchinetti C, Bartleson J, Parisi J, Kasperbauer J, Rodriguez M. Retinocochleocerebral vasculopathy. *Medicine (Baltimore)* 1998;77:12–40.
- [12] Riley P, McCann L, Maillard S, Woo P, Murray K, Pilkington C. Effectiveness of infliximab in the treatment of refractory juvenile dermatomyositis with calcinosis. *Rheumatology (Oxford)* 2008;47:877–80.