

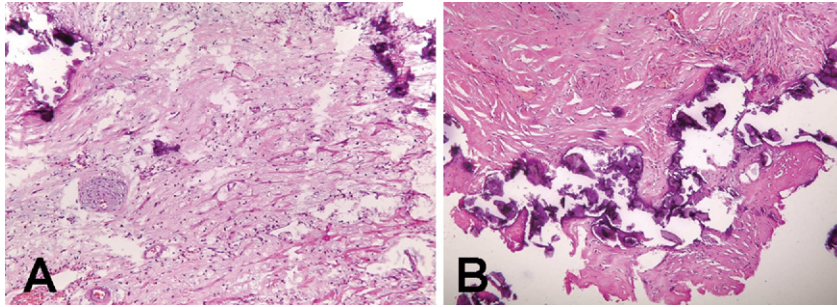Fig 3. (A) Pericardium layer and dystrophic calcifications within the hyalinized fibrous tissue. (Hematoxylin and eosin stain; $\times 100$.) (B) Calcified fibrous tissue involving the myocardium. (Hematoxylin and eosin stain; $\times 100$.)

All the materials were composed of dystrophic calcified pericardium and hyalinized fibrous tissue without any relevant tumor cells. Histopathologic diagnosis was consistent with calcifying fibrous pseudotumor.

Transthoracic echocardiographies were performed at 1, 3, and 6 months after the operation. Residual periapical and inferoposterior calcifications of the pericardium caused a mild restrictive type of left ventricle filling. Three years after the operation, transthoracic echocardiography showed fused pericardium with the posterior wall of the left ventricle and atrium without hemodynamic repercussion. The patient's heart function, cavities dimensions, and valvular apparatus were normal. Three years after the operation patient had no cardiac symptoms. She is fully capable of performing her everyday activities without any signs of fatigue. At the end of the year in 2009, she naturally conceived.

Comment

Calcifying fibrous pseudotumor is rare, but it is a distinctive lesion of soft tissue. Because its original description by Rosenthal and Abdul-Karim in 1988 [4], tumor occurrence has been reported in various parts of the body [5-8]. There are several cases of CFPT involving mediastinum and pleura [5, 6], and two cases of CFPT arising from the heart [7, 8]. In both cases young women were affected, and in one case complete resection was definitive treatment [7]. In the other case complete resection was not possible due to encasement of the anterior descending coronary artery [8]. There was no correlation between the clomiphene and oral contraceptives use or polycystic ovary syndrome and CFPT described in the literature. Our case shows that CFPT can infiltrate myocardium and prevent total resection. Because of incipient signs of constrictive effect to the heart and unpredictable biologic and clinical behavior of CFPT, regular follow-up is obligatory in this case.

References

1. Van Dorpe J, Ectors N, Geboes K, D'Hoore A, Sciot R. Is calcifying fibrous pseudotumor a late sclerosing stage of inflammatory myofibroblastic tumor? *Am J Surg Pathol* 1999; 23:329-35.
2. Fetsch JF, Montgomery EA, Meis JM. Calcifying fibrous pseudotumor. *Am J Surg Pathol* 1993;17:502-8.

3. Maeda A, Kawabata K, Kusuzaki K. Rapid recurrence of calcifying fibrous pseudotumor. *Anticancer Res* 2002;22: 1795-7.
4. Rosenthal NS, Abdul-Karim FW. Childhood fibrous tumor with psammoma bodies. Clinicopathologic feature in two cases. *Arch Pathol Lab Med* 1988;112:798-800.
5. Dumont P, de Muret A, Skrobala D, Robin P, Toumieux B. Calcifying fibrous pseudotumor of the mediastinum. *Ann Thorac Surg* 1997;63:543-4.
6. Pinkard NB, Wilson RW, Lawless N, et al. Calcifying fibrous pseudotumor of pleura. A report of three cases of a newly described entity involving the pleura. *Am J Clin Pathol* 1996;105:189-94.
7. Hisayuki Shigematsu, Yoshifumi Sano, Shingo Kasahara, Hiroyuki Yanai, Hiroshi Date. Calcifying fibrous tumor arising from the heart. *J Thorac Cardiovasc Surg* 2006;132:e21-2.
8. Kirby PA, Sato Y, Tannous R, Dehner LP. Calcifying fibrous pseudotumor of the myocardium. *Pediatr Dev Pathol* 2006;9: 384-7.

Cerebral Air Embolism as a Result of Inducing Pneumoperitoneum After Bilobectomy

Hak Young Rhee, MD, Dae Hyun Kim, MD, Young Tae Kwak, MD, Jae Woo Lee, MD, and Sung Hun Kim, MD

Departments of Neurology, Thoracic and Cardiovascular Surgery, and Anesthesiology, Kyung Hee University East-West Neo Medical Center, Seoul; and Department of Neurology, College of Medicine, Kangwon National University, Chuncheon, Republic of Korea

A 62-year-old man with lung cancer underwent a right lower bilobectomy of the lung. After resection, we insufflated air through the diaphragm into the peritoneal cavity, and sudden cardiac arrest developed in the patient. A large number of air bubbles were aspirated from the heart and great vessels, and the patient recovered after resuscitation. However, he remained with a left sensory deficit, a left homonymous hemianopia, and left hemiparesis. A brain computed tomographic scan revealed an acute ischemic lesion in the right parieto-

Accepted for publication June 16, 2010.

Address correspondence to Dr Kim, Department of Thoracic and Cardiovascular Surgery, Kyung Hee University East-West Neo Medical Center, Kyunghee Univ #149, Sangil-dong, Gangdong-gu, Seoul, 134-727, Republic of Korea; e-mail: kmctskdh@hanmail.net.

occipital area. Our case shows that an air embolism is a possible complication of artificial intraoperative pneumoperitoneum after pulmonary resection.

(Ann Thorac Surg 2011;91:293-5)

© 2011 by The Society of Thoracic Surgeons

Removal of the right middle and lower lobes often results in a large residual space that may contribute to persistence of any air leak or empyema, because the space is not obliterated by adherence of the visceral and the diaphragmatic pleura [1]. Artificial pneumoperitoneum is a popular procedure, known to be simple and safe to perform, to treat prolonged air leaks or residual pleural space after pulmonary resection [1-3]. Herein, we report a case of cerebral air embolism as a complication of artificial intraoperative pneumoperitoneum after resection of the right middle and lower lobes.

A 62-year-old man was admitted for fever, cough, and productive sputum. An initial chest roentgenogram showed pneumonic infiltration in the right lower lobe (RLL), and a bronchoscopic biopsy demonstrated squamous cell carcinoma in the RLL. Whole-body fusion positron emission tomography demonstrated hypermetabolic areas in the RLL bronchus and the right hilar lymph nodal station. The clinical stage of his lung cancer was IIb, and a bilobectomy of the right middle lobe and RLL was performed.

Bilobectomy of the right middle lobe and RLL with systemic dissection of the mediastinal lymph nodes was performed by a thoracotomy in the left lateral decubitus position. Because the residual pleural dead space was large, we intended to make an artificial pneumoperitoneum to reduce the size of the pleural cavity by elevating the diaphragm. We inserted a 20-gauge needle into the dome of the right diaphragm. After confirming that the needle was introduced properly, the operator injected 700 cc of atmospheric air into the peritoneal cavity through the needle, thereby elevating the right diaphragm. Five minutes after creation of the artificial pneumoperitoneum, his vital signs abruptly deteriorated to a blood pressure of 40/30 mm Hg

and a pulse of 40 bpm. Cardiac contractility decreased severely, and the right heart was distended extensively. An ST wave depression also appeared. Oxygen saturation was 70%, and end-tidal carbon dioxide tension was 8 mm Hg. His position was changed to head-down, and ice was applied around his head. Inotropic drugs were injected, and the pericardium was incised. We provided cardiac massage to support contractility, with simultaneous removal of air from the right atrium, right inferior pulmonary vein stump, left atrium, and ascending aorta by multiple injections of angio-needles. After 1 hour of resuscitation, his vital signs slowly recovered.

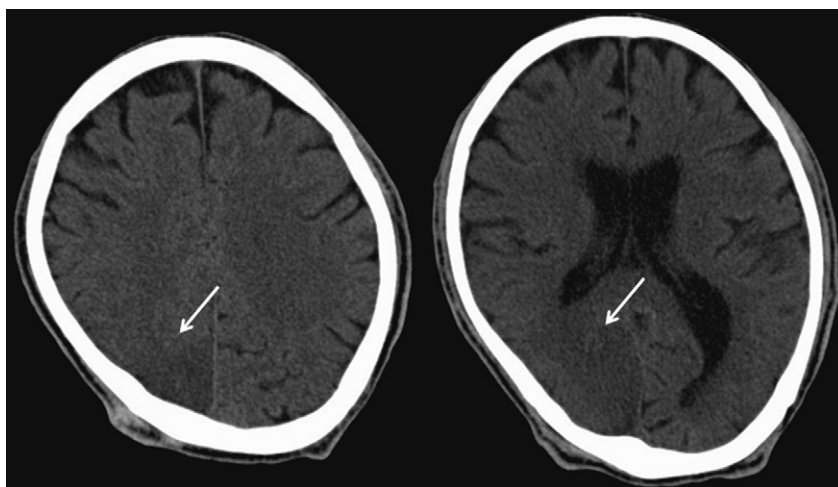
Immediately after the operation, the patient's consciousness did not improve, and an asymmetric motor response to pain was observed. Although the patient became alert and fully cooperative 1 day after the operation, a neurological examination showed a left sensory deficit, a left homonymous hemianopia, and left hemiparesis. Brain computed tomography on postoperative day 4 revealed a hypodense area in the right parieto-occipital lobe corresponding to the posterior cerebral arterial territory (Fig 1). There was no evidence of an intracardiac shunt on trans-thoracic echocardiography. Two months after the operation, the motor power of the left extremities improved remarkably, but the sensory deficit and homonymous hemianopia remained.

Comment

Artificial pneumoperitoneum is known to be a safe and effective procedure for managing a space problem associated with prolonged air leaks after pulmonary resection [3]. By elevating the diaphragm temporarily, it can help the visceral pleura of the lung to adhere to the parietal pleura of the diaphragm. This procedure can be performed even at the time of thoracotomy during pulmonary resection [1-3].

Cerebral air embolisms, one of the causes of perioperative stroke, have been reported in cardiac surgeries with

Fig 1. Brain computed tomographic scan shows a hypodensity in the right parieto-occipital area, suggesting cerebral infarction of the right posterior cerebral arterial territory (arrows).



cardiopulmonary bypass, hip replacement surgeries, craniotomies performed with the patient in a sitting position, and Caesarean sections [4]. All of these procedures have an incised vascular bed and a hydrostatic gradient favoring the intravascular entry of air. In addition, laparoscopic procedures are well known to be related to venous embolisms from carbon dioxide gas used for pneumoperitoneum. The major cause leading to emboli is the misplacement of the Veress needle directly into a vessel or parenchymal organ [5]. During a venous embolism, cerebral embolism can occur when the gas enters the systemic arterial circulation and causes symptoms of end-artery obstruction [6].

In this case, a large amount of air had been aspirated from the heart and great vessels, including the arterial system. Thus, it is reasonable to assume that the air embolism occurred because of the pneumoperitoneum, which increased the intra-abdominal pressure and allowed the air to enter the venous system through unexpected intravascular injection of the needle used for inducing pneumoperitoneum. It is possible that the needle moved as the syringe was moved back and forth while the operator injected air. Although the exact location where air entered the venous system was not identified, direct injection within the liver or a branch of the right phrenic vein is a possible route. After entering venous circulation, air could shunt from venous to arterial circulation and obstruct cerebral blood flow. Usually the passage of air into systemic circulation can occur through the existence of an intra-cardiac shunt, which was not found in this case. Nevertheless, animal studies have shown that when the lung filter is overloaded, air bypasses this filter, and a paradoxical embolism through the pulmonary capillary bed can occur [7, 8]. The location of the arterial occlusion may have been related to the patient's position during the operation. The patient was in a left lateral decubitus position, with the right side upward, and gravitation may have affected the right hemispheric involvement.

The decision to induce a pneumoperitoneum can be made in the postoperative period only after a persistent air leak is documented [3]. If this procedure needs to be performed intraoperatively, an open technique is an alternative way, using a soft red rubber, rather than a Veress needle. In inducing pneumoperitoneum, Cerfolio and colleagues [1] made a small transdiaphragmatic opening in the right hemi-diaphragm at the time of bilobectomy of the right lung and injected air using an 18-French red rubber catheter, although the opening to prevent the needle from moving into the vein, which was proven to be safe and easy to do. Another alternative is transient phrenic nerve paralysis with continuous paraventricular infusion of bupivacaine, which is a safe, low-cost, and easy to perform technique [9]. Another important issue to consider is how to handle the embolism after it occurs. After the development of an air embolism, aggressive cardiopulmonary resuscitations and adequate oxygenation with an increase in the oxygen concentration of the inspired gas for reducing the size of air embolus is required. Rapid resuscitation with volume expansion

elevates venous pressure, thus preventing the subsequent entry of air into circulation [6]. The patient should be placed in the left lateral decubitus position with the head down, which allows the air to rise into the apex of the right ventricle and prevents its entry into the pulmonary artery. Air should be evacuated from all suspected sites, which may include all cardiac chambers and the ascending aorta.

Although they are rare, air embolisms deserve special attention as possible complications of an artificial intraoperative pneumoperitoneum after pulmonary resection. Systemic embolization may also occur through transpulmonary passage.

References

1. Cerfolio RJ, Holman WL, Katholi CR. Pneumoperitoneum after concomitant resection of the right middle and lower lobes (bilobectomy). *Ann Thorac Surg* 2000;70:942–6.
2. Okur E, Arisoy Y, Baysungur V, et al. Prophylactic intraoperative pneumoperitoneum decreases pleural space problems after lower lobectomy or bilobectomy of the lung. *Thorac Cardiovasc Surg* 2009;57:160–4.
3. De Giacomo T, Rendina EA, Venuta F, et al. Pneumoperitoneum for the management of pleural air space problems associated with major pulmonary resections. *Ann Thorac Surg* 2001;72:1716–9.
4. Selim M. Perioperative stroke. *N Engl J Med* 2007;356:706–13.
5. Azevedo JL, Azevedo OC, Miyahira SA, et al. Injuries caused by Veress needle insertion for creation of pneumoperitoneum: a systematic literature review. *Surg Endosc* 2009;23:1428–32.
6. Muth CM, Shank ES. Gas embolism. *N Engl J Med* 2000;342:476–82.
7. Butler BD, Hills BA. Transpulmonary passage of venous air emboli. *J Appl Physiol* 1985;59:543–7.
8. Tommasino C, Rizzardi R, Beretta L, Venturino M, Piccoli S. Cerebral ischemia after venous air embolism in the absence of intracardiac defects. *J Neurosurg Anesthesiol* 1996;8:30–4.
9. Clavero JM, Cheyre JE, Solovera ME, Aparicio RP. Transient diaphragmatic paralysis by continuous para-phrenic infusion of bupivacaine: a novel technique for the management of residual spaces. *Ann Thorac Surg* 2007;83:1216–8.

En Bloc Resection of 3 Vertebra in a Pancoast Patient: Long-Term Stability Using a Free Vascularized Fibular Graft

Cornelis G. Vos, MD, Koen J. Hartemink, MD, J. W. A. (Wolter) Oosterhuis, MD, PhD, Hay A. Winters, MD, PhD, and Marinus A. Paul, MD, PhD

Departments of Surgery and Plastic Surgery, VU University Medical Center, Amsterdam, the Netherlands

Vertebral involvement is no longer a contraindication for resection in superior sulcus tumors. We describe the reconstruction of thoracic vertebrae 2 to 4 using a free

Accepted for publication July 29, 2010.

Address correspondence to Dr C.G. Vos, VU University Medical Center, Department of Surgery, De Boelelaan 1117, Amsterdam, 1081 HV, the Netherlands; e-mail: c.vos@vumc.nl.