

Case Report

Recurrent Stroke Due to a Novel Voltage Sensor Mutation in Ca_v2.1 Responds to Verapamil

Ellen Knierim, MD; Lilia Leisle; Christiane Wagner, MD; Bernhard Weschke, MD; Barbara Lucke; Georg Bohner, MD; Jens P. Dreier, MD; Markus Schuelke, MD

Background and Purpose—Familial hemiplegic migraine is characterized by recurrent migraine, hemiparesis, and ataxia. Causes may be mutations in calcium and sodium channels or in a subunit of the Na/K-ATPase. Migraine treatment with calcium channel blockers was only successful in some patients.

Summary of Case—We describe a 6-year-old girl with recurrent ischemic strokes after minor head trauma associated with seizures, hemiparesis, fever, and altered consciousness. Genetic analysis revealed a spontaneous, novel dominant *CACNA1A* mutation (c.4046G→A, p.R1349Q) that removed a highly conserved arginine of the voltage sensing region of the P/Q-type Ca_v2.1 channel. Because a homologous mutation in the *tottering-5J* mouse increased open probability of the channel as well as calcium influx, we treated the patient with the calcium channel blocker verapamil during characteristic prodromi after head trauma. Treatment was instantly effective and prevented a new stroke.

Conclusion—*CACNA1A* mutations should be considered in the diagnostic workup of childhood stroke, especially if associated with ataxia and migraine. (*Stroke*. 2011;42:e14-e17.)

Key Words: calcium channels ■ genetics ■ pediatric neurology ■ pediatric stroke ■ stroke in children

Familial hemiplegic migraine (FHM) is a rare, childhood-onset, autosomal-dominant subtype of migraine with aura. It is characterized by hemiparesis during the aura phase and may also be associated with cerebellar ataxia, delay of motor development, and other neurological symptoms such as cerebral seizures, mental retardation, brain edema, fever, and coma.^{1,2} Attacks may be provoked by typical migraine triggers such as stress, exertion, and minor head trauma. Some small open pharmacological studies tested the efficiency of acetazolamide and verapamil to suppress aura symptoms, but not all patients improved and the relation between therapeutic effect and molecular defect had remained unexplored.³ Gene mutations leading to FHM comprise defects in *CACNA1A* (FHM1, MIM #141500), *ATP1A2* (FHM2, MIM #602481), and *SCN1A* (FHM3, MIM #609634). On the reverse, mutations in *CACNA1A* may cause various clinical phenotypes, which include FMH1, episodic ataxia Type 2 (MIM #108500), and spinocerebellar ataxia Type 6 (MIM #183086). There exists a certain, albeit restricted, genotype–phenotype relation: gain-of-function mutations cause FHM1, truncating mutations or mutations affecting folding of the channel cause episodic ataxia Type 2, and triplet extension mutations around Q84 lead to spinocerebellar ataxia Type 6.⁴ We report the case of a young girl in whom FHM Type 1 manifested itself with repeated cerebral

infarctions due to a novel human gain-of-function mutation in the voltage-gated calcium channel Ca_v2.1. The child responded promptly to therapy with the calcium channel blocker verapamil, thus linking a defined molecular defect in FHM1 with a potential pathogenesis-based therapy for the first time.

Case History

The 6-year-old girl is a single child of healthy nonconsanguineous parents. At 3 months, she presented with a severe convergent squint. Motor development was retarded (head control 3 months, turns from supine to prone 12 months, sitting freely 14 months, pulls to standing from supine 18 months). At the age of 2 years, she had 2 episodes of cerebral seizures and coma for 2 weeks after a fall from a height of 1 m from a bed. An MRI excluded intracranial hemorrhage and detected mild cerebellar atrophy and delay in myelination. From this time, her motor development was stagnant and until now she is unable to walk freely. At 3.5 years of age, she was admitted again with encephalopathy and left-sided weakness, this time a few hours after a backward fall from a bobby-car. MRI revealed a massive ischemic lesion with prominent perifocal edema in the right parietal and occipital lobe (Figure 1A–B). Despite an extensive search for emboli, including transesophageal cardiac ultrasound and coagulation

Received August 16, 2010; final revision received October 1, 2010; accepted October 4, 2010.

From the Department of Neuropediatrics (E.K., C.W., B.W., B.L., M.S.), the NeuroCure Clinical Research Center (E.K., B.L., M.S.), the Department of Neuroradiology (G.B.), and the Center for Stroke Research (J.P.D.), Charité Universitätsmedizin Berlin, Berlin, Germany; and the Leibniz-Institute for Molecular Pharmacology and Max-Delbrueck-Center for Molecular Medicine (L.L.), Berlin, Germany.

Correspondence to Markus Schuelke, MD, Department of Neuropediatrics, Charité Universitätsmedizin Berlin, Campus Virchow Klinikum, Augustenburger Platz 1, D-13353 Berlin, Germany. E-mail markus.schuelke@charite.de

© 2011 American Heart Association, Inc.

Stroke is available at <http://stroke.ahajournals.org>

DOI: 10.1161/STROKEAHA.110.600023

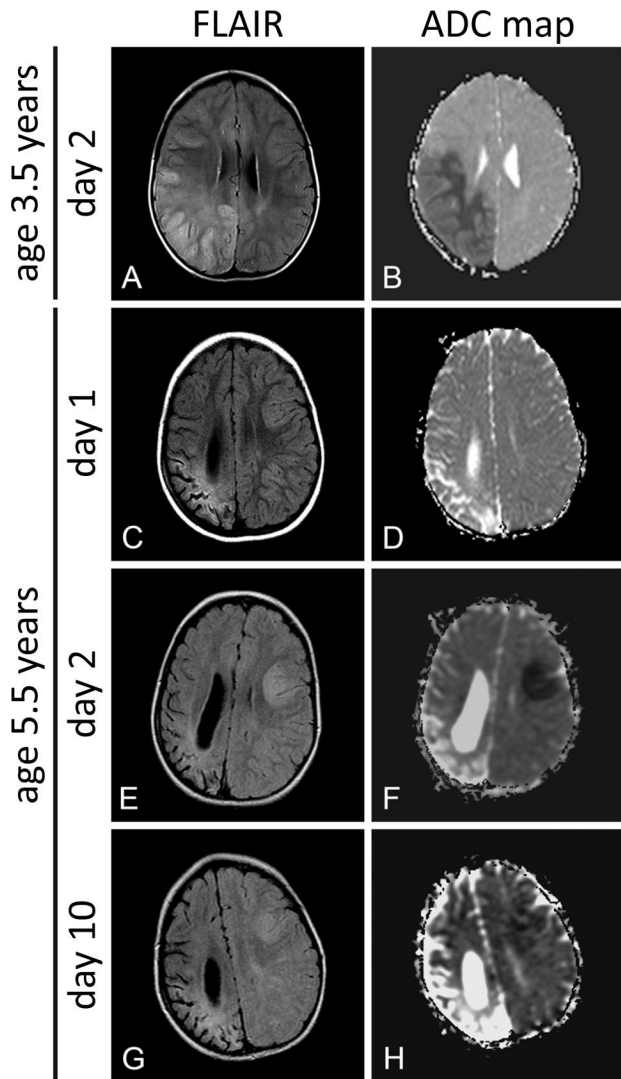


Figure 1. A, Cerebral MRI at the age of 3.5 years. Axial fluid-attenuated inversion recovery (FLAIR) image demonstrates edema in the right parietal and occipital lobe, which is not restricted to vascular territories. Corresponding hypointense signal changes on the apparent diffusion coefficient (ADC) map confirm an ischemic lesion. B–D, Serial cerebral MRI at the age of 5.5 years. B, At the day of symptom onset, the axial FLAIR image shows mild cortical edema in the left frontal and parietal lobe, whereas the ADC map is still unremarkable at this time, suggesting vasogenic rather than cytotoxic edema. At the right parietal and occipital lobe, the cortex is atrophied in the area of the old infarction. C, At the second day, cytotoxic edema with increasing hyperintense signal changes on FLAIR images and signal reduction on the ADC map corresponding to an ischemic lesion can be seen in the left frontal lobe. A vascular occlusion of the left posterior cerebral artery was ruled out by conventional angiography (data not shown). D, Ten days after symptom onset, cerebral MRI depicts progressive subcortical edema in the left parietal lobe on FLAIR images without signs of new ischemic tissue damage on the ADC map.

studies, no obvious cause was found. Sequence analysis of all mitochondrial tRNAs ruled out mitochondrial encephalomyopathy, lactic acidosis, and strokelike episodes (MELAS) syndrome and related disorders. The girl recovered slowly, needed long-term rehabilitation, and a left-sided hemiplegia remained. Absence-like seizures were treated with levetiracetam. At 5 years of age, after falling from the lap of a

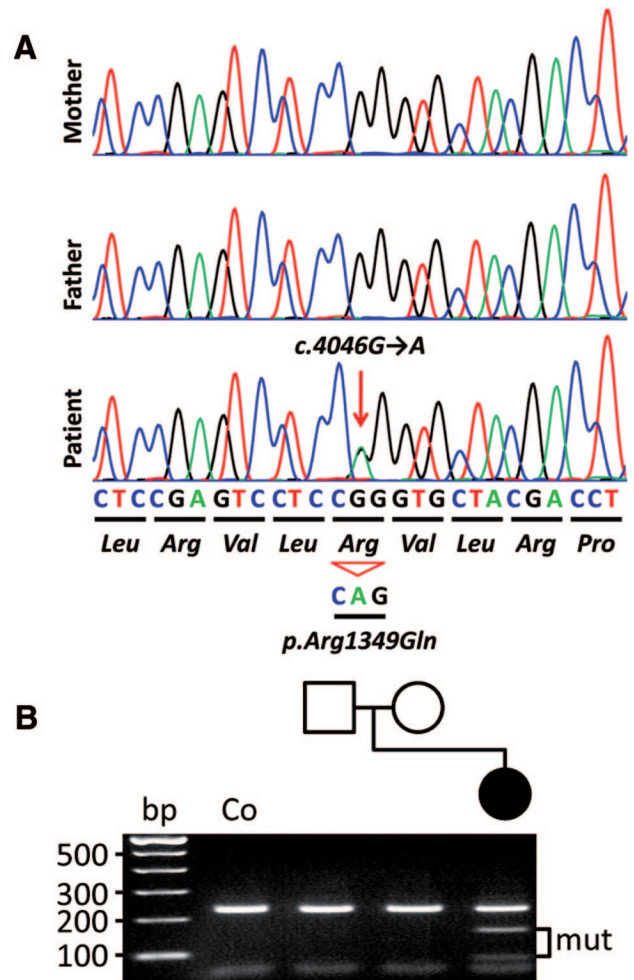


Figure 2. Molecular genetic findings in the patient's family. A, The heterozygous c.4046G→A transition leads to the exchange of arginine for glutamine and was absent in both parents. B, Segregation analysis of the mutation. The c.4046G→A mutation generates a novel *BstNI* restriction site, thus cleaving the 241-bp wild-type fragment into 171+70 bp (mut).

grandparent, she was again admitted to the hospital with loss of consciousness, now with fever, right-sided focal seizures, and weakness. Serial MRI scans revealed increased signal intensity on T₂ and fluid-attenuated inversion recovery images and hypointensity in apparent diffusion coefficient maps of the left hemisphere that were not restricted to vascular territories and showed variance in the temporal progression of the lesions (Figure 1C–H). Digital subtraction angiography excluded an arterial or venous occlusion. Over the next 3 months, vigilance and motor capabilities of the child improved slowly.

Genetics

The clinical symptoms and the MRI diagnostic findings led us to suspect a severe form of FHM and prompted sequence analysis of *CACNA1A*. Genomic DNA was isolated from peripheral blood cells by salt extraction and all 47 exons of *CACNA1A* (GenBank NM_001127222), including flanking intronic regions, were polymerase chain reaction-amplified and analyzed by automatic sequencing. We identified a heterozygous c.4046G→A transition in *CACNA1A* (Figure

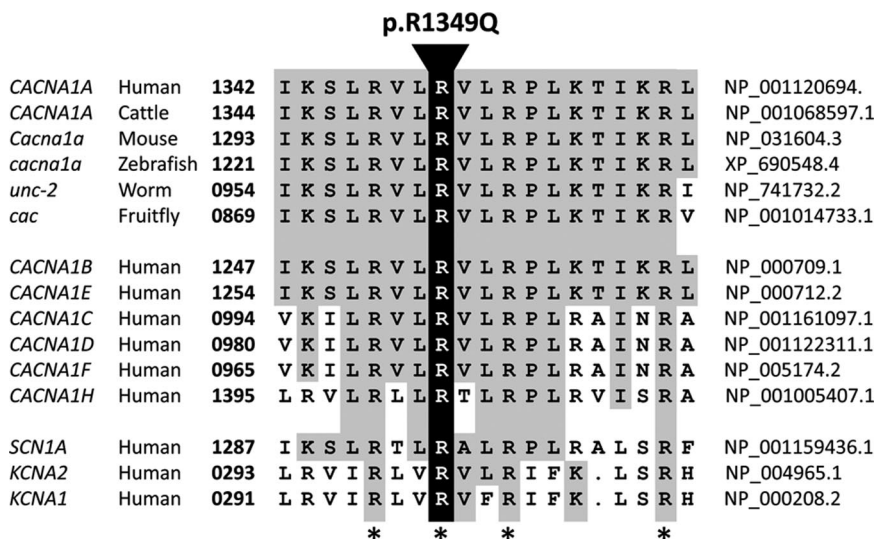


Figure 3. Multiple sequence alignment of a critical sequence motif from the highly evolutionary conserved voltage sensing domain of CACNA1A orthologs from various species (i), of several voltage-gated fast and slow calcium channels (ii) as well as sodium and potassium channels (iii). Note the complete conservation of the quadruple-arginine motif (*). The mutated amino acid is highlighted.

2). To confirm the c.4046G→A mutation and to screen normal controls, we polymerase chain reaction-amplified the DNA sequence of exon 25 using the oligonucleotides (forward) 5'-GGACCACTCTTCACCAGGAA-3' and (reverse) 5'-CCACCATCTCCCAATCTCAC-3'. The resulting 241-bp band was cut into 171+70 bp by *Bst*NI only in the presence of the mutation (Figure 2B). On the protein level, the mutation causes the substitution of arginine to glutamine at codon 1349. The de novo mutation was absent in her parents (Figure 2) and in 200 alleles of normal control subjects (data not shown). To exclude uniparental disomy or a complex rearrangement and to confirm paternity, we investigated 20 microsatellite markers flanking the *CACNA1A* locus on chromosome 19 (D19S424, D19S1034, D19S586, D19S906, D19S221, D19S558, D19S226, D19S923, D19S885, D19S429, D19S925, D19S931, D19S255, D19S875, D19S433, D19S882, D19S414, D19S871, D19S223, D19S178) by polymerase chain reaction amplification with fluorescent primers. These polymerase chain reaction products were then mixed with a ROX500 standard and analyzed for their lengths on an ABI3730 sequencer and subsequently with the GenMapper Version 3.7 software (data not shown).

Clinical Course and Verapamil Treatment

Shortly after we had found the *CACNA1A* mutation, at the age of 5.5 years, the girl was again admitted to the emergency department after another backward fall from a chair and hitting her head on the floor. She showed the characteristic prodromi that had anticipated her last ischemic strokes (all secondary to a minor head trauma), which comprised severe headaches, yawning, truncal unsteadiness, and progressive loss of consciousness. Based on the molecular genetic results, we decided to initiate immediately an intravenous therapy with the calcium channel blocker verapamil at a single dose of 0.1 mg/kg body weight over 20 minutes. Already during infusion the girl regained consciousness and started to talk to her mother. The dramatic clinical improvement was sustained even after the infusion had finished. As a long-term prophylactic treatment, we prescribed oral verapamil at a daily dosage of 3 mg/kg body weight under which the child did not develop any signs of stroke for 1 year despite 2 episodes of

head trauma of the same order of magnitude as the ones causing stroke before.

Discussion

We report on a young girl who had several ischemic strokes due to a spontaneous dominant mutation in her *CACNA1A* gene (c.4046G→A, p.R1349Q). Ischemic stroke has not been reported in FHM1 before. These findings expand the clinical spectrum of *CACNA1A* mutations and place our patient at one extreme of a clinical continuum between simple migraine aura and the most severe vascular complications with manifest stroke.

The *CACNA1A* gene encodes the α_1 -subunit of the highly conserved P/Q-type voltage-gated calcium channel $\text{Ca}_v2.1$. Analysis of the c.4046G→A sequence variant with Mutation Taster, an evaluation tool of the pathogenic potential of sequence variants,⁵ predicted pathogenicity with a high probability ($R=0.988$). Moreover, the absence of this variant in 200 normal alleles excluded a common polymorphism. The mutation replaces an evolutionary highly conserved alkaline arginine by a neutral glutamine. R1349 contributes to a motif of 4 arginines that form the voltage sensor of various calcium as well as of sodium and potassium channels (Figure 3).⁶

Missense mutations removing such arginine residues have been shown to alter $\text{Ca}_v2.1$ channel function in a gain-of-function manner. This was confirmed by in vitro and ex vivo studies on human *CACNA1A* FHM1 mutations (p.R192Q and p.R583Q) and for the p.R1252Q mutation of the *tottering-5j* (*Tg-5j*) mouse (this mutation corresponds to p.R1300Q on NP_031604.3; Figure 3) that led to a shift to more negative potentials for both $\text{Ca}_v2.1$ channel activation and inactivation.^{7–9} Interestingly, the p.R1300Q mutation of the *Tg-5j* mouse is exactly homologous to the human p.R1349Q mutation (Figure 3). The functional consequences of this mutation were grave, because homozygous mice died soon after birth.⁹ We thus have reason to assume that in humans, the p.R1349Q mutation may also lead to a gain-of-function with enhanced $\text{Ca}_v2.1$ channel activity and subsequent increased intracellular calcium concentrations leading to cortical spreading depression.

Spreading depression of cortical electric activity is thought to be the pathophysiological correlate of migraine aura and the result of near-complete and sustained depolarization of neurons above the inactivation threshold for their action-potential generating ion channels. Spreading depolarization can be observed as a large change of the slow potential, whereas spreading depression is characterized by electric silence in the higher frequency band of the electrocorticogram in humans and animals.¹⁰ Resistance vessels change their vascular tone in response to spreading depolarization, causing either (1) transient hyperperfusion (physiological hemodynamic response) in healthy tissue; or (2) severe hypoperfusion (inverse hemodynamic response) under pathological conditions leading to spreading ischemia, which in itself may cause widespread cerebral infarctions in animals¹¹ and which contributes to lesion progression in humans.¹⁰ Mild head trauma is a well-known trigger for such spreading depolarizations,¹² and missense mutations in *CACNA1A* may decrease their threshold,¹³ an effect presumably due to increased glutamatergic neurotransmission.^{14,15} The findings in our patient suggest that the inverse hemodynamic response to spreading depolarization might be promoted or mediated by Ca_v2.1 channels. Because Ca_v2.1 channels also seem to be present on the smooth muscle layer of resistance vessels,¹⁶ they may mediate vasoconstriction secondary to calcium influx. Interestingly, another L-type calcium channel blocker, nimodipine, was able to almost completely reverse spreading ischemia in a rat model.¹⁷

We therefore hypothesize that the mild head trauma in our patient was sufficient to induce spreading depolarization, which, on top of an inverse hemodynamic response, led to widespread brain infarctions in a superadditive manner. This hypothesis deserves further study in animals, for example, in the *tottering-5j* (*Tg-5J*) mouse with the homologous mutation.

We are aware that analysis of a single case cannot prove the therapeutic efficacy of verapamil in this condition. Further controlled clinical studies in combination with molecular genetic analyses are thus necessary to substantiate such an effect. Beyond that, our findings suggest that sequence analysis of *CACNA1A* should be considered during diagnostic workup of childhood stroke associated with migraine and ataxia; all the more, it seems to be a treatable condition.

Acknowledgments

We express gratitude to the patient and her family and to Dr Christine Gerstenfeld for proofreading the manuscript.

Sources of Funding

This project was supported by the Deutsche Forschungsgemeinschaft through the NeuroCure Cluster of Excellence, Exc 257 and the SFB 665 TP C4 to M.S. and the SFB TR3 D10 as well as by the BMBF through the Center for Stroke Research Berlin, 01 EO 0801 to J.P.D.

Disclosures

None.

References

- Vahedi K, Denier C, Ducros A, Bousson V, Levy C, Chabriat H, Haguenau M, Tournier-Lasserre E, Bousser MG. *CACNA1A* gene de novo mutation causing hemiplegic migraine, coma, and cerebellar atrophy. *Neurology*. 2000;55:1040–1042.
- Stam AH, Luijckx GJ, Poll-The BT, Ginjaar IB, Frants RR, Haan J, Ferrari MD, Terwindt GM, van den Maagdenberg AM. Early seizures and cerebral oedema after trivial head trauma associated with the *CACNA1A* S218L mutation. *J Neurol Neurosurg Psychiatry*. 2009;80:1125–1129.
- Russell MB. Management of sporadic and familial hemiplegic migraine. *Expert Rev Neurother*. 2010;10:381–387.
- Pietrobon D. Ca(v)2.1 channelopathies. *Pflugers Arch*. 2010;460:375–393.
- Schwarz JM, Rödelsperger C, Schuelke M, Seelow D. MutationTaster evaluates disease-causing potential of sequence alterations. *Nat Methods*. 2010;7:575–576.
- Ruta V, Chen J, MacKinnon R. Calibrated measurement of gating-charge arginine displacement in the KvAP voltage-dependent K⁺ channel. *Cell*. 2005;123:463–475.
- Hans M, Luvisetto S, Williams ME, Spagnolo M, Urrutia A, Tottene A, Brust PF, Johnson EC, Harpold MM, Stauderman KA, Pietrobon D. Functional consequences of mutations in the human alpha1A calcium channel subunit linked to familial hemiplegic migraine. *J Neurosci*. 1999;19:1610–1619.
- Kraus RL, Sinnegger MJ, Koschak A, Glossmann H, Stenirri S, Carrera P, Striessnig J. Three new familial hemiplegic migraine mutants affect P/Q-type Ca(2+) channel kinetics. *J Biol Chem*. 2000;275:9239–9243.
- Miki T, Zwingman TA, Wakamori M, Lutz CM, Cook SA, Hosford DA, Herrup K, Fletcher CF, Mori Y, Frankel WN, Letts VA. Two novel alleles of tottering with distinct Ca(v)2.1 calcium channel neuropathologies. *Neuroscience*. 2008;155:31–44.
- Dreier JP, Major S, Manning A, Woitzik J, Drenckhahn C, Steinbrink J, Tolias C, Oliveira-Ferreira AI, Fabricius M, Hartings JA, Vajkoczy P, Lauritzen M, Dirnagl U, Bohner G, Strong AJ. Cortical spreading ischaemia is a novel process involved in ischaemic damage in patients with aneurysmal subarachnoid haemorrhage. *Brain*. 2009;132:1866–1881.
- Dreier JP, Ebert N, Priller J, Megow D, Lindauer U, Klee R, Reuter U, Imai Y, Einhaupl KM, Victorov I, Dirnagl U. Products of hemolysis in the subarachnoid space inducing spreading ischemia in the cortex and focal necrosis in rats: a model for delayed ischemic neurological deficits after subarachnoid hemorrhage? *J Neurosurg*. 2000;93:658–666.
- Roitbak AI, Bobrov AV. Spreading depression resulting from cortical punctures. *Acta Neurobiol Exp (Wars)*. 1975;35:761–768.
- van den Maagdenberg AM, Pietrobon D, Pizzorusso T, Kaja S, Broos LA, Cesetti T, van de Ven RC, Tottene A, van der Kaa J, Plomp JJ, Frants RR, Ferrari MD. A *Cacna1a* knockin migraine mouse model with increased susceptibility to cortical spreading depression. *Neuron*. 2004;41:701–710.
- Koehler RC, Roman RJ, Harder DR. Astrocytes and the regulation of cerebral blood flow. *Trends Neurosci*. 2009;32:160–169.
- Tottene A, Conti R, Fabbro A, Vecchia D, Shapovalova M, Santello M, van den Maagdenberg AM, Ferrari MD, Pietrobon D. Enhanced excitatory transmission at cortical synapses as the basis for facilitated spreading depression in Ca(v) 2.1 knockin migraine mice. *Neuron*. 2009;61:762–773.
- Andreassen D, Friis UG, Uehnholt TR, Jensen BL, Skott O, Hansen PB. Coexpression of voltage-dependent calcium channels Cav1.2, 2.1a, and 2.1b in vascular myocytes. *Hypertension*. 2006;47:735–741.
- Windmuller O, Lindauer U, Foddis M, Einhaupl KM, Dirnagl U, Heinemann U, Dreier JP. Ion changes in spreading ischaemia induce rat middle cerebral artery constriction in the absence of NO. *Brain*. 2005;128:2042–2051.