

Paradoxical Association of Moyamoya Syndrome With Large Middle Cerebral Artery Aneurysm and Subarachnoid Hemorrhage

—Case Report—

Hidenori ENDO, Miki FUJIMURA, Takashi INOUE,
Hiroaki SHIMIZU*, and Teiji TOMINAGA*

Department of Neurosurgery, Kohnan Hospital, Sendai, Miyagi;

**Department of Neurosurgery, Tohoku University Graduate School of Medicine, Sendai, Miyagi*

Abstract

A 69-year-old woman was admitted to our hospital because of fluctuating dysarthria during the past 2 months. Magnetic resonance imaging revealed old cerebral infarction of the left cerebral hemisphere with acute subarachnoid hemorrhage in the left sylvian fissure. Cerebral angiography showed a large saccular aneurysm, 14 mm in diameter, at the bifurcation of the left middle cerebral artery (MCA) in association with moyamoya vasculopathy with atherosclerosis, including steno-occlusive changes at the bilateral terminal internal carotid arteries and abnormal net-like vessels at the base of the brain. She underwent microsurgical neck clipping of the large aneurysm followed by superficial temporal artery-MCA anastomosis without complication. Intraoperative findings showed no evidence of aneurysm rupture, suggesting that the subarachnoid hemorrhage was due to the intrinsic pathology of moyamoya vasculopathy. The postoperative course was uneventful, and the patient was discharged without neurological deficit. Association of moyamoya syndrome with large MCA aneurysm is extremely rare, and formation of large aneurysm at the vascular territory of an occluded vessel is apparently unique.

Key words: moyamoya syndrome, large cerebral aneurysm, middle cerebral artery aneurysm, subarachnoid hemorrhage

Introduction

Moyamoya disease is a progressive, occlusive cerebrovascular disease with unknown etiology characterized by bilateral steno-occlusive changes at the terminal portion of the internal carotid artery and abnormal vascular network at the base of the brain.^{1,2)} Moyamoya disease is frequently associated with intracranial aneurysms located within the abnormal basal network or the circle of Willis, probably as a result of the intrinsic pathology of moyamoya disease such as hemodynamic stress and fragile structure of the collateral vessels.^{4,5,7,8)} Most saccular aneurysms on the circle of Willis are located on the posterior circulation, and the association of moyamoya disease with middle cerebral artery (MCA) aneurysm is rare.⁵⁾ Furthermore, the association of moyamoya vasculopathy with large MCA aneurysm has not been reported previously. Here we report a rare case with adult onset moyamoya syndrome associated with large MCA aneurysm and subarachnoid hemorrhage (SAH).

Case Report

A 69-year-old woman was admitted to our hospital because of fluctuating dysarthria during the past 2 months. She had never complained of severe headaches. Magnetic resonance (MR) imaging incidentally found acute SAH along the left sylvian fissure (Fig. 1A, B). MR imaging also showed old cerebral infarction in the left posterior watershed area without recent cerebral infarction (Fig. 1C, D). Cerebral angiography showed a large saccular MCA aneurysm (14 mm diameter) with bleb at its posterior aspect, in association with steno-occlusive changes of the bilateral terminal internal carotid arteries and abnormal net-like vessels at the base of the brain (Fig. 2A). Atherosclerotic changes were found in the intracranial major arteries, leading to the diagnosis of moyamoya syndrome (akin-moyamoya disease) associated with atherosclerosis.¹¹⁾ Severe stenosis of the distal M1 segment, just proximal to the large aneurysm, was also observed (Fig. 2B). Collateral circulation for the cerebral blood flow from the external carotid artery was not detected (not shown). Xenon single photon emission computed tomography (SPECT) demonstrated that the cerebral blood flow and cerebral vascular reactivity were markedly com-

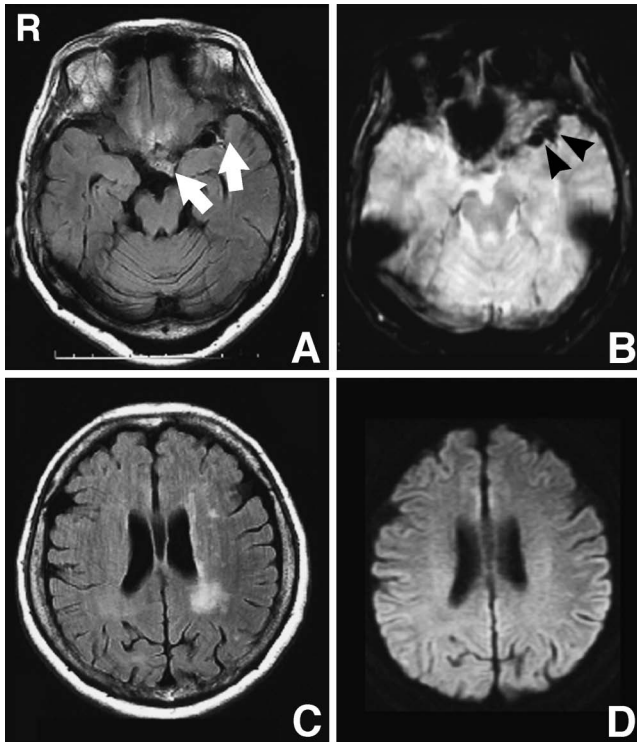


Fig. 1 Preoperative magnetic resonance images showing an area of high intensity on the fluid-attenuated inversion recovery (FLAIR) image (A, arrows) and low intensity on the T₂*-weighted image (B, arrowheads) in the left sylvian fissure indicating recent subarachnoid hemorrhage, and an area of high intensity on the FLAIR image (C) in the left posterior watershed area without abnormal signal on the diffusion-weighted image (D) indicating past history of cerebral infarction.

promised in the left cerebral hemisphere (not shown). Surgery was performed to inspect the source of silent bleeding and to prevent future ischemic stroke.

Left fronto-temporal craniotomy was performed. SAH was observed on the brain surface (Fig. 3A). The left sylvian fissure was split with evacuation of SAH in the fissure (Fig. 3B). Fragile microvessels had developed within the sylvian fissure. The aneurysm was carefully detached from the surrounding structure to observe the bleb on its posterior aspect (Fig. 3C). Inspection of the aneurysm found no evidence of recent rupture (Fig. 3D). Aneurysm clipping using multiple clips was performed with preservation of the M₂ portion and perforators (Fig. 3E). The distal M₁ portion had atherosclerotic appearance, which might correspond to the angiographic stenotic lesion. The parent artery (M₁ portion) was not occluded throughout the clipping procedure because the intra-aneurysmal pressure was relatively low for the size of the aneurysm. Motor evoked potentials monitored during clipping remained consistently normal. Superficial temporal artery (STA)-MCA single anastomosis was uneventfully performed to prevent future ischemic stroke (Fig. 3F).

MR imaging on the day after surgery revealed no ischemic or hemorrhagic complications (Fig. 4A, B). Post-

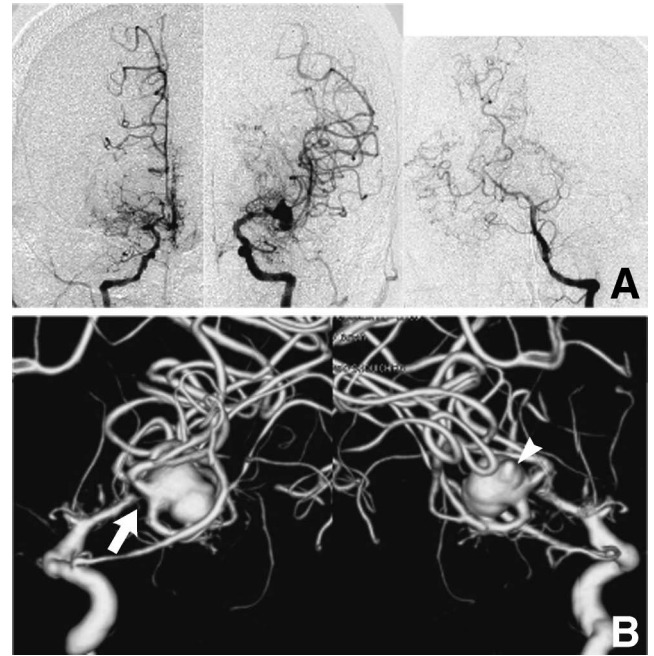


Fig. 2 A: Preoperative cerebral angiograms showing multiple stenotic changes around the circle of Willis with net-like moyamoya vessels and a left large middle cerebral artery aneurysm. B: Three-dimensional digital subtraction angiograms revealing severe stenosis of distal M₁ segment (arrow) and bleb at the posterior aspect of the aneurysm (arrowhead).

operative N-isopropyl-p-[¹²³I]iodoamphetamine SPECT findings during the acute stage after revascularization surgery showed significant improvement of cerebral blood flow in the left cerebral hemisphere (not shown). Her blood pressure was strictly controlled to avoid symptomatic cerebral hyperperfusion.²⁾ The patient was discharged 3 weeks after surgery without neurological deficit. Cerebral angiography 6 months after surgery revealed the patent STA-MCA bypass with no aneurysm filling (Fig. 4C-E). No antegrade blood flow from M₁ was evident due to the contribution of the bypass flow to the distal MCA territory. No cerebrovascular event occurred during the follow-up period of 6 months.

Discussion

A review found that 56% of the aneurysms associated with moyamoya disease occurred around the circle of Willis, 22% on the peripheral collateral vessels, and 18% in the basal ganglia.⁵⁾ Aneurysms around the circle of Willis predominantly developed in the posterior circulation, and only 2 of the 73 aneurysms within the circle of Willis arose on the MCA (2.7%), indicating that the association of moyamoya disease with MCA aneurysm is relatively rare, probably due to the lower hemodynamic stress on the MCA bifurcation in moyamoya disease. Few cases have discussed the size of the aneurysms, and moyamoya disease in association with large MCA aneurysm was unknown. The present case was considered to be

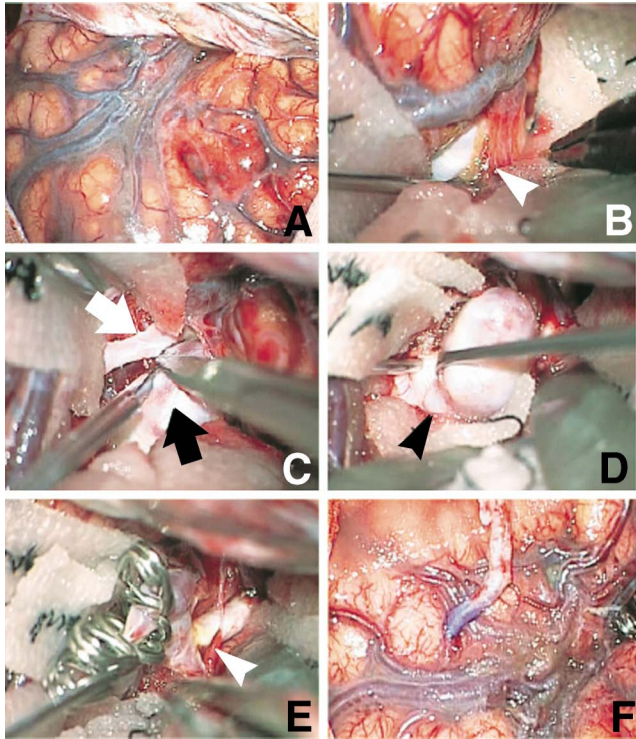


Fig. 3 Intraoperative photographs showing subarachnoid hemorrhage on the brain surface (A), evacuation of the thin subarachnoid hemorrhage (arrowhead) surrounding the aneurysm (B), M₂ segment (white arrow) separated from the aneurysm (black arrow) (C), little evidence of recent rupture around the aneurysm with the bleb (arrowhead) (D), clipping was performed using multiple clips, and atherosclerotic change of the distal M₁ portion (arrowhead) (E), and superficial temporal artery-middle cerebral artery single anastomosis was performed (F).

moyamoya syndrome with a background of atherosclerosis, but also represents large cerebral aneurysm of the MCA associated with moyamoya vasculopathy.

The present case was considered to develop cerebral ischemia and SAH in a relatively short period. Most patients with hemorrhagic-onset moyamoya disease have intracerebral hemorrhage (ICH) or intraventricular hemorrhage (IVH).⁶⁾ In contrast, the clinical manifestations of hemorrhagic moyamoya disease associated with intracranial aneurysms tend to be SAH (74%) rather than ICH (34%) or IVH (29%).⁵⁾ The incidence of aneurysm rupture associated with moyamoya disease is unclear. In the present case, the intraoperative findings indicated that the cause of SAH was not related to aneurysm rupture. Disruption of the transdural anastomosis is a possible cause of SAH.¹⁰⁾ The incidence of disease progression in adult moyamoya disease was proven to be higher than recognized before.⁹⁾ Atherosclerotic background of the disease might be involved in the disease progression in our case.

The underlying mechanism of this rare association is totally undetermined. Based on the observation that the peculiar hemodynamic stress in moyamoya disease con-

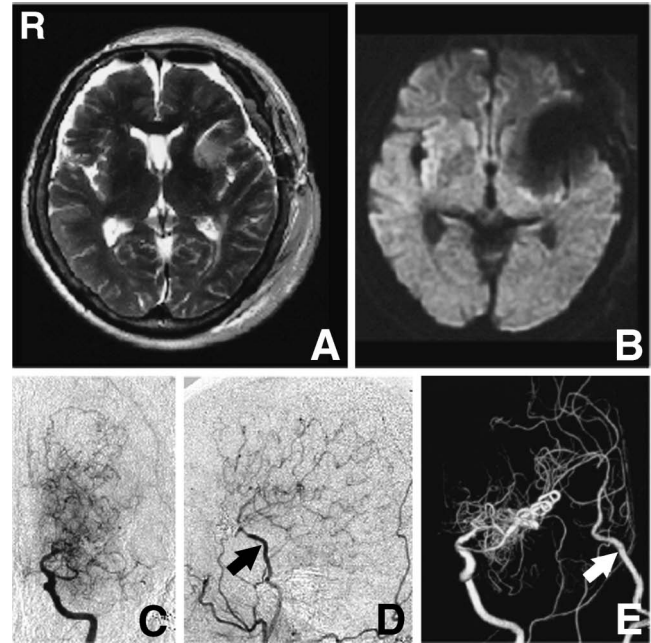


Fig. 4 A, B: T₂-weighted (A) and diffusion-weighted (B) magnetic resonance images obtained on the day after surgery showing no ischemic or hemorrhagic complications. C-E: Left internal carotid angiogram (C), left external carotid angiogram (D), and three-dimensional digital subtraction angiogram of the left common carotid artery (E) obtained 6 months after surgery showing no aneurysm filling, patent superficial temporal artery-middle cerebral artery bypass (arrow), and no antegrade blood flow from M₁ due to the contribution of the bypass flow to the distal middle cerebral artery territory.

tributes to the formation of cerebral aneurysm at the circle of the Willis,^{5,7,8)} the formation of large MCA aneurysm at the vascular territory of occlusive vessel is apparently unique. Furthermore, the intraoperative findings showed relatively low intra-aneurysmal pressure and no evidence of aneurysm rupture. These findings might support the idea of initial occurrence of the cerebral aneurysm with subsequent development of moyamoya vasculopathy. Whether this association was incidental or had a shared background remains unclear. Recent studies have shown the importance of inflammatory response in the pathogenesis of cerebral aneurysm and moyamoya angiopathy.^{1,3)} Therefore, inflammatory response might be one of the potential mechanisms of this rare association.

References

- 1) Aoki T, Kataoka H, Morimoto M, Nozaki K, Hashimoto N: Macrophage-derived matrix metalloproteinase-2 and -9 promote the progression of cerebral aneurysms in rats. *Stroke* 38: 162-169, 2007
- 2) Fujimura M, Mugikura S, Kaneta T, Shimizu H, Tominaga T: Incidence and risk factors for symptomatic cerebral hyperperfusion after superficial temporal artery-middle cerebral artery anastomosis in patients with moyamoya disease. *Surg Neurol* 71: 442-447, 2009

- 3) Fujimura M, Watanabe M, Narisawa A, Shimizu H, Tomi-
ga T: Increased expression of serum matrix metal-
loproteinase-9 in patients with moyamoya disease. *Surg
Neurol* 72: 476-480, 2009
- 4) Iwama T, Todaka T, Hashimoto N: Direct surgery for major
artery aneurysm associated with moyamoya disease. *Clin
Neurol Neurosurg* 99 Suppl 2: S191-193, 1997
- 5) Kawaguchi S, Sakaki T, Morimoto T, Kakizaki T, Kamada K:
Characteristics of intracranial aneurysms associated with
moyamoya disease. A review of 111 cases. *Acta Neurochir
(Wien)* 138: 1287-1294, 1996
- 6) Kobayashi E, Saeki N, Oishi H, Hirai S, Yamaura A: Long-
term natural history of hemorrhagic moyamoya disease in
42 patients. *J Neurosurg* 93: 976-980, 2000
- 7) Kodama N, Sato M, Sasaki T: Treatment of ruptured cerebral
aneurysm in moyamoya disease. *Surg Neurol* 46: 62-66, 1996
- 8) Kuroda S, Houkin K, Kamiyama H, Abe H: Effects of surgi-
cal revascularization on peripheral artery aneurysms in
moyamoya disease: report of three cases. *Neurosurgery* 49:
463-468, 2001
- 9) Kuroda S, Ishikawa T, Houkin K, Nanba R, Hokari M,
Iwasaki Y: Incidence and clinical features of disease
progression in adult moyamoya disease. *Stroke* 36:
2148-2153, 2005
- 10) Marushima A, Yanaka K, Matsuki T, Kojima H, Nose T:
Subarachnoid hemorrhage not due to ruptured aneurysm in
moyamoya disease. *J Clin Neurosci* 13: 146-149, 2006
- 11) Research on intractable diseases of the Ministry of Health,
Labour and Welfare, Japan: [Recommendations for the
Management of Moyamoya Disease. A Statement from
Research Committee on Spontaneous Occlusion of the Cir-
cle of Willis (Moyamoya Disease)]. *Surgery for Cerebral
Stroke* 37: 321-337, 2009 (Japanese)
- 12) Suzuki J, Takaku A: Cerebrovascular "moyamoya" disease.
Disease showing abnormal net-like vessels in base of brain.
Arch Neurol 20: 288-299, 1969

Address reprint requests to: Miki Fujimura, M.D., Ph.D., Depart-
ment of Neurosurgery, Kohnan Hospital, 4-20-1
Nagamachi-minami, Taihaku-ku, Sendai 982-8523, Japan.
e-mail: fujimur@kohnan-sendai.or.jp