



University
of Glasgow

Cooper, S.A., Joshi, A.C., Seenan, P.J., Hadley, D.M., Muir, K.W.,
Leigh, R.J., and Metcalfe, R.A. (2012) *Akinetopsia: acute presentation
and evidence for persisting defects in motion vision*. *Journal of
Neurology, Neurosurgery & Psychiatry* 83 (2). pp. 229-230.
ISSN 0022-3050

<http://eprints.gla.ac.uk/61428/>

Deposited on: 10 April 2012

Funding GG was funded by the Stroke Association.

Competing interests None.

Ethics approval This study was conducted with the approval of the St George's University Ethical Committee.

Provenance and peer review Not commissioned; externally peer reviewed.

Received 24 June 2010

Revised 15 October 2010

Accepted 19 November 2010

Published Online First 4 January 2011

J Neurol Neurosurg Psychiatry 2012;**83**:228–229.
doi:10.1136/jnnp.2010.222091

REFERENCES

1. Rothwell PM, Giles MF, Chandratheva A, *et al.* Effect of urgent treatment of transient ischaemic attack and minor stroke on early recurrent stroke (EXPRESS study): a prospective population-based sequential comparison. *Lancet* 2007;**370**:1432–42.
2. Kothari RU, Pancioli A, Liu T, *et al.* Cincinnati prehospital stroke scale: reproducibility and validity. *Ann Emerg Med* 1999;**33**:373–8.
3. Johnston SC, Rothwell PM, Nguyen-Huynh MN, *et al.* Validation and refinement of scores to predict very early stroke risk after transient ischaemic attack. *Lancet* 2007;**369**:283–92.
4. Gulli G, Khan S, Markus HS. Vertebrobasilar stenosis predicts high early recurrent stroke risk in posterior circulation stroke and TIA. *Stroke* 2009;**40**:2732–7.
5. Harbison J, Hossain O, Jenkinson D, *et al.* Diagnostic accuracy of stroke referrals from primary care, emergency room physicians, and ambulance staff using the face arm speech test. *Stroke* 2003;**34**:71–6.

Akinetopsia: acute presentation and evidence for persisting defects in motion vision

Akinetopsia—selective loss of motion vision—is rarely described.^{1,2} Current evidence indicates that the brain treats moving stimuli as a distinct feature of vision.^{2,3} Thus, electrophysiological studies have identified cortical areas in the macaque monkey that encode the direction and speed of moving visual stimuli in visual area V5 and adjacent medial superior temporal visual area (MST).^{2,3} Inactivating V5/MST in macaque monkeys induces defects of motion vision that are evident with psychophysical testing or measurement of ocular tracking.^{2,3} Akinetopsia in patients after lesions such as stroke rarely persists, probably because several cortical areas contribute to human perception.² Here, we present a patient's personal account of acute transient akinetopsia following stroke, and report how a patient with transient akinetopsia due a stroke 23 years previously still shows evidence of abnormal motion vision, based on his ocular tracking.

Patient 1 is a 61-year-old woman who sought medical advice the morning after sudden onset of visual disturbance. She had been well, apart from a mild bi-frontal headache until leaving work the preceding

day. Travelling home she suddenly noticed that, although static objects appeared normal, smooth movements of people were seen as a series of discontinuous 'freeze frames'. The opening of a train door was 'broken up' and those nearby appeared to 'move in slow motion'. She was startled when surrounding passengers 'suddenly moved'. Recognition of people or objects and visual acuity was preserved. These symp-

toms were unchanged when admitted to hospital 22 h later. She was an ex-smoker of 22 years with an unremarkable past medical history. Her only medication was celecoxib for osteoarthritis. Her account can be found in the accompanying online video.

Her general examination was normal; blood pressure was 167/69. Pursuit and saccadic eye movements were intact on examination but not measured. Colour

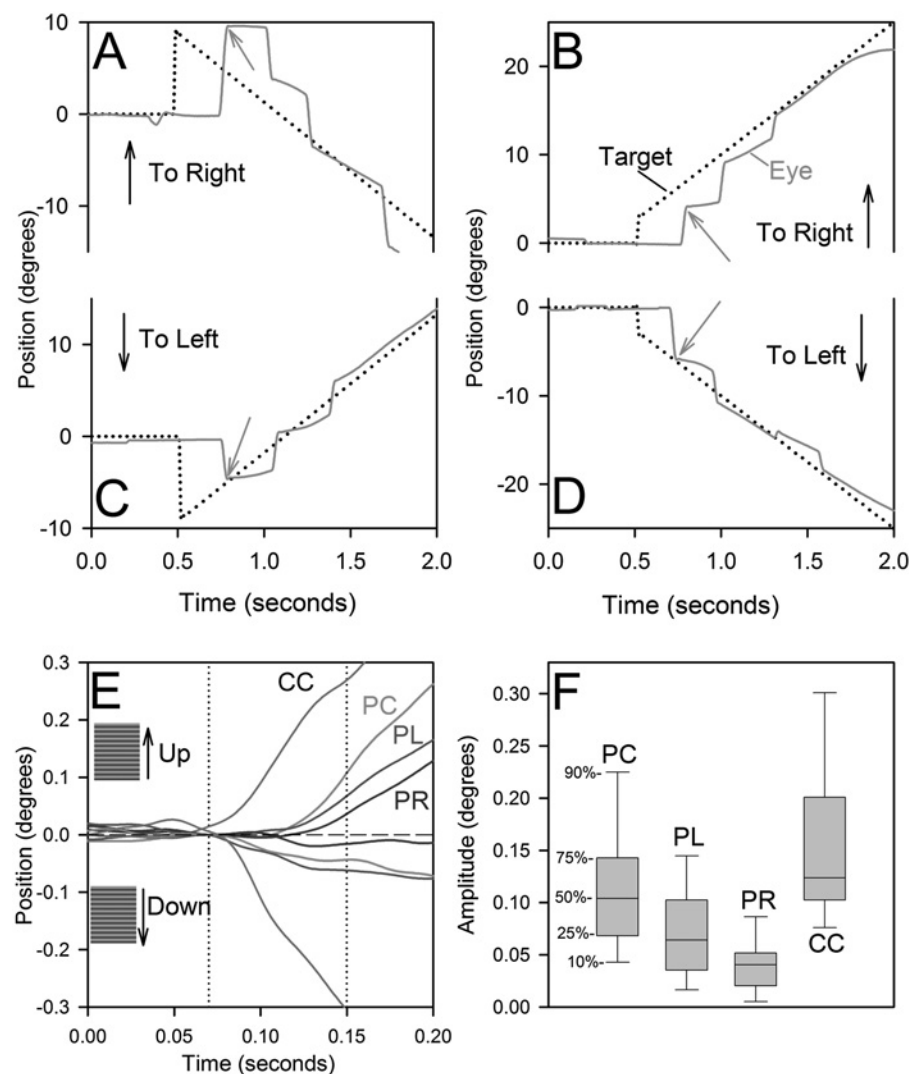


Figure 1 Ocular tracking responses of Patient 2. (A–D) Tracking of small laser target. When the target was stepped into his right visual hemifield and ramped either to the left (A) or right (B), in both cases, his initial saccade was appropriate in size for the step but did not take into account the subsequent ramp so that his eye landed off target (grey arrows). When the target was stepped into his left visual hemifield and ramped either to the right (C) or left (D), his initial saccade was accurate (grey arrows), indicating that both the step and ramp were taken into account. (E,F) Ocular following responses (OFRs) of a vertically moving grating, with spatial frequency 0.17 degrees/cycle. (E) Mean responses for Patient 2 when he viewed the display presented in his central visual field (PC), left visual hemifield (PL) or right visual hemifield (PR). Also shown are mean responses of a representative control subject when he viewed the display in his central visual field (CC). All responses of Patient 2 are smaller than those of the control subject, especially downwards, and the smallest responses occur during stimulation of his right visual hemifield. (F) Comparison of upward OFR of Patient 2 during the three viewing conditions and six control subjects during central viewing; percentiles of this box plot are indicated on the left. All of the patient's responses are significantly smaller than those of control subjects, and responses during stimulation of Patient 2's right visual hemifield are significantly smaller than any other set of responses ($p < 0.02$, Mann–Whitney rank sum test).

vision and visual fields were normal. Her neurological examination was unremarkable. After 2 days her symptoms improved and had resolved by day five. MRI demonstrated tiny multifocal areas of restricted diffusion (hyperintensity on diffusion-weighted imaging (DWI) and hypointensity on apparent diffusion coefficient map) consistent with recent infarcts in the cortex and subcortical white matter of the inferior parietal lobe and parietal–occipital junction on the right (online supplementary figure 1). Lesions were not detected in her left cerebral hemisphere.

Patient 2 is a 79-year-old former engineer who suffered a left posterior hemispheric stroke at the age of 56, in 1986, causing dyslexia and dyscalculia (see online supplementary data).⁴ Soon afterwards, he became aware that objects moving in his right visual hemifield appeared to jump from one location to the next. Thus, when he watched birds flying outside his hospital window, if they appeared in his right visual hemifield, they seemed to jump rather than move smoothly. All symptoms improved within a month, although he is still aware of mild difficulties estimating the speed of objects in his right visual hemifield. When studied in 1986, he showed a defect of both saccade and pursuit tracking of targets moving in his right, but not in his left, visual hemifield.⁴ This defect was similar to that reported following experimental lesions of extrafoveal V5,^{2,3} and MRI demonstrated a left-sided hemorrhagic infarction affecting Brodmann areas 37 and 19.⁴

When re-evaluated in 2009, uncorrected visual acuity was 20/20 OD and 20/50 OS and he had a homonymous, partial, right superior visual quadrant defect; however, he could easily see the visual stimuli we used. We measured (search coil) ocular tracking of step and step-ramp motion of a small target (figure 1A–D and online supplementary data).⁵ If the stimulus moved in his right visual hemifield, the initial saccade was inaccurate; however, saccades to targets moving in his left visual hemifield were generally on target. Saccades to appearance of static targets in either hemifield showed no significant asymmetry. Thus, his retinotopic tracking defect persisted after 23 years.⁴ We also tested motion vision in his central field, and each hemifield, by measuring the ocular following response (OFR) to vertically moving sine-wave gratings.⁵ Comparisons of Patient 2's mean OFR with those of a control subject are displayed in figure 1E; all of his responses are smaller than those of the control subject, and responses during stimulation of his right visual hemifield are smallest. Comparison of all upward OFRs from Patient 2 and six control subjects are shown in figure 1F. Patient 2's OFRs during stimulation of his right visual hemifield were significantly smaller than during stimulation of his left or central visual fields, and all of his responses were smaller than those of control subjects.

These two patients with akinetopsia document several features of this rare disorder. Patient 1 demonstrated how akinetopsia may present as a spectacular and isolated visual disturbance, affecting the whole visual field. The cerebral lesions causing her global akinetopsia were detected in only the right hemisphere. Signal changes on MRI affected her right inferior parietal lobe and parietal–occipital junction, but spared the homologue of V5. These findings are consistent with studies indicating that rostro-dorsal parietal, occipito-parietal and superior parietal cortex may all contribute to global motion processing.^{2,3} However, the pattern of scattered tiny foci of DWI hyperintensity is consistent with spontaneous fragmentation of thrombus and reperfusion. Without perfusion imaging shortly after the ictus, it remains possible that the initial ischaemic insult was more extensive, or even bilateral. Thus, our MRI findings cannot definitively localise the anatomical substrate for her akinetopsia.

Patient 2 reported disturbance of motion vision restricted to his right visual hemifield, and his left-hemisphere lesion encompassed modern estimates of the human homologue for V5.⁴ Twenty-three years later, he reported only minor, persisting disturbance of motion vision, but showed a persisting retinotopic defect of tracking (figure 1) consistent with an extrafoveal V5 lesion.² His OFR was more impaired for stimuli presented in his right visual hemifield.

In summary, akinetopsia can present as an acute but transient phenomenon affecting the complete visual field due to unilateral cerebral lesions at more than one site. Long after symptomatic akinetopsia has resolved, disturbance of motion vision may be detected by abnormal tracking eye movements.

**Sarah A Cooper,¹ Anand C Joshi,^{2,3}
Pamela J Seenan,⁴ Donald M Hadley,⁵
Keith W Muir,⁶ R John Leigh,^{2,3}
Richard A Metcalfe¹**

¹Department of Neurology, Institute of Neurological Sciences, Southern General Hospital, Glasgow, UK;

²Department of Neurology, Veterans Affairs Medical Center and Case Western Reserve University, Cleveland, Ohio, USA;

³Department of Biomedical Engineering, Veterans Affairs Medical Center and Case Western Reserve University, Cleveland, Ohio, USA;

⁴Gartnavel General Hospital, Great Western Road, Glasgow, UK;

⁵Department of Neuroradiology, Institute of Neurological Sciences, Southern General Hospital, Glasgow, UK;

⁶Division of Clinical Neurosciences, University of Glasgow, Southern General Hospital, Glasgow, UK

Correspondence to Dr Richard Metcalfe, Institute of Neurological Sciences, Southern General Hospital, Glasgow, G51 4TF, UK; Richard.Metcalfe@glasgow.ac.uk

► Additional materials are published online only. To view these files please visit the journal online (<http://jnp.bmj.com/content/83/2.toc>).

Competing interests None.

Patient consent Obtained.

Provenance and peer review Not commissioned; externally peer reviewed.

Received 13 July 2010

Revised 18 November 2010

Accepted 20 November 2010

Published Online First 8 January 2011

J Neurol Neurosurg Psychiatry 2012;**83**:229–230.
doi:10.1136/jnnp.2010.223727

REFERENCES

1. **Barton JJS.** Disorders of higher visual function. In: Kennard C, Leigh RJ, eds. *Handbook of Neurology; Neuro-Ophthalmology*. London: Elsevier, 2011.
2. **Shipp S,** de Jong BM, Zihl J, *et al.* The brain activity related to residual motion vision in a patient with bilateral lesions of V5. *Brain* 1994;**117**:1023–38.
3. **Leigh RJ,** Zee DS. *The Neurology of Eye Movements*. 4th edn. New York: Oxford University Press, 2006.
4. **Thurston SE,** Leigh RJ, Crawford T, *et al.* Two distinct deficits of visual tracking caused by unilateral lesions of cerebral cortex in humans. *Ann Neurol* 1988;**23**:266–73.
5. **Joshi AC,** Riley DE, Mustari MJ, *et al.* Selective defects of visual tracking in progressive supranuclear palsy (PSP): implications for mechanisms of motion vision. *Vision Res* 2010;**50**:761–71.

Cerebellar-type multiple system atrophy presenting with leucoencephalopathy

In June 2004, a 52-year-old woman was admitted to our department with a walking impairment and scanning speech that had persisted over the previous few months. A neurological examination revealed exclusively cerebellar signs with gait ataxia, slight oculomotor dysfunction and impaired coordination. Known medical and family history were unremarkable up to this point (however, no information could be provided on the patient's father). MRI scans showed a severe cerebellar atrophy of both hemispheres without any additional pathologies. Electrophysiological (evoked potentials) and blood examination, including vitamin E, vitamin B12, antineuronal antibodies and genetic testing for spinocerebellar ataxia genotypes 1, 2, 3 and 6, were negative for pathological findings. Over the following months the patient developed neurogenic bladder dysfunction with urge incontinence and incomplete bladder release, thus fulfilling the consensus criteria for probable multiple system atrophy of the cerebellar type (MSA-C).¹

We initiated a single photon emission tomography investigation, which revealed a striatal dopaminergic deficit and down-regulation of postsynaptic dopamine receptors; MIBG scans of the heart remained normal. The patient was treated with amantadine up to 300 mg/day without showing any significant improvement. Over time, the disease slowly progressed: the patient needed constant support when walking and she complained of cognitive deficits but there were still no signs of parkinsonism. As the initial MRI scans lacked characteristic findings for MSA-C,² we repeated the MRI scans at the end of 2006. As expected, cerebellar



Akinetopsia: acute presentation and evidence for persisting defects in motion vision

Sarah A Cooper, Anand C Joshi, Pamela J Seenan, et al.

J Neurol Neurosurg Psychiatry 2012 83: 229-230 originally published online January 8, 2011
doi: 10.1136/jnp.2010.223727

Updated information and services can be found at:
<http://jnp.bmj.com/content/83/2/229.full.html>

	<i>These include:</i>
References	This article cites 3 articles, 1 of which can be accessed free at: http://jnp.bmj.com/content/83/2/229.full.html#ref-list-1
Email alerting service	Receive free email alerts when new articles cite this article. Sign up in the box at the top right corner of the online article.

Notes

To request permissions go to:
<http://group.bmj.com/group/rights-licensing/permissions>

To order reprints go to:
<http://journals.bmj.com/cgi/reprintform>

To subscribe to BMJ go to:
<http://group.bmj.com/subscribe/>