

Significance of Focal Cerebral Hyperperfusion as a Cause of Transient Neurologic Deterioration After Extracranial-Intracranial Bypass for Moyamoya Disease: Comparative Study With Non-Moyamoya Patients Using N-Isopropyl-p-[¹²³I]Iodoamphetamine Single-Photon Emission Computed Tomography

Miki Fujimura, MD*
Hiroaki Shimizu, MD‡
Takashi Inoue, MD*
Shunji Mugikura, MD§
Atsushi Saito, MD‡
Teiji Tominaga, MD‡

*Department of Neurosurgery, Kohnan Hospital, Sendai, Japan; Departments of ‡Neurosurgery and §Radiology, Tohoku University Graduate School of Medicine, Sendai, Japan

Correspondence:

Miki Fujimura, MD, PhD,
Department of Neurosurgery,
Kohnan Hospital,
4-20-1 Nagamachi-minami,
Taihaku-ku, Sendai 982-8523, Japan.
E-mail: fujimur@kohnan-sendai.or.jp

Received, March 30, 2010.

Accepted, August 16, 2010.

Copyright © 2011 by the
Congress of Neurological Surgeons

BACKGROUND: Superficial temporal artery-middle cerebral artery (STA-MCA) anastomosis prevents cerebral ischemic attack by improving cerebral blood flow in patients with occlusive cerebrovascular disease and hemodynamic compromise. Recent evidence suggests that focal cerebral hyperperfusion is a potential complication of this procedure for moyamoya disease.

OBJECTIVE: To clarify the exact differences in the incidence and clinical manifestations of this phenomenon between patients with and without moyamoya disease.

METHODS: N-isopropyl-p-[¹²³I]iodoamphetamine single-photon emission computed tomography was performed 1 and 7 days after STA-MCA anastomosis on 121 hemispheres from 86 consecutive patients with moyamoya disease (2-67 years of age; mean, 34.3 years) and on 28 hemispheres from 28 non-moyamoya patients (12-67 years of age; mean, 56.5 years). The incidence of symptomatic hyperperfusion, defined as a significant focal increase in cerebral blood flow at the site of the anastomosis that is responsible for the apparent neurological signs, was compared between groups.

RESULTS: Symptomatic cerebral hyperperfusion including mild focal neurological signs was seen in 25 patients with moyamoya disease (26 hemispheres, 21.5%) but in none of the patients without moyamoya disease ($P = .0069$). Multivariate analysis revealed that moyamoya disease was significantly associated with the development of symptomatic cerebral hyperperfusion ($P = .0008$). All patients with symptomatic hyperperfusion were relieved by intensive blood pressure control, and no patients suffered from permanent neurological deficit caused by hyperperfusion.

CONCLUSION: Symptomatic cerebral hyperperfusion is a potential complication of STA-MCA anastomosis, especially in patients with moyamoya disease. Accurate diagnosis and adequate management of hyperperfusion are recommended, especially in patients with moyamoya disease.

KEY WORDS: Cerebral hyperperfusion, Extracranial-intracranial bypass, Moyamoya disease, Surgical complication

Neurosurgery 68:957–965, 2011

DOI: 10.1227/NEU.0b013e318208f1da

www.neurosurgery-online.com

ABBREVIATIONS: EC-IC, extracranial-intracranial; ICH, intracerebral hemorrhage; ¹²³I-IMP-SPECT, N-isopropyl-p-[¹²³I]iodoamphetamine single-photon emission computed tomography; MRA, magnetic resonance angiography; SAH, subarachnoid hemorrhage; STA-MCA, superficial temporal artery–middle cerebral artery

Cerebrovascular reconstruction surgery including carotid endarterectomy or extracranial-intracranial (EC-IC) bypass for patients with atherosclerotic steno-occlusive cerebrovascular diseases can cause a rapid increase in cerebral blood flow (CBF) in the chronic ischemic brain, resulting in complications such as

cerebral hyperperfusion syndrome. Cerebral hyperperfusion syndrome after carotid endarterectomy is characterized by unilateral headache, face and eye pain, seizures, and focal symptoms that occur secondary to cerebral edema or intracerebral hemorrhage (ICH).¹⁻⁴ Patients with poorer cerebrovascular reactivity are known to have higher risk for hyperperfusion syndrome.⁴⁻⁷ In contrast, cerebral hyperperfusion syndrome after EC-IC bypass for atherosclerotic occlusive cerebrovascular disease is rare and mostly manifests as mild focal neurological deficit,^{8,9} except for 1 case of acute hyperperfusion with massive ICH after high-flow EC-IC bypass.¹⁰

Moyamoya disease is a chronic, occlusive cerebrovascular disease with unknown origin characterized by bilateral stenotic changes at the terminal portion of the internal carotid artery and an abnormal vascular network at the base of the brain.¹¹ EC-IC bypass such as superficial temporal artery–middle cerebral artery (STA-MCA) anastomosis is generally the standard surgical treatment for moyamoya disease to prevent cerebral ischemic attacks.¹²⁻¹⁵ Despite the favorable long-term outcome,¹²⁻¹⁵ increasing evidence suggests that focal cerebral hyperperfusion may cause transient neurological deterioration^{12,16-22} or delayed ICH²³ during the acute stage after EC-IC bypass for moyamoya disease. These results strongly suggest that patients with moyamoya disease are more vulnerable to cerebral hyperperfusion compared with patients with other occlusive cerebrovascular diseases. However, the differences in the incidence and clinical manifestation of cerebral hyperperfusion between patients with and without moyamoya disease have not been evaluated.

The present prospective study performed *N*-isopropyl-*p*-[¹²³I]iodoamphetamine single-photon emission computed tomography (¹²³I-IMP-SPECT) 1 and 7 days after STA-MCA (M4) anastomosis in 121 hemispheres of 86 consecutive patients with moyamoya disease and 28 hemispheres of 28 patients without moyamoya disease to compare the incidences of symptomatic cerebral hyperperfusion.

PATIENTS AND METHODS

Inclusion Criteria

The postoperative changes in CBF and clinical course were investigated in 86 consecutive patients (moyamoya group; male/female = 24/62; age, 2-67 years; mean age, 34.3 years) with moyamoya disease surgically treated in 121 hemispheres by the same surgeon (M.F.) from March 2004 to June 2009. For comparison, the postoperative changes in CBF and clinical course were also investigated in 28 patients (non-moyamoya group; male/female = 24/4; age, 12-67 years; mean age, 56.3 years), including 27 adult patients with atherosclerotic occlusive cerebrovascular disease and 1 pediatric patient with MCA occlusion probably caused by dissection, who were surgically treated in 28 affected hemispheres. Inclusion criteria of this study, corresponding to our surgical indications for STA-MCA anastomosis, included all of the following: the presence of ischemic symptoms, apparent hemodynamic compromise by SPECT, independent activity of daily living (modified Rankin scale scores, 0-2), and absence of major cerebral infarction. All hemispheres that did not match these criteria were excluded from the

initial surgery. Once hemodynamic compromise was confirmed, the patients underwent revascularization surgery. All patients in the moyamoya group underwent STA-MCA (M4) anastomosis with or without encephalo-duro-myo-synangiosis.^{12,16} All patients in the non-moyamoya group underwent STA-MCA (M4) anastomosis without indirect pial synangiosis. All patients in the moyamoya group satisfied the diagnostic criteria of the Research Committee on Spontaneous Occlusion of the Circle of Willis of the Ministry of Health, Labor, and Welfare, Japan, except for 4 patients with “probable moyamoya disease” with unilateral involvement. All patients were strictly followed up in our institutes for > 6 months with a mean follow-up period of 45.6 months.

Postoperative CBF Measurement and Diagnosis of Hyperperfusion

The CBF was routinely measured by ¹²³I-IMP-SPECT 1 and 7 days after surgery in all patients in both groups. The CBF was quantified by the autoradiographic method; the CBF in each subregion of the cerebral cortex was automatically calculated by the Three-Dimensional Stereotactic Region of Interest Template software (version 2) provided by Daiichi Radio-Isotope (Tokyo, Japan), and the diagnosis of cerebral hemodynamics was made by 2 specialized radiologists blinded to the clinical condition of the patients.^{12,20} Within 2 days after surgery, 1.5- or 3-T magnetic resonance imaging (MRI) and magnetic resonance angiography (MRA) were routinely performed.¹⁹ MRI included diffusion-weighted images, fluid-attenuated inversion recovery images, T1-/T2-weighted images, and T2*-weighted images. The diagnostic criteria for symptomatic cerebral hyperperfusion included all of the following^{12,20}: the presence of a significant focal increase in CBF at the site of the anastomosis (qualitative observation of focal intense increase in CBF confined to 1 major vascular territory), which is responsible for the apparent neurological signs including focal neurological deficit and/or severe headache resulting from hemorrhagic changes; apparent visualization of STA-MCA bypass by MRA and the absence of any ischemic changes by diffusion-weighted imaging; and the absence of other pathologies such as compression of the brain surface by the temporal muscle inserted for indirect pial synangiosis, ischemic attack, and seizure.

The occurrence of symptomatic cerebral hyperperfusion after revascularization surgery was evaluated by ¹²³I-IMP-SPECT in the acute stage. The mortality and morbidity resulting from cerebral hyperperfusion were also evaluated 3 months after revascularization surgery. We investigated the correlation between postoperative CBF changes and clinical presentation in both groups and compared the incidence of symptomatic cerebral hyperperfusion between the moyamoya group and non-moyamoya group.

Statistical Analysis

The incidence of symptomatic cerebral hyperperfusion was compared between the moyamoya and non-moyamoya groups by χ^2 test. Because age and history of intracranial hemorrhage were known to be related to symptomatic cerebral hyperperfusion after STA-MCA anastomosis for moyamoya disease,¹² multivariate statistical analysis of the factors related to development of symptomatic cerebral hyperperfusion, including disease subtype, age, sex, operated side, and history of intracranial hemorrhage, was performed with a logistic regression model. The incidence of any cerebral hyperperfusion (both symptomatic and asymptomatic) was also compared between the moyamoya and non-

moyamoya groups. Correlation between age and development of symptomatic cerebral hyperperfusion was evaluated in the moyamoya group by the Student *t* test. Systolic blood pressure 1 day after surgery was compared between the moyamoya group and non-moyamoya group by the Student *t* test.

RESULTS

Moyamoya Group

Among the 86 consecutive patients with 121 operated hemispheres, 25 patients (26 hemispheres, 21.5% of 121 operated hemispheres) suffered from temporary neurological deterioration, including mild focal neurological signs, resulting from postoperative focal cerebral hyperperfusion from 2 to 14 days after surgery (Table 1). Postoperative MRI/MRA showed no ischemic changes, and the thick high signal intensity of the STA on the operated hemisphere was evident in all 26 hemispheres. Postoperative SPECT revealed significant intense increases in CBF at the sites of anastomosis on all 26 hemispheres. As Table 2 summarizes, 21 patients (22 hemispheres, 18.2%) suffered from transient focal neurological deficit caused by focal hyperperfusion that mimicked ischemic attack, which started from 2 to 9 days after surgery and was sustained for several days. The anatomic location and the temporal profile of hyperperfusion were completely in accordance with the transient neurological signs in these 21 patients. Four patients (4 hemispheres, 3.3%) complained of severe headache and suffered from cerebral hyperperfusion syndrome associated with subarachnoid hemorrhage (SAH) in 3 patients (2.5%) or with ICH at the right frontal subcortex in 1 patient (0.83%). Symptoms were relieved by intensive blood pressure control with the use of the free radical scavenger edaravone (Mitsubishi Pharma Co, Tokyo, Japan), although 1 patient with ICH required rehabilitation to relieve transient left hemiparesis for 2 months.²³ One patient with significant bilateral flow compromise manifesting as SAH required ligation of the STA-MCA bypass 2 days after the first-stage surgery to control postoperative cerebral hyperperfusion and was rescued by marked development of pial synangiosis without complication. No patient suffered from permanent neurological deficit caused by cerebral hyperperfusion. No patients suffered from delayed neurological deterioration resulting from cerebral hyperperfusion during the follow-up period. Cerebral hyperperfusion, both

asymptomatic and symptomatic, was detected by SPECT in 60.3% (73 of 121 hemispheres) in the moyamoya group.

Among 86 consecutive patients with 121 operated hemispheres in the moyamoya group, no patient suffered from perioperative cerebral infarction, except for 3 patients (2.5%) presenting with pseudolaminar necrosis in the part of the cerebral cortex supplied by the STA-MCA bypass in the subacute stage, which did not affect their long-term neurological status. All patients with the onset of transient ischemic attack obtained disappearance or improvement of ischemic attack during the follow-up period. One ischemia-onset patient (0.83%) suffered from ICH on the ipsilateral thalamus 3 years after successful revascularization surgery, and she suffered deteriorated modified Rankin scale score from 0 to 3 after hemorrhage. Two hemorrhage-onset patients suffered from rebleeding (1.65%), 1 from contralateral ICH and 1 from SAH, both of which did not affect their neurological status. The patency of the STA-MCA bypass was confirmed in all 86 patients with 121 operated hemispheres by postoperative MRA.

Non-Moyamoya Group

Among 28 patients with 28 operated hemispheres in the non-moyamoya group, no patient (0 of 28, 0%) suffered from symptomatic cerebral hyperperfusion. No patient suffered from perioperative cerebral infarction by postoperative MRI, and the patency of STA-MCA bypass was confirmed by MRA in all 28 patients. No patient suffered cerebral ischemic events such as transient ischemic attack and recurrent stroke during the follow-up period. One patient presented with simple partial seizure of his right upper extremity several hours after left STA-MCA anastomosis, whereas ¹²³I-IMP-SPECT 1 day after surgery demonstrated only mild increase in CBF at the left fronto-parietal lobe. On the basis of the effect of seizure on subsequent flow study and equivocal finding of ¹²³I-IMP-SPECT, we did not include this case as symptomatic cerebral hyperperfusion. No other patients in the non-moyamoya group suffered from seizure postoperatively. Cerebral hyperperfusion, both asymptomatic and symptomatic, was detected by SPECT in 67.9% (19 of 28 hemispheres) in the non-moyamoya group.

Statistical Analysis

The incidence of symptomatic cerebral hyperperfusion was significantly higher in the moyamoya group (26 of 121, 21.5%) compared with the non-moyamoya group (0 of 28, 0%; *P* = .0069). The incidence of hemorrhagic cerebral hyperperfusion was 3.3% (4 of 121) in the moyamoya group, whereas no hemorrhagic complication occurred in the non-moyamoya group (0 of 28), although there was no statistical significance between groups (*P* = .33). There was no significant difference in the incidence of any cerebral hyperperfusion, both asymptomatic and symptomatic, between the moyamoya group (73 of 121, 60.3%) and non-moyamoya group (19 of 28, 67.9%; *P* = .46). Multivariate analysis revealed that the disease subtype of moyamoya disease was significantly associated with the development of

TABLE 1. Incidence of Symptomatic Cerebral Hyperperfusion After Extracranial-Intracranial Bypass

	Moyamoya	Non-Moyamoya
Hemispheres, n (patients, n)	121 (86)	28 (28)
Age (mean), y	2–67 (34.3)	12–67 (56.5)
Male/female, n	24/62	24/4
Symptomatic hyperperfusion, n (%)	26 (21.5) ^a	0 (0)

^aSignificantly higher (*P* = .0069).

TABLE 2. Incidence of Symptomatic Cerebral Hyperperfusion After Extracranial-Intracranial Bypass in 86 Patients With Moyamoya Disease^a

	Hemisphere, n (Incidence, %)	Symptomatic Period, d	Brain Damage Caused by Hyperperfusion	Permanent Neurological Deficit Caused by Hyperperfusion
Symptomatic hyperperfusion	26 (21.5)			
Focal neurological deficit	22 (18.2)	2–14	None	None
SAH	3 (2.5)	1–2	None	None
ICH	1 (0.8)	≥ 4	Minimum	None

^aICH, intracerebral hemorrhage; SAH, subarachnoid hemorrhage.

symptomatic cerebral hyperperfusion ($P = .0008$), as shown in Table 3. Age was also found to be associated with symptomatic cerebral hyperperfusion by multivariate analysis ($P = .033$), probably because of the younger age distribution in the moyamoya group compared with the non-moyamoya group. There was no significant association of sex ($P = .41$), side of the operated hemisphere ($P = .49$), and past history of hemorrhage ($P = .19$) with the occurrence of symptomatic hyperperfusion (Table 3).

Because of the apparently different age distributions in the moyamoya and non-moyamoya groups (Table 1), the correlation between age and development of symptomatic cerebral hyperperfusion was examined only in the moyamoya group. Among 86 patients with moyamoya disease, patients with symptomatic hyperperfusion were relatively older (mean, 38.9 years of age) than those without symptomatic hyperperfusion (mean, 32.8 years of age), but the difference was not significant ($P = .12$). Systolic blood pressure 1 day after surgery was 131.8 mm Hg in the moyamoya group and 126.8 mm Hg in the non-moyamoya group (no statistical difference; $P = .069$).

REPRESENTATIVE CASES

Case 1: Moyamoya Disease

This 9-year-old boy, presenting with minor completed stroke in the right temporo-occipital lobe, was found to have moyamoya disease. He underwent STA-MCA anastomosis with encephalo-

duro-myo-synangiosis on the left hemisphere 4 months after revascularization surgery on the right hemisphere. The recipient artery at the M4 segment of the temporal branch of the MCA was explored, and anastomosis was performed between the stump of the STA (1.0 mm in diameter) and the M4 segment (0.8 mm in diameter) that supplied the left temporal lobe. The temporary occlusion time was 19 minutes. ¹²³I-IMP-SPECT 1 day after surgery revealed focal intense increase in CBF at the site of the anastomosis (arrows in Figure 1A). Postoperative MRI 1 day after surgery showed no evidence of ischemic change, and MRA demonstrated thick high signal intensity of the STA (arrow in Figure 1B). Two days after surgery, he suffered from fluctuating aphasia. Repeated MRI ruled out cerebral ischemia and compression of the brain surface. On the basis of the diagnosis of symptomatic cerebral hyperperfusion, his systolic blood pressure was controlled under 110 mm Hg, which improved his symptom. His aphasia resolved 5 days after surgery, and ¹²³I-IMP-SPECT 7 days after surgery showed normalization of CBF on the left hemisphere. He was discharged without neurological deficit 16 days after surgery, and there was no cerebrovascular event during the follow-up period of 3 months.

Case 2: Atherosclerotic Right MCA (M1) Occlusion

This 66-year-old woman, presenting with minor completed stroke in the right hemisphere, was proven to have severe hemodynamic compromise of the affected hemisphere. She underwent STA-MCA anastomosis on the affected hemisphere 6 months after the onset of stroke. The recipient artery at the M4 segment of the temporal branch of the MCA was explored, and anastomosis was performed between the stump of the STA (1.0 mm in diameter) and the M4 segment (1.0 mm in diameter) that supplied the temporal lobe. The temporary occlusion time was 18 minutes. ¹²³I-IMP-SPECT 1 day after surgery revealed focal increase in CBF at the site of the anastomosis (arrows in Figure 2A). Postoperative MRI 2 days after surgery showed no evidence of ischemic change, and MRA demonstrated the high signal intensity of ipsilateral STA (arrow in Figure 2B). Blood pressure was maintained in the normal range, and she did not present neurological sign perioperatively. There was no cerebrovascular event during the follow-up period of 4 months.

TABLE 3. Multivariate Analysis of Symptomatic Cerebral Hyperperfusion After Extracranial-Intracranial Bypass

Risk Factors	Symptomatic Cerebral Hyperperfusion		P
	Yes	No	
Mean age, y	38.8 ± 14.92	40.52 ± 18.68	.0330
Male sex, n (%)	6 (23.1)	52 (42.3)	.4064
Left hemisphere, n (%)	12 (46.15)	65 (52.84)	.4910
History of hemorrhage, n (%)	4 (15.38)	5 (4.07)	.1876
Moyamoya disease, n (%)	26 (100)	95 (77.2)	.0008

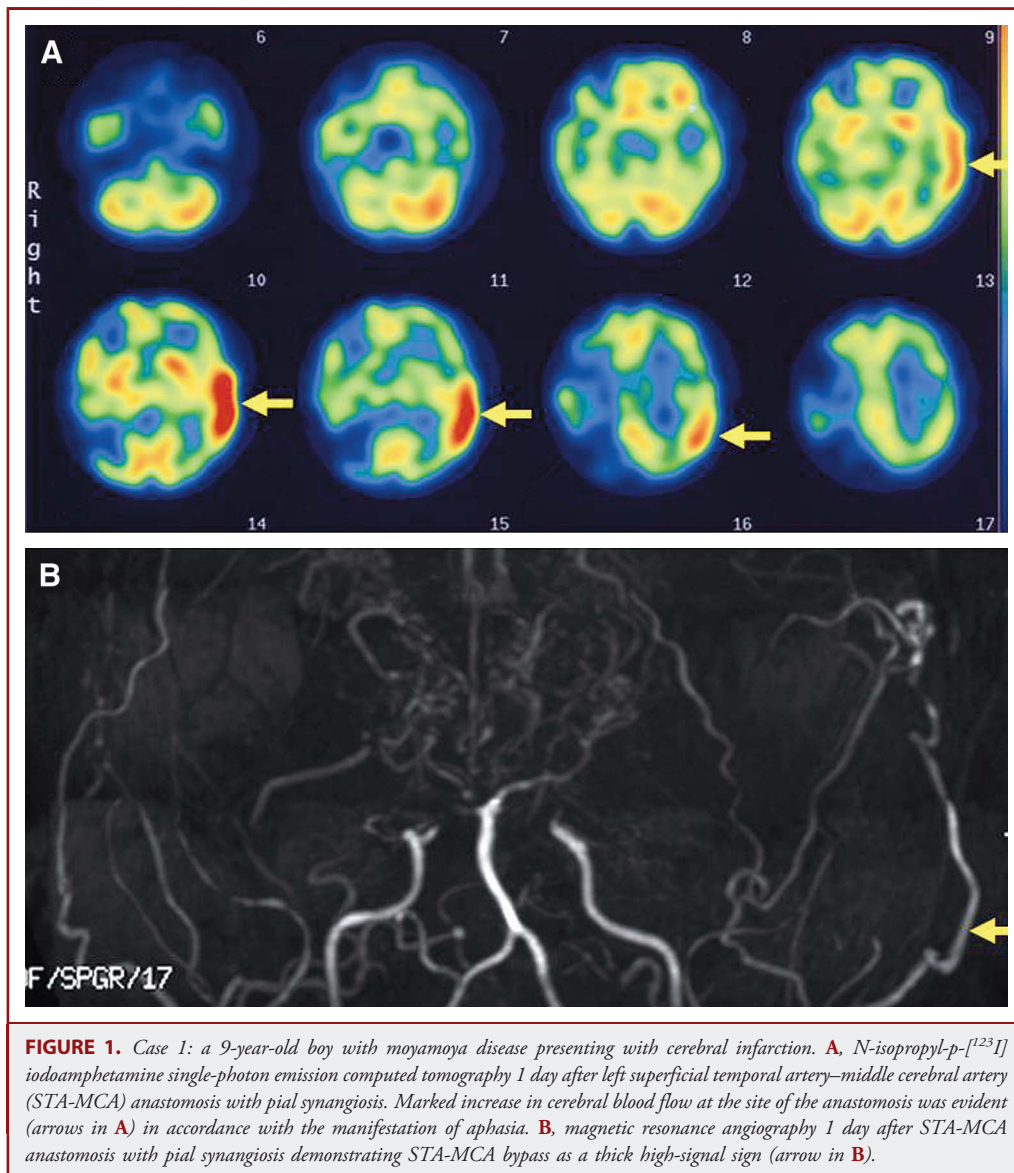


FIGURE 1. Case 1: a 9-year-old boy with moyamoya disease presenting with cerebral infarction. **A**, *N*-isopropyl-*p*-[¹²³I] iodoamphetamine single-photon emission computed tomography 1 day after left superficial temporal artery–middle cerebral artery (STA-MCA) anastomosis with pial synangiosis. Marked increase in cerebral blood flow at the site of the anastomosis was evident (arrows in **A**) in accordance with the manifestation of aphasia. **B**, magnetic resonance angiography 1 day after STA-MCA anastomosis with pial synangiosis demonstrating STA-MCA bypass as a thick high-signal sign (arrow in **B**).

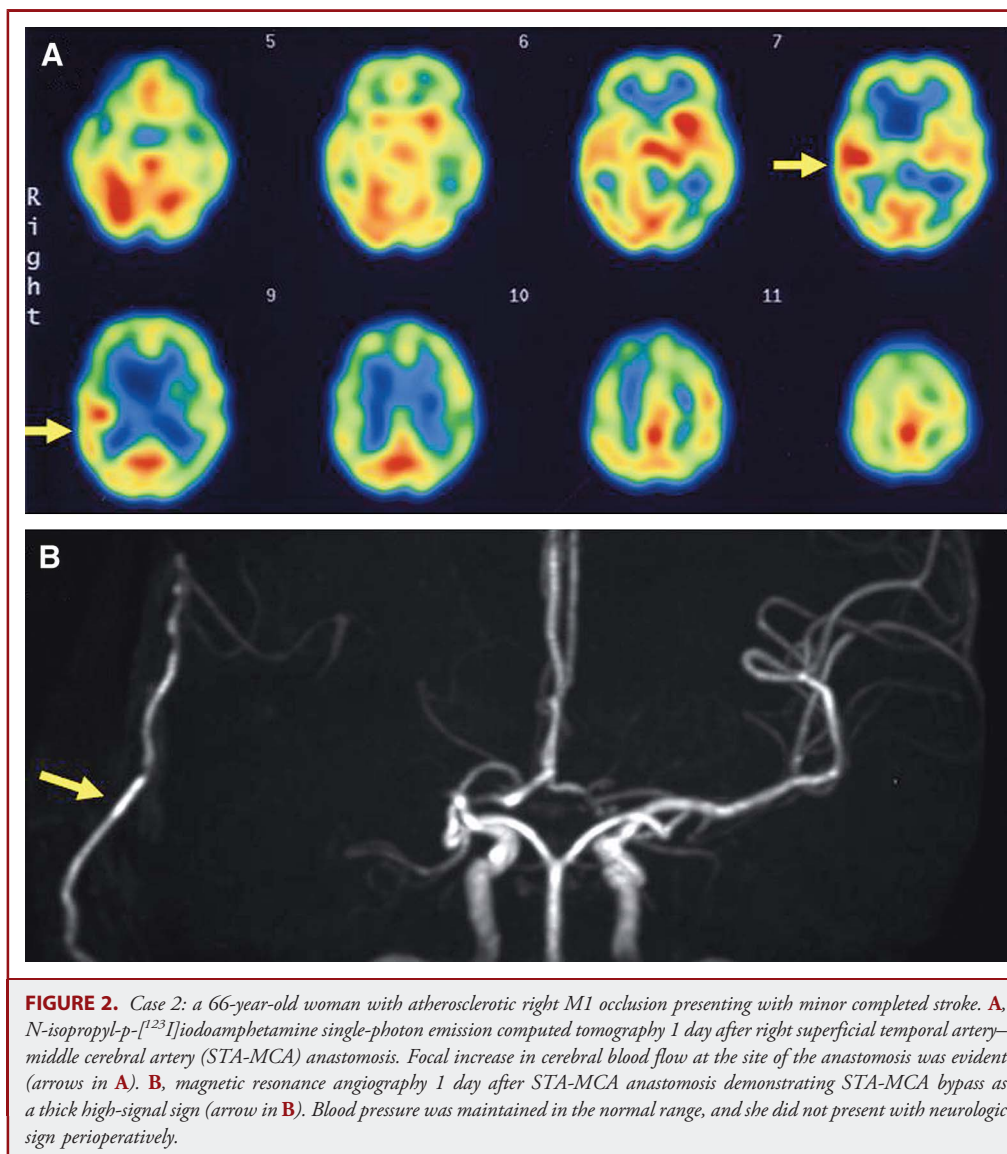
Follow-up MRA 3 months after surgery showed apparently patent STA.

DISCUSSION

In the present study, we demonstrated for the first time that patients with moyamoya disease have significantly higher risk for symptomatic hyperperfusion as a potential complication of EC-IC bypass compared with other occlusive cerebrovascular diseases treated by the same procedure. Accurate diagnosis by flow study and proper management of hyperperfusion is recommended, especially in patients with moyamoya disease, because the management of hyperperfusion is contradictory to that of cerebral ischemia.

Incidence and Clinical Manifestation of Symptomatic Cerebral Hyperperfusion After EC-IC Bypass

Symptomatic cerebral hyperperfusion after EC-IC bypass for atherosclerotic occlusive cerebrovascular disease is rare and generally manifests as mild focal neurological deficit, which resolves within 2 weeks.^{8,9} Heros et al⁸ first suggested the involvement of cerebral hyperperfusion in 5 patients with atherosclerotic ischemic disease who presented with temporary neurological deterioration after STA-MCA bypass among 134 patients (3.7%). All 5 patients had resolved symptoms within 2 weeks after surgery. Kuroda and colleagues⁹ also reported on a 64-year-old woman with atherosclerotic internal carotid artery occlusion who presented with transient aphasia caused by hyperperfusion from 2 to 7 days after STA-MCA anastomosis. Our results showed that



no patients in the non-moyamoya group (0 of 28, 0%) suffered from symptomatic cerebral hyperperfusion after STA-MCA anastomosis. Regarding high-flow bypass, Stiver and Ogilvy¹⁰ reported on a 48-year-old woman with severe right supraclinoid internal carotid artery and proximal M1 stenosis who suffered from acute hyperperfusion with massive ICH after high-flow EC-IC bypass. EC-IC bypass for atherosclerotic occlusive disease, as long as the low-flow bypass is selected, is considered to have relatively low risk for cerebral hyperperfusion, and symptoms are thought to be self-limiting in most cases.

In contrast to atherosclerotic patients, however, increasing evidence suggests that cerebral hyperperfusion is a cause of transient neurological deterioration^{12,16-22} or delayed ICH²³ during the

acute stage after EC-IC bypass for moyamoya disease. The incidence of temporary neurological deterioration probably caused by hyperperfusion is reported to be 16.7% to 28.1%^{12,18,22} when mild focal neurological signs are included. Our most recent report, the only study in which a time sequential flow study was conducted in all cases, indicated that the incidence of symptomatic cerebral hyperperfusion was as high as 24.5% (25 of 102 consecutive surgeries),¹² although the exact difference in the incidence and clinical presentation of hyperperfusion between moyamoya patients and non-moyamoya patients was unclear.

In the present study, symptomatic cerebral hyperperfusion including mild focal neurological sign was seen in 25 patients with moyamoya disease (26 hemispheres, 21.5%) but in no

patients in the non-moyamoya group (0%; $P = .0069$). All patients with symptomatic hyperperfusion were treated with intensive blood pressure control, and no patient suffered from permanent neurological deficit resulting from cerebral hyperperfusion, although 4 patients with moyamoya disease had hemorrhagic hyperperfusion (4/121, 3.3%), including 3 patients with SAH and 1 with ICH,²³ which makes us aware of the substantial risks for surgical morbidity resulting from hyperperfusion in moyamoya patients. Regarding the time course of symptomatic cerebral hyperperfusion, focal neurological sign may manifest from postoperative day 2 and could prolong for several days, whereas SAH could occur on the day after revascularization surgery.^{12,16} Intensive blood pressure control relieves symptoms caused by hyperperfusion, which may also help the diagnosis of hyperperfusion, whereas the focal neurological signs may fluctuate for a couple days before complete resolution. Thus, we recommend routine CBF measurement for patients with high risk of postoperative hyperperfusion such as moyamoya patients and patients with atherosclerotic ischemic disease associated with marked hemodynamic compromise.

We previously reported that adult-onset and/or hemorrhage-onset moyamoya patients had higher risk for symptomatic cerebral hyperperfusion.¹² In the present study, patients with symptomatic hyperperfusion were relatively older (mean, 38.9 years) than those without symptomatic hyperperfusion (mean, 32.8 years) in the moyamoya group, but we did not find a statistical difference, in contrast to our previous study. Relatively small numbers of pediatric cases in our series and our recent case with symptomatic cerebral hyperperfusion in a child (representative case 1) with marked preoperative hemodynamic compromise might have diluted the results in the present series. Nevertheless, we experienced only 2 pediatric moyamoya patients with symptomatic cerebral hyperperfusion, both presenting with mild neurological signs without hemorrhage, and we consider that accurate diagnosis of cerebral hyperperfusion is clinically important, especially for adult-onset moyamoya disease.

Underlying Mechanism of the Occurrence of Cerebral Hyperperfusion in Patients With Moyamoya Disease

The reason why moyamoya patients had higher risk for symptomatic cerebral hyperperfusion is undetermined. Because the vulnerability of the blood-brain barrier in patients subjected to chronic ischemia is thought to be one of the important factors for cerebral hyperperfusion,⁴ it is conceivable that a similar mechanism regarding blood-brain barrier maintenance, which may facilitate hemorrhage in patients with moyamoya disease, could also contribute to the occurrence of postoperative cerebral hyperperfusion. Because reactive oxygen species have been implicated in cerebral ischemia/reperfusion injury,²⁴ excessive production of reactive oxygen species during revascularization may also affect vascular permeability and thus result in transient neurological deterioration and/or hemorrhagic complications.^{24,25} Regarding the downstream molecules related to reperfusion injury, recent studies using dura mater, arachnoid

membrane, and serum obtained from the patients with moyamoya disease demonstrated that the expression of vascular endothelial growth factor²⁶ and matrix metalloproteinase-9,²⁵ both of which have a potential role to increase the permeability of the blood-brain barrier, is significantly increased in moyamoya patients compared with healthy control subjects. These observations raise the possibility that the increased expression of vascular endothelial growth factor and matrix metalloproteinase-9 in patients with moyamoya disease^{25,26} may contribute, at least in part, to the vulnerability to cerebral hyperperfusion in moyamoya patients compared with the patients in the non-moyamoya group. Our results showed that there was no difference in the incidence of any cerebral hyperperfusion (symptomatic and asymptomatic) between the moyamoya and non-moyamoya groups, whereas moyamoya patients showed much higher incidence of symptomatic hyperperfusion compared with non-moyamoya patients. These findings strongly suggest a lower threshold for symptoms in the setting of hyperperfusion in moyamoya disease rather than in the hemodynamics. The issues regarding underlying mechanism of symptomatic cerebral hyperperfusion remain to be elucidated in a future study. By delineating the deleterious cascades of cerebral hyperperfusion, prophylactic blockade of these molecules in high-risk patients may be helpful in avoiding unfavorable complications, including postoperative cerebral hyperperfusion after EC-IC bypass, which could be a new therapeutic approach in combination with revascularization surgery for moyamoya disease.

Besides the intrinsic biological background of moyamoya disease, characteristic angioarchitecture of the pial artery may explain the underlying mechanism that facilitates postoperative cerebral hyperperfusion in patients with moyamoya disease. Kim and colleagues¹⁸ speculate that poorer network formation between the pial arteries may lead to the poorer hemodynamic distribution after revascularization surgery and thus result in focal cerebral hyperperfusion after EC-IC bypass, especially in moyamoya disease. Our most recent study using a novel intraoperative infrared monitoring system on the brain surface demonstrated that the increase in the brain surface temperature around the site of the anastomosis immediately after surgical revascularization was significantly higher in patients who subsequently presented with symptomatic hyperperfusion,²⁰ suggesting that poorer distribution of the blood flow from STA may result in focal hyperemia and thus cause symptomatic cerebral hyperperfusion. Further study with a larger number of patients with moyamoya disease and with atherosclerotic ischemic disease may address this important issue.

CONCLUSION

Symptomatic cerebral hyperperfusion is a potential complication of EC-IC bypass, especially in patients with moyamoya disease. Accurate diagnosis and proper management of hyperperfusion are recommended, especially in patients with moyamoya disease.

Disclosure

The authors have no personal financial or institutional interest in any of the drugs, materials, or devices described in this article.

REFERENCES

- Piepgas DG, Morgan MK, Sundt TM Jr, Yanagihara T, Mussman LM. Intracerebral hemorrhage after carotid endarterectomy. *J Neurosurg.* 1988;68(4):532-536.
- Solomon RA, Loftus CM, Quest DO, Correll JW. Incidence and etiology of intracerebral hemorrhage following carotid endarterectomy. *J Neurosurg.* 1986;64(1):29-34.
- Sundt TM Jr, Sharbrough FW, Piepgas DG, Kearns TP, Messick JM, O'Fallon WM. Correlation of cerebral blood flow and electroencephalographic changes during carotid endarterectomy: with results of surgery and hemodynamics of cerebral ischemia. *Mayo Clin Proc.* 1981;56(9):533-543.
- van Mook R, Renneberg G, Schurink R, et al. Cerebral hyperperfusion syndrome. *Lancet Neurol.* 2005;4(12):877-888.
- Hosoda K, Kawaguchi T, Ishii K, et al. Prediction of hyperperfusion after carotid endarterectomy by brain SPECT analysis with semiquantitative statistical mapping method. *Stroke.* 2003;34(5):1187-1193.
- Komoribayashi N, Ogasawara K, Kobayashi M, et al. Cerebral hyperperfusion after carotid endarterectomy is associated with preoperative hemodynamic impairment and intraoperative cerebral ischemia. *J Cereb Blood Flow Metab.* 2005;26(7):878-884.
- Ogasawara K, Inoue T, Kobayashi M, Endo H, Fukuda T, Ogawa A. Pretreatment with the free radical scavenger edaravone prevents cerebral hyperperfusion after carotid endarterectomy. *Neurosurgery.* 2004;55(5):1060-1067.
- Heros RC, Scott RM, Ackerman RH, Conner ES. Temporary neurological deterioration after extracranial-intracranial bypass. *Neurosurgery.* 1984;15(2):178-185.
- Kuroda S, Kamiyama H, Abe H, Asaoka K, Mitsumori K. Temporary neurological deterioration caused by hyperperfusion after extracranial-intracranial bypass: case report and study of cerebral hemodynamics. *Neurol Med Chir (Tokyo).* 1994;34(1):15-19.
- Stiver SI, Ogilvy CS. Acute hyperperfusion syndrome complicating EC-IC bypass. *J Neurol Neurosurg Psychiatry.* 2002;73(1):88-89.
- Suzuki J, Takaku A. Cerebrovascular "moyamoya" disease: disease showing abnormal net-like vessels in base of brain. *Arch Neurol.* 1969;20(3):288-299.
- Fujimura M, Mugikura S, Kaneta T, Shimizu H, Tominaga T. Incidence and risk factors for symptomatic cerebral hyperperfusion after superficial temporal artery-middle cerebral artery anastomosis in patients with moyamoya disease. *Surg Neurol.* 2009;71(4):442-447.
- Guzman R, Lee M, Achrol A, et al. Clinical outcome after 450 revascularization procedures for moyamoya disease. *J Neurosurg.* 2009;111(5):927-935.
- Houkin K, Ishikawa T, Yoshimoto T, Abe H. Direct and indirect revascularization for moyamoya disease: surgical techniques and peri-operative complications. *Clin Neurol Neurosurg.* 1997;99(Suppl 2):S142-S145.
- Okada Y, Shima T, Nishida M, Yamane K, Yamada T, Yamanaka C. Effectiveness of superficial temporal artery-middle cerebral artery anastomosis in adult moyamoya disease: cerebral hemodynamics and clinical course in ischemic and hemorrhagic varieties. *Stroke.* 1998;29(3):625-630.
- Fujimura M, Kaneta T, Mugikura S, Shimizu H, Tominaga T. Temporary neurologic deterioration due to cerebral hyperperfusion after superficial temporal artery-middle cerebral artery anastomosis in patients with adult-onset moyamoya disease. *Surg Neurol.* 2007;67(3):273-282.
- Furuya K, Kawahara N, Morita A, Momose T, Aoki S, Kirino T. Focal hyperperfusion after superficial temporal artery-middle cerebral artery anastomosis in a patient with moyamoya disease: case report. *J Neurosurg.* 2004;100(1):128-132.
- Kim JE, Oh CW, Kwon OK, Park SQ, Kim SE, Kim YK. Transient hyperperfusion after superficial temporal artery/middle cerebral artery bypass surgery as a possible cause of postoperative transient neurological deterioration. *Cerebrovasc Dis.* 2008;25(6):580-586.
- Kohama M, Fujimura M, Mugikura S, Tominaga T. Temporal change of 3-T magnetic resonance imaging/angiography during symptomatic cerebral hyperperfusion following superficial temporal artery-middle cerebral artery anastomosis in a patient with adult-onset moyamoya disease. *Neurosurg Rev.* 2008;31(4):451-455.
- Nakagawa A, Fujimura M, Arafune T, Sakuma I, Tominaga T. Clinical implications of intraoperative infrared brain surface monitoring during superficial temporal artery-middle cerebral artery anastomosis in patients with moyamoya disease. *J Neurosurg.* 2009;111(6):1158-1164.
- Ogasawara K, Komoribayashi N, Kobayashi M, et al. Neural damage caused by cerebral hyperperfusion after arterial bypass surgery in a patient with moyamoya disease: case report. *Neurosurgery.* 2005;56(6):E1380.
- Ohue S, Kumon Y, Kohno K, Watanabe H, Iwata S, Ohnishi T. Postoperative temporary neurological deficits in adults with moyamoya disease. *Surg Neurol.* 2008;69(3):281-286.
- Fujimura M, Shimizu H, Mugikura S, Tominaga T. Delayed intracerebral hemorrhage after superficial temporal artery-middle cerebral artery anastomosis in a patient with moyamoya disease: possible involvement of cerebral hyperperfusion and increased vascular permeability. *Surg Neurol.* 2009;71(2):223-227.
- Chan PH. Role of oxidants in ischemic brain injury. *Stroke.* 1996;27(6):1124-1129.
- Fujimura M, Watanabe M, Narisawa A, Shimizu H, Tominaga T. Increased expression of serum matrix metalloproteinase-9 in patients with moyamoya disease. *Surg Neurol.* 2009;72(5):476-480.
- Sakamoto S, Kiura Y, Yamasaki F, et al. Expression of vascular endothelial growth factor in dura matter of patients with moyamoya disease. *Neurosurg Rev.* 2008;31(1):77-81.

COMMENTS

In this study, the authors report the differential risk for symptomatic cerebral hyperperfusion after revascularization for moyamoya disease compared with atherosclerotic disease. Whereas 21.5 % of the 121 moyamoya hemispheres suffered transient neurological symptoms attributable to focal hyperperfusion, none of the 28 patients with atherosclerosis demonstrated symptomatic hyperperfusion. Interestingly, imaging evidence of hyperperfusion was present in approximately two-thirds of patients in both groups, suggesting that the phenomenon is not uncommon but that the moyamoya group has a lower threshold for developing symptoms in this setting. Future studies to quantitatively assess the extent of hyperperfusion and correlation with intraoperative and postoperative bypass flow measurements will be important to provide further insights into this phenomenon.

Sepideh Amin-Hanjani
Chicago, Illinois

Fujimura et al present their large extracranial-intracranial arterial bypass experience and a comparison of the incidence of perioperative hyperperfusion syndrome, diagnosed by neurologic findings and abnormalities on *N*-isopropyl-p-[¹²³I]iodoamphetamine single-photon emission computed tomography, between those with moyamoya disease and those with nonmoyamoya, atherosclerotic occlusive disease. Interestingly, hyperperfusion was seen in 26 of 121 operated hemispheres for moyamoya disease and 0 of 28 hemispheres in the nonmoyamoya group. Hyperperfusion syndrome was confirmed in these patients by the presence of neurologic symptoms, absence of ischemic changes on magnetic resonance imaging, and concomitant hyperperfusion visualized in the region of the bypass on single-photon emission computed tomography imaging. In addition, subarachnoid hemorrhage and intracerebral hemorrhage were seen in a minority of patients with moyamoya disease undergoing extracranial-intracranial bypass and in none of those with atherosclerotic disease.

The authors present an elegant study that suggests a true difference in susceptibility to hyperperfusion in patients with moyamoya disease compared with those with vascular occlusive disease secondary to atherosclerotic disease. Hyperperfusion syndrome appears to be an increasingly recognized cause of neurologic deficit in the immediate postoperative period after cerebral revascularization, likely secondary to improved diagnostic imaging techniques and better understanding of this previously considered rare entity. A solid understanding of this diagnosis is particularly relevant, given that the treatment for hyperperfusion is the opposite of that for ischemia, and an unfortunate

misdiagnosis may result in symptom exacerbation by inappropriate hemodynamic alterations if ischemia is wrongly suspected. Further research is essential to establish useful management guidelines for the successful prevention of cerebral hyperperfusion after revascularization; however, we commend the authors on their efforts to further illuminate the management nuances of this challenging disease.

Kyle Fargen

J. Mocco

New York, New York



The International Podcast Series. Article abstracts translated for our international audience at www.neurosurgery-online.com

NEUROSURGERY
THE JOURNAL OF THE AMERICAN ASSOCIATION OF NEUROLOGICAL SURGEONS