

CASE REPORT

Recanalisation of the internal carotid artery via the vasa vasorum after coil occlusion

T MEGURO, MD, K MURAOKA, MD, K TERADA, MD, N HIROTSUNE, MD and S NISHINO, MD

Department of Neurological Surgery, Hiroshima City Hospital, 7-33 Motomachi, Naka-ku, Hiroshima 730-8518, Japan

ABSTRACT. Antegrade recanalisation of a completely occluded internal carotid artery (ICA) via the vasa vasorum is extremely rare. Here, we report such a case after proximal endovascular coiling in a case of dissected (*i.e.* non-atherosclerotic) ICA. A 42-year-old man presented with thromboembolic stroke of the left frontal lobe owing to pseudo-occlusion of the left ICA manifesting as motor aphasia and right hemiparesis. There were abundant floating thrombi in the petrous portion of the left ICA. Because of good collateral flow in the left middle cerebral artery territory through the anterior communicating artery and external carotid artery system, endovascular coil embolisation of the left ICA was performed for prevention of further thromboembolic stroke. The patient showed progressive recovery following endovascular treatment, and was discharged with mild right hemiparesis 1 month later. He maintained a regimen of aspirin and physical rehabilitation. At follow-up, 38 months later, the patient was asymptomatic. Angiography demonstrated occlusion of the left ICA and multiple serpiginous vessels originating from the proximal internal and external carotid arteries and which filled the ICA distal to the occlusion. This case suggests that an ICA occluded by proximal coil embolisation—even in a non-atherosclerotic case—might be recanalised via the vasa vasorum.

Received 1 December 2009

Revised 13 February 2010

Accepted 26 February 2010

DOI: 10.1259/bjr/31383692

© 2011 The British Institute of Radiology

The vasa vasorum supply the arterial blood to the adventitia and outer third of the media in large arteries, whereas diffusion across the endothelial layer supplies oxygen and other nutrients to the endothelium and inner media [1, 2]. Atherosclerotic changes cause an increase in the vasa vasorum, which form a dense vascular network within the plaque [3, 4], and vessels originating from the arterial lumen may develop and communicate with the vasa vasorum [3, 5]. However, after complete occlusion of the internal carotid artery (ICA), recanalisation via the vasa vasorum is rare, with only a few reported cases [5–12].

We describe a case of recanalisation of the ICA occluded by endovascular coiling. It seems that collateralisation via the vasa vasorum developed in the 3 year follow-up period.

Case report

A 42-year-old man was admitted to the neurology department of a local hospital on 17 August 2005. He had experienced sudden onset of weakness of the right extremities and speech disturbance. CT and MRI of the brain revealed left cerebral infarction, and antiplatelet and anticoagulation therapy (aspirin 100 mg day⁻¹ and argatroban 60 mg day⁻¹) was initiated. His neurological

symptoms improved satisfactorily but suddenly deteriorated on the third day from onset. Repeat MRI/magnetic resonance angiography (MRA) suggested an increase in cerebral infarction because of the left ICA occlusion, and he was immediately transferred to our department. On admission, his Glasgow coma scale score was 9 (E3V1M5). He had right hemiplegia and motor aphasia. Laboratory data revealed no definitive abnormality. A CT scan showed a low-density area in the left frontal lobe, so emergency cerebral angiography was performed. On the left common carotid injection, the ICA appeared occluded 3 cm distal to the carotid bifurcation (Figure 1a). The suprapetrous portion of the left ICA was canalised via the external carotid (vidian and inferolateral trunk arteries), but the petrous and cervical portions of the ICA were not seen on the early-phase image obtained within 2 s after injection. The delayed-phase image (after 2.5 s) revealed a slow stream of contrast material progressing antegrade through the ICA. Floating thrombi were seen in the petrous ICA on the late-phase image (Figure 1b). The circulation of the left hemisphere was mainly derived through collateral vessels from the anterior communicating artery and external carotid artery systems.

The patient was diagnosed as having ICA dissection, and we decided to undertake endovascular occlusion of the left ICA to prevent further thromboembolism. The left ICA was occluded with Guglielmi detachable coils (Boston Scientific/Target Therapeutics, Fremont, CA) (Figure 2). The patient was neurologically unchanged immediately

Address correspondence to: Toshinari Meguro, MD, Department of Neurological Surgery, Hiroshima City Hospital, 7-33 Motomachi, Naka-ku, Hiroshima 730-8518, Japan. E-mail: tmeguron@hotmail.com

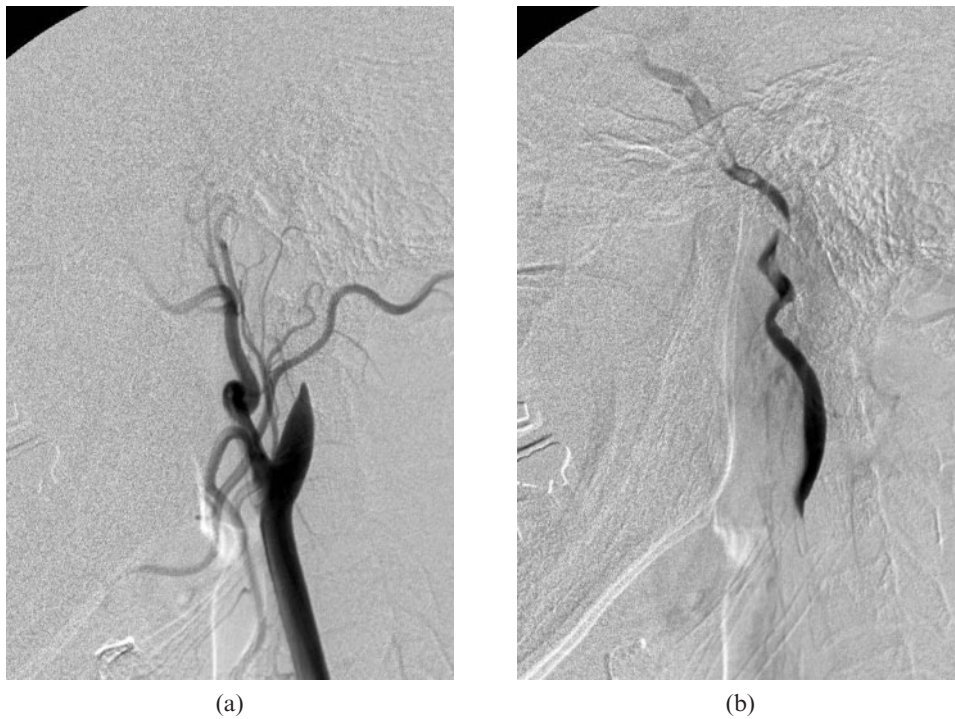


Figure 1. Left common carotid angiograms, lateral view. (a) Early-phase image shows the left internal carotid artery (ICA) occlusion 3 cm distal to the carotid bifurcation. (b) Later-phase image shows a slow stream of contrast material progressing antegrade through the ICA. Floating thrombi were seen in the petrous ICA.

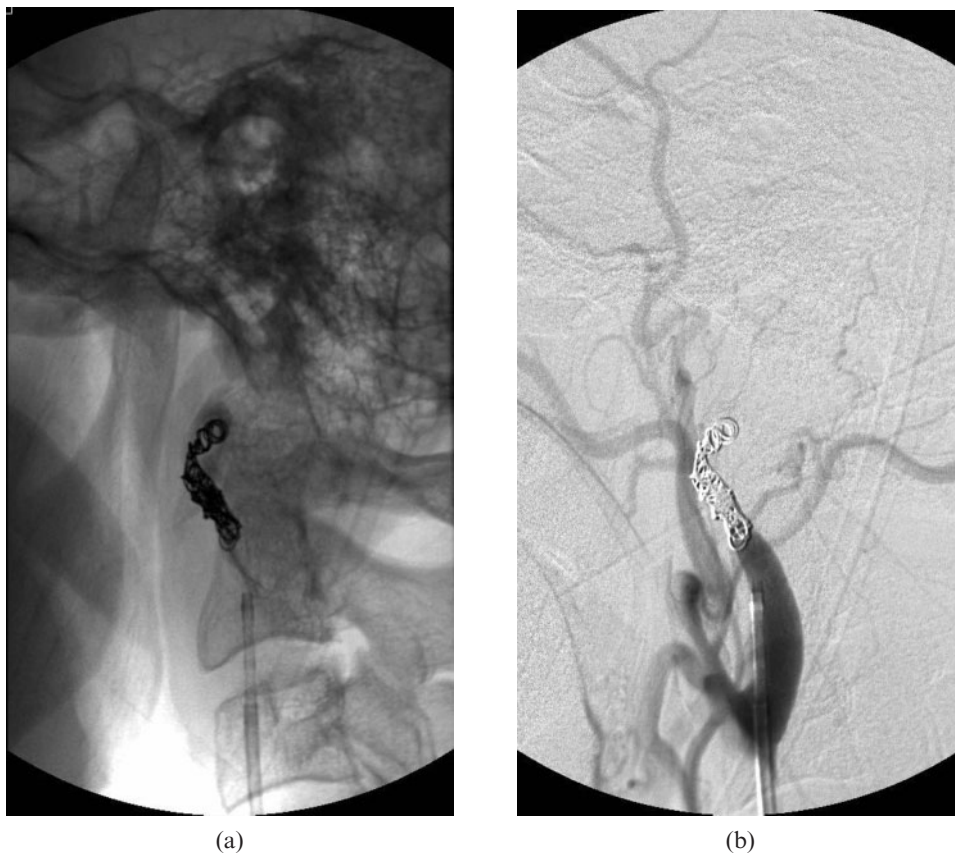


Figure 2. Left common carotid angiograms after endovascular occlusion of the internal carotid artery (ICA) with coils. (a) No subtraction. (b) The cervical ICA was completely occluded by the coil.

after the treatment but gradually improved. He underwent anticoagulant therapy (argatroban 60 mg day⁻¹) for 7 days and took aspirin (100 mg day⁻¹) from then on. He was transferred to a local rehabilitation centre 2 weeks later. His neurological symptoms gradually improved. He had mild right hemiparesis, and 3 months later his score on the modified Rankin scale was Grade 1.

A follow-up angiography was performed 38 months after treatment. The left common carotid injection demonstrated that the left ICA had recanalised with multiple small vascular channels. The multiple small vascular channels arose from the proximal left ICA and the left external carotid artery ran outside the expected lumen of the left ICA, then filled the native lumen distal to the petrous portion of the ICA (Figure 3).

Discussion

The authors suppose that the cause of ICA pseudo-occlusion in this case was ICA dissection, according to the initial angiographic findings. Spontaneous dissection of the ICA is a frequent cause of stroke in young to middle-aged patients, accounting for approximately 20% of stroke in patients <45 years of age [13]. Conservative management with anticoagulation and/or antiplatelet medications is the primary treatment for symptomatic carotid dissection. Thromboembolism, not haemodynamic infarction, is the essential stroke mechanism in ICA dissection, and ICA dissection has the potential for pseudoaneurysm formation in its dissecting part that may be causing a mass effect and thrombus formation

within the pseudosac with subsequent embolisation. Prevention of arterioarterial embolism is the main therapeutic goal in ICA dissection [14]. Because most dissections of the carotid artery heal spontaneously, surgical or endovascular treatment should be attempted if symptoms progress despite the conservative treatment [13, 15].

It has been recognised that the vasa vasorum in the cervical carotid artery originate from the external carotid artery and internal carotid artery near the carotid bifurcation [3, 5]; however, recanalisation of an occluded cervical internal carotid artery via the vasa vasorum is very rare. There have been only a few reported cases [5–12]. Among most of the reported cases, the cause of internal carotid artery occlusion was atherosclerosis. Bo et al [3] reported that the vasa vasorum are prominent in areas of marked atherosclerosis. The proliferation of vasa vasorum into atherosclerotic plaques is related to angiogenic factors in the atherosclerotic plaques and subsequent neovascularisation.

Except for the vasa vasorum that developed, the possible mechanisms of the antegrade recanalisation of the occluded ICA in our patient were neovascularisation in the embolised coil mass and thrombus, and recanalisation of the pseudolumen of the carotid dissection. These mechanisms might be partially involved in this case. However, the most characteristic angiographic finding of recanalised vessels via the vasa vasorum is the location of vascular channels outside the expected carotid artery lumen that provide collateral flow from the proximal external and internal carotid arteries to the

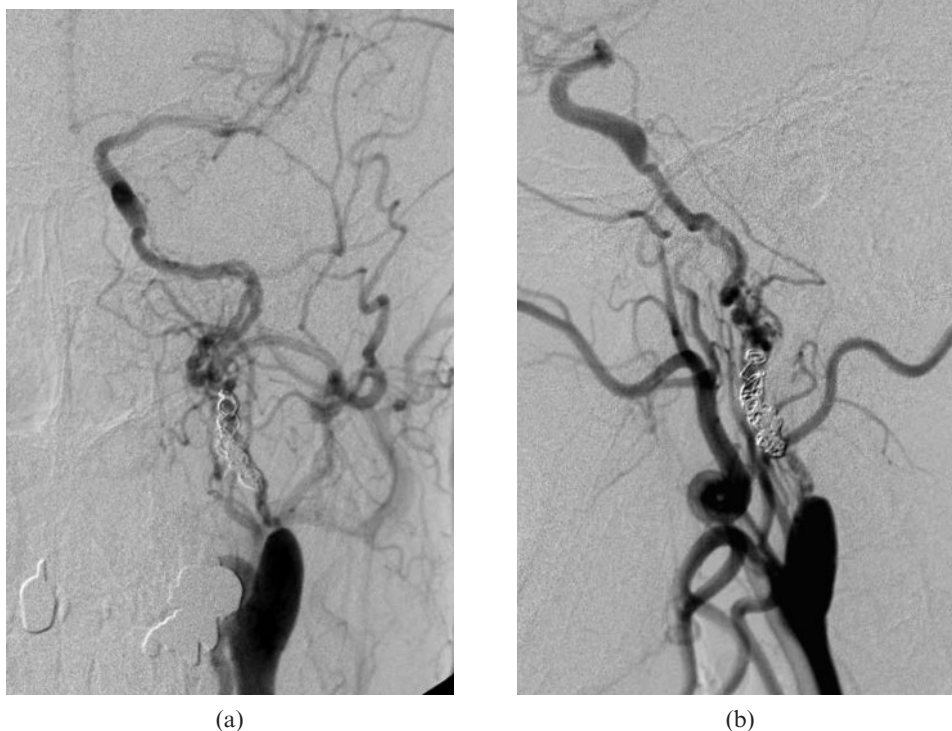


Figure 3. Left common carotid angiograms 38 months after treatment. Frontal (a) and lateral (b) views. Multiple small vascular channels arising from the proximal internal carotid artery (ICA) and the external carotid artery project over the expected course of the ICA with antegrade filling of the distal ICA.

more distal cervical carotid artery beyond the occlusion site. In the present case, angiography confirmed these findings.

We present the first case of antegrade recanalisation via the vasa vasorum of an ICA completely occluded by endovascular coiling. Only one case of recanalisation via the vasa vasorum after proximal embolisation of the ICA has been reported [6]. Numagami et al [6] occluded the ICA with a detachable balloon for treatment of a giant intracavernous aneurysm; however, the ICA was found to be recanalised via the vasa vasorum at the follow-up 6 months after treatment. They hypothesised that recanalisation of the ICA via the vasa vasorum was induced by marginal cerebral blood flow in the ipsilateral hemisphere. We could not determine a relationship between the development of the vasa vasorum and cerebral blood flow in the ipsilateral hemisphere, because a detailed quantitative analysis of cerebral blood flow was not performed in the presented case.

In conclusion, although antegrade recanalisation via the vasa vasorum after parent artery occlusion by endovascular coiling is very rare, it is important to recognise this phenomenon and it is necessary to check for it in the imaging follow-up of the parent vessel.

References

1. Werber AH, Heistad DD. Diffusional support of arteries. *Am J Physiol* 1985;248:H901-6.
2. Williams JK, Orgren KI, Armstrong ML, Heistad DD. Vasa vasorum in the carotid sinus of atherosclerotic monkeys: implications for baroreceptor function. *Atherosclerosis* 1989;78:25-32.
3. Bo WJ, McKinney WM, Bowden RL. The origin and distribution of vasa vasorum at the bifurcation of the common carotid artery with atherosclerosis. *Stroke* 1989;20:1484-7.
4. Yoshida K, Inoue K, Chin M, Narumi O, Yamagata S. Occlusive thrombosis with neovascularization of the internal carotid artery: two case reports. *Neurol Med Chir (Tokyo)* 2008;48:447-50.
5. Shimizu H, Tominaga T, Ezura M, Yoshimoto T. Bypass surgery for occluded internal carotid artery revascularized by vasa vasorum: case report. *Neurol Med Chir (Tokyo)* 2002;42:57-61.
6. Numagami Y, Ezura M, Takahashi A, Yoshimoto T. Antegrade recanalization of completely embolized internal carotid artery after treatment of a giant intracavernous aneurysm: a case report. *Surg Neurol* 1999;52:611-16.
7. Bradac G, Oberson R. *Angiography in cerebro-arterial occlusive disease*. New York: Springer-Verlag, 1979: 69.
8. Colon GP, Deveikis JP, Dickinson LD. Revascularization of occluded internal carotid arteries by hypertrophied vasa vasorum: report of four cases. *Neurosurgery* 1999;45:634-7.
9. Kasner SE, Liebeskind DS, Cucchiara BL, McGarvey ML, Detre JA, Sinson G, et al. Internal carotid artery "spring sign". *Neurology* 2002;58:1099.
10. Kemeny V, Droste DW, Nabavi DG, Schulte-Altedorneburg G, Schuierer G, Ringelstein EB. Collateralization of an occluded internal carotid artery via a vas vasorum. *Stroke* 1998;29:521-3.
11. Martin MA, Marotta TR. Vasa vasorum: another cause of the carotid string sign. *AJNR Am J Neuroradiol* 1999;20:259-62.
12. Newton T, Potts D. *Angiography in radiology of the skull and the brain*. St. Louis: Mosby, 1974: 1214-15.
13. Kadkhodayan Y, Jeck DT, Moran CJ, Derdeyn CP, Cross DT, 3rd. Angioplasty and stenting in carotid dissection with or without associated pseudoaneurysm. *AJNR Am J Neuroradiol* 2005;26:2328-35.
14. Benninger DH, Georgiadis D, Kremer C, Studer A, Nedeltchev K, Baumgartner RW. Mechanism of ischemic infarct in spontaneous carotid dissection. *Stroke* 2004;35:482-5.
15. Schievink WI, Piepgras DG, McCaffrey TV, Mokri B. Surgical treatment of extracranial internal carotid artery dissecting aneurysms. *Neurosurgery* 1994;35:809-15; discussion 815-16.