

Efficacy of Motor Cortex Stimulation for Intractable Central Neuropathic Pain: Comparison of Stimulation Parameters Between Post-stroke Pain and Other Central Pain

Takafumi TANEI,^{1,2} Yasukazu KAJITA,² Hiroshi NODA,³
Shigenori TAKEBAYASHI,¹ Daisuke NAKATSUBO,⁴
Satoshi MAESAWA,² and Toshihiko WAKABAYASHI²

¹Department of Neurosurgery, Nagoya Central Hospital, Nagoya, Aichi;

²Department of Neurosurgery, Nagoya University Graduate School of Medicine, Nagoya, Aichi;

³Department of Neurosurgery, Kasugai Municipal Hospital, Kasugai, Aichi;

⁴Department of Neurosurgery, National Hospital for Geriatric Medicine, Ohbu, Aichi

Abstract

Motor cortex stimulation (MCS) has now become the preferred option for neurosurgical management of intractable central neuropathic pain such as post-stroke pain and trigeminal neuropathic pain. However, the efficacy of MCS for other central neuropathic pain such as pain resulting from spinal cord or brainstem lesions is unclear. We retrospectively reviewed 11 consecutive patients with intractable central neuropathic pain who underwent MCS in our institution. Eight patients had poststroke pain caused by thalamic hemorrhage (n = 5) or infarction (n = 3) (thalamic group). Two patients had postoperative neuropathic pain caused by spinal cord lesions, and one patient had facial pain caused by a brainstem lesion associated with multiple sclerosis (brainstem-spinal group). Visual analog scale and stimulation parameters were evaluated at 1 and 6 months postoperatively. MCS was effective for six of eight patients in the thalamic group, and all three patients in the brainstem-spinal group. These efficacies continued for 6 months after surgery without significant change in the stimulation parameters compared with the parameters at 1 month in both groups. The mean amplitude at 1 month and frequency at 6 months after surgery were significantly higher in the brainstem-spinal group than the thalamic group, although the patient number was small. MCS is effective for other central neuropathic pain, but higher intensity stimulation parameters may be necessary to gain adequate pain reduction.

Key words: motor cortex stimulation, central neuropathic pain, spinal cord, deep brain stimulation, stimulation parameter

Introduction

Intractable neuropathic pain such as central post-stroke pain (CPSP) is the most difficult type of pain to control with medical treatment. Central neuropathic pain is defined as pain caused by neural injury in the brain or spinal cord. Various surgical methods for pain management have been tried over the years, but motor cortex stimulation (MCS) has now become the preferred option in the neurosurgical management of intractable central neuropathic pain.^{2,7,15,21,25,26} Most patients suffering from intract-

able pain caused by spinal cord lesions have undergone surgical interventions to manage the pain, such as spinal cord stimulation (SCS) and cordotomy.^{13,24} Therefore, few reports have described the efficacy of MCS for targeting neuropathic central pain caused by spinal cord lesion.^{22,23}

This study evaluated the efficacy of MCS for CPSP and other central pain caused by spinal cord or brainstem lesion, and compared stimulation parameters between CPSP and central pain from other sources.

Materials and Methods

We retrospectively reviewed 11 consecutive patients

with intractable neuropathic pain who underwent MCS electrode array implantation at Nagoya University Hospital from August 1999 to February 2009. The selection criterion for MCS was clinically diagnosed central neuropathic pain. Eight patients (5 males and 3 females) had post-stroke pain caused by thalamic hemorrhage (5 patients) or infarction (3 patients) (thalamic group). All patients presented with incomplete hemialgia contralateral to the side of the thalamic lesion. The main pain site was the upper extremity. Four of the eight patients also had pain in the face. Two patients (1 male and 1 female) had postoperative neuropathic pain in the upper extremity and body caused by spinal cord lesions (Chiari malformation type I or spinal tumor). One male had intractable facial pain caused by a brainstem lesion associated with multiple sclerosis (MS). These three patients were defined as suffering from neuropathic pain caused by other central lesions (brainstem-spinal group). All patients gave written informed consent before implantation of the stimulation system according to the standards of our institutional review board. In the thalamic group, the age at surgery was 59.4 ± 6.9 years (mean \pm standard deviation [SD]). The length of time from pain onset to surgery was 4.3 ± 2.9 years. In the brainstem-spinal group, the age at surgery was 36.3 ± 7.6 years, which was significantly younger than that of the thalamic group ($p < 0.05$). The length of time from pain onset was 3.7 ± 1.7 years, which was not significantly different with the thalamic group. The patients had been treated with various medications including anticonvulsant and/or antidepressant drugs before receiving MCS.

The location of the precentral gyrus was estimated from bone landmarks using conventional methods, and preoperative magnetic resonance (MR) images were taken after placement of fiducial markers. After the preliminary target was oriented using a neuronavigation workstation with the MR imaging data, a skin incision and a burr hole around the central sulcus were made under local anesthesia. The electrode array was inserted from the edge of the burr hole into the epidural space, and the locations of the precentral and postcentral gyri were confirmed from phase reversal of the N20 wave of the somatosensory evoked potential recorded from the electrode with median nerve stimulation. A four-plate electrode array was inserted at the target of the pain site on the precentral gyrus, then muscle contraction of the pain area was confirmed by bipolar stimulation via the electrode array. After implantation of the electrode array, a 1-week period of stimulation testing was performed. The stimulation system was implanted if more than 50% pain relief on

the visual analog scale (VAS) was obtained during the test stimulation period (Itrel III; Medtronic Inc., Minneapolis, Minnesota, USA). After implantation of the neurostimulator, stimulation parameters were adjusted to the setting ranges defined by the individual stimulation data. The ranges of the parameters were amplitude, 0–10 V; pulse width, 60–330 μ sec; and frequency, 30–130 Hz. Stimulation was usually performed for 1 hour, then turned off for 2 hours.

Clinical evaluation was based on the VAS according to the pain reduction elicited by the MCS. Stimulation parameters were also evaluated based on amplitude (V), pulse width (μ sec), and frequency (Hz). The effects of stimulation were classified into four categories, as follows: excellent, reduction of the pain level by 80% to 100%; good, reduction of the pain level by 60% to 79%; fair, reduction of the pain level by 40% to 59%; and poor, reduction of the pain level by less than 40%. Evaluations were performed at 1 and 6 months postoperatively. Pain control was considered to be satisfactory when the patient reported greater than 60% reduction in pain.

All values were expressed as means \pm SD. Duration of pain, patient age, and the stimulation parameters were compared between the thalamic and brainstem-spinal groups at 1 month and 6 months after surgery using the paired t-test. Stimulation parameters in the same groups were compared between 1 month and 6 months using the paired t-test. Probability values of less than 0.05 were considered to be significant.

Results

Our analysis revealed satisfactory pain reduction in six of eight patients in the thalamic group and three of three patients in the brainstem-spinal group (Tables 1 and 2). The pain reduction continued for 6 months after the surgery. One patient in the thalam-

Table 1 Patients treated with motor cortex stimulation for post stroke pain (thalamic group)

Case No.	Age (years), Sex	Cause	Location of pain	Result
1	59, M	ICH	lt hemibody, face	excellent
2	70, M	ICH	rt hemibody	good
3	52, M	infarction	rt hemibody	excellent
4	61, F	ICH	rt hemibody, face	good
5	57, F	ICH	lt hemibody, face	good
6	58, M	infarction	lt hemibody	poor
7	56, F	infarction	lt hemibody	good
8	55, M	ICH	rt hemibody, face	poor (seizure)

F: female, ICH: intracerebral hemorrhage, lt: left, M: male, rt: right.

Table 2 Patients treated with motor cortex stimulation for other central pain (brainstem-spinal group)

Case No.	Age (years), Sex	Location of lesion	Cause	Location of pain	Result
9	45, F	spinal cord	spinal tumor	bil upper limbs, body	good
10	31, M	spinal cord	Chiari malformation	rt upper limb, body	good
11	33, M	brainstem	multiple sclerosis	lt face	good

bil: bilateral, F: female, lt: left, M: male, rt: right.

Table 3 Intensity of stimulation parameters of motor cortex stimulation (MCS) and deep brain stimulation (DBS) in Case 9

		MCS			MCS+rt DBS			MCS+bil DBS		
		Amplitude (V)	Pulse width (μ sec)	Frequency (Hz)	Amplitude (V)	Pulse width (μ sec)	Frequency (Hz)	Amplitude (V)	Pulse width (μ sec)	Frequency (Hz)
MCS	rt	6.2 \pm 1.0	345 \pm 87	81 \pm 31	2.0 \pm 1.5	441 \pm 15	121 \pm 23	3.5 \pm 1.6	90 \pm 0	113 \pm 15
	lt	5.8 \pm 1.1	350 \pm 87	80 \pm 31	9.7 \pm 1.7	434 \pm 34	121 \pm 23	4.0 \pm 1.5	180 \pm 0	113 \pm 15
DBS	rt	—	—	—	4.5 \pm 1.0	429 \pm 23	114 \pm 24	4.6 \pm 0.1	270 \pm 0	130 \pm 0
	lt	—	—	—	—	—	—	4.4 \pm 1.0	240 \pm 0	130 \pm 0

bil: bilateral, lt: left, rt: right.

ic group experienced seizures during test stimulation, and another patient in the thalamic group did not experience reduction of pain during the test stimulation period. In these two patients, the epidural electrode was removed and the stimulation system was not implanted. No hardware-related problems and no intracranial hemorrhage complications occurred.

The mean stimulation parameters at 1 month after surgery in the thalamic and brainstem-spinal groups were amplitude 3.46 \pm 2.6 and 7.8 \pm 2.9 V, pulse width 265 \pm 195 and 338 \pm 130 μ sec, and frequency 61.7 \pm 30.8 and 96.3 \pm 34.5 Hz, respectively. The average amplitude in the brainstem-spinal group was significantly higher than that in the thalamic group ($p < 0.05$). There were no significant differences in the other stimulation parameters between the two groups. All stimulation parameters 6 months after surgery were unchanged compared to the parameters 1 month after surgery in both groups. The average stimulation parameters at 6 months after surgery in the thalamic and brainstem-spinal groups were amplitude 3.04 \pm 2.9 and 6.68 \pm 2.6 V, pulse width 180 \pm 101 and 308 \pm 102 μ sec, and frequency 55 \pm 31.9 and 106 \pm 18.9 Hz, respectively. The mean frequency in the brainstem-spinal group was significantly higher than that in the thalamic group ($p < 0.05$). No other stimulation parameters differed significantly between the two groups.

Two patients with neuropathic pain caused by postoperative spinal lesions required higher amplitude stimulation parameters for adequate reduction

of pain, so implantable pulse generator (IPG) replacements were necessary. These two patients hoped for more pain reduction, so received stereotactically implanted sensory thalamic deep brain stimulation (DBS) electrodes in the area where stimulation induced paresthesia in the area of pain. The combination of MCS and DBS achieved more pain reduction than only MCS.

Illustrative Cases

Case 9: A 45-year-old female was referred to our department for treatment of back and intractable pain of the bilateral upper extremities. She had undergone surgery for removal of a thoracic spinal tumor at 9 years of age in another hospital. This operation left her with paraplegia. She presented with backache and pain in the bilateral upper extremities in the fourth decade. The pain had gradually deteriorated. At first, we attempted a SCS procedure, but were unable to cannulate an electrode in the spinal epidural space because of closing up caused by the previous operation. Right MCS was performed in October 2005, and achieved more than 60% pain reduction on the left side of the body. One year after the right MCS procedure, left MCS was performed. More than 70% pain reduction was achieved on the right side of the body, but stimulation parameters ranging in amplitude from 5–10 V, pulse width 100–300 μ sec, and frequency 100–150 Hz were necessary for adequate reduction of pain (Table 3). These high-amplitude stimulation

parameters exhausted the IPG after a short period of time, and exchange was necessary approximately every 6 months. The patient was implanted with a DBS electrode in the right ventrocaudal (Vc) nucleus of the thalamus in October 2007. Combined DBS and MCS achieved more than 90% pain reduction. One year after the right hemisphere DBS implantation surgery, DBS electrode implantation was performed in the left Vc nucleus of the thalamus and adequate pain reduction was achieved (Fig. 1). Combined bilateral continuous stimulation allowed reduction of the amplitudes of the bilateral MCS from 5–10 to 2–4 V (Table 3).

Case 10: A 31-year-old male was referred to our department for treatment of intractable back and right upper limb pain. He presented with pain and Chiari type I malformation with syringomyelia was diagnosed at another hospital. He underwent surgery for foramen magnum decompression in December 2002. The pain was not improved after the operation, but gradually deteriorated. Left MCS was performed in September 2003 and achieved more than 70% pain reduction. High-power stimulation parameters were necessary to achieve pain reduction, so IPG exchange was frequently necessary (Table 4). The patient was implanted with a DBS electrode in the left Vc nucleus of the thalamus in

October 2004 (Fig. 2). Simple Vc-DBS achieved satisfactory pain reduction. Therefore, temporary MCS was used only when his pain was not controlled by DBS, which decreased the consumption of the IPG. Combined continuous DBS and temporary MCS achieved more pain reduction than only DBS.

Discussion

MCS for the treatment of neuropathic pain can provide pain relief in 50–75% of patients, with pain reduction of 50% or more.^{21,26)} MCS was performed primarily on patients with CPSP and trigeminal neuropathic pain.²²⁾ In the present study, six of eight patients responded favorably to MCS for CPSP, lending further support to the conclusions of prior studies. The effects of MCS for central neuropathic pain caused by spinal cord injury (SCI) or brainstem lesion are still unclear. MCS resulted in positive outcomes for 7 of 8 patients suffering neuropathic pain caused by SCI, and 9 of 14 patients suffering from other types of central neuropathic pain.²²⁾ Seven SCI patients benefited from MCS and four of these patients showed long-term improvements, suggesting that MCS therapy for neuropathic pain in SCI patients may have greater potential for long-term efficacy than DBS.¹⁸⁾ In our study, MCS provided good

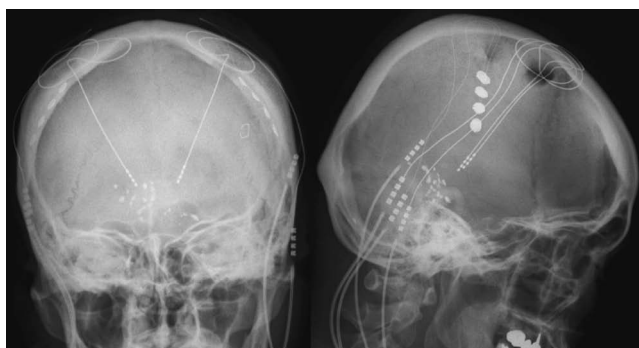


Fig. 1 Case 9. Radiographs showing placement of the electrode arrays in the bilateral precentral gyri and deep brain-stimulating electrodes in the bilateral ventrocaudal nuclei of the thalamus.

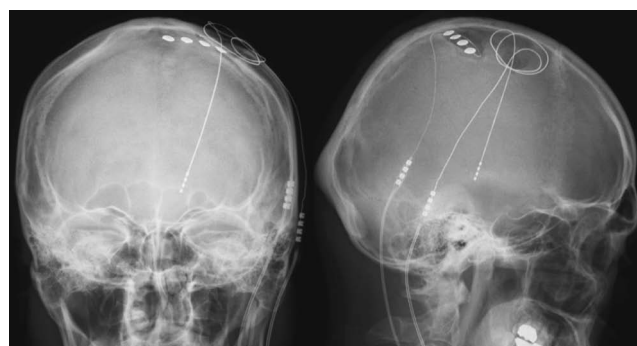


Fig. 2 Case 10. Radiographs showing placement of the electrode array in the left precentral gyrus and the deep brain-stimulating electrode in the left ventrocaudal nucleus of the thalamus.

Table 4 Intensity of stimulation parameters of motor cortex stimulation (MCS) and deep brain stimulation (DBS) in Case 10

	MCS			DBS + temporary MCS		
	Amplitude (V)	Pulse width (μ sec)	Frequency (Hz)	Amplitude (V)	Pulse width (μ sec)	Frequency (Hz)
MCS	10.5 \pm 0	450 \pm 0	62.5 \pm 46	10.2 \pm 1.3	407 \pm 120	98 \pm 12
DBS	—	—	—	3.6 \pm 1.1	167 \pm 126	74 \pm 30

pain relief in two cases of central neuropathic pain caused by postoperative spinal lesions and one case of brainstem lesion caused by MS, although higher intensity stimulation parameters were necessary than in the thalamic group. The young ages of these three patients were one of the factors of the high efficacy of MCS in the brainstem-spinal group (Table 2).

The stimulation frequencies used for MCS have ranged from 25 to 60 Hz (up to 110 Hz).^{1,2)} Amplitude ranged from 1 to 4 V (up to 10 V), and pulse width ranged from 60 to 200 μ sec (up to 450 μ sec). In our thalamic group, the average stimulation parameters at 1 and 6 months after surgery were consistent with previous reports. In contrast, the brainstem-spinal group required higher intensities for all stimulation parameters compared to the thalamic group, although the patient number was small. In general, higher intensity stimulation parameters may be required for adequate pain reduction, because of brain atrophy, pain in the lower limbs, or placement of the lead distant to the target of the pain site in the motor cortex. Our brainstem-spinal group consisted of patients with pain caused by spinal tumor, malformation, and degenerative diseases. Patients in the brainstem-spinal group were younger compared to patients in the thalamic group, so brain atrophy in the brainstem-spinal group was moderate compared to the thalamic group. Pain in the lower limbs was more difficult to treat because of difficulties localizing the epidural electrode array on the representation of the lower limb in the motor cortex, which is located in the most medial part of the cerebral hemisphere.²⁰⁾ The locations of pain in the brainstem-spinal group were the upper limbs, body, and face (Table 2), so the representations of the pain locations were more easily localized in the cortex and did not require high-intensity stimulation parameters. All our patients underwent treatment by the same surgical team using the same procedures. The location of the electrode array was confirmed by muscle contraction of the pain area using bipolar stimulation intraoperatively. Furthermore, MCS provided adequate pain relief for 6 months without significant changes to the intensity of the stimulation parameters for all three patients in the brainstem-spinal group. Therefore, the electrode array was precisely stimulating the area of the precentral gyrus corresponding to the target of the pain site. Higher intensity stimulation parameters may be necessary for MCS for central neuropathic pain caused by spinal cord or brainstem lesions to gain adequate pain reduction, although exact comparison should use the actual current values. Further studies might be necessary to evaluate the relationship of in-

tensity stimulation parameters of MCS and location of the lesions.

Several mechanisms of MCS have been reported, but remain poorly understood. MCS may activate non-nociceptive neurons and inhibit hyperactive nociceptive neurons.²⁶⁾ In recent years, advances in functional imaging have allowed investigation of neuronal activity. Several studies have indicated that MCS increases cerebral blood flow within the thalamus, brainstem, anterior cingulate cortex, insula, and orbitofrontal cortex.^{4,9,16)} MCS is thought to modulate the pathways for pain perception and pain-related emotional pathways, and these modulations result in reductions in neuropathic pain. MCS also induces release of endogenous opioid in part of the medial pain system.¹²⁾ However, the proposed mechanisms of MCS cannot explain why other central neuropathic pain requires higher intensity MCS parameters than CPSP. Several studies reported that the thalamus is a key structure in the mediation of the functional effects of MCS.^{3,5,17)} The neurons in the somatosensory thalamus of patients with neuropathic pain following SCI demonstrated increased bursting activity, and these bursts occurred at higher firing rates than movement disorder patients.^{10,11)} Lesions in the spinothalamic tract, which is below the level of the thalamus, lead to degeneration of these terminals and the abnormal bursting activity is the result of deafferentation of thalamic neurons deprived of their normal input.¹⁹⁾ Irregular burst discharges were found in the posterolateral thalamus in patients with CPSP, and regional cerebral glucose metabolism decreased in the thalamus and cortical postcentral area, but increased in the cortical precentral area, suggesting that changes in cortical activity adjacent to the central sulcus might be related to the genesis of thalamic pain.⁶⁾ Differences in abnormal activities in the thalamic neurons and changes in cortical and thalamic activity may be one reason for the necessity of higher intensity stimulation parameters for MCS in the brainstem-spinal group.

In our study, the two patients with central neuropathic pain caused by postoperative spinal cord lesions were most successfully treated with a combination of DBS and MCS, which achieved more pain relief than either only MCS or DBS. The amplitude of the MCS stimulation parameters could also be decreased by combining the two methods in one patient (Table 3). Temporary MCS was used only when the pain was not controlled by DBS on the other patient (Table 4). Therefore, the combined stimulation method achieved not only pain reduction, but also decreased risk of seizure and consumption of the IPG. Various studies have described DBS

for the treatment of intractable neuropathic pain.^{2,8,14,27} DBS provided neuropathic pain relief in 18 of 36 SCI patients, although the rates of complications with DBS were higher than for MCS.¹⁸ The rate of serious permanent complications of DBS is reported to be 1% to 2%, and that of transient complications to be 15% to 25%.²⁷ Therefore, DBS is now considered with more caution and is only a viable alternative therapy if less invasive procedures have failed.¹⁹ The present study suggests that combination therapy may provide an additional therapeutic alternative for patients who do not gain satisfactory pain relief from only MCS. In our opinion, of the surgical treatment strategies for intractable central neuropathic pain caused by spinal cord or brainstem lesions, MCS is the first choice for pains in the upper limbs, body, and face, and if MCS does not achieve adequate pain reduction, additional DBS is recommended. Additional DBS can provide various intervention choices such as only MCS, only DBS, and combined MCS-DBS.

The present study found that MCS was an effective treatment for central neuropathic pain caused by CPSP, but also for pain resulting from other central lesions such as spinal cord and brainstem lesions. However, higher intensity stimulation parameters for MCS may be necessary to gain adequate pain reduction with other types of central lesions. The combination of MCS and DBS may provide an additional alternative treatment for such central neuropathic pain if MCS fails to achieve adequate pain reduction. Further research will be required to evaluate the relationships between intensity of stimulation parameters and causes of pain.

References

- 1) Brown JA, Barbaro NM: Motor cortex stimulation for central and neuropathic pain: current status. *Pain* 104: 431-435, 2003
- 2) Canavero S, Bonicalzi V: Therapeutic extradural cortical stimulation for central and neuropathic pain: a review. *Clin J Pain* 18: 48-55, 2002
- 3) Garcia-Larrea L, Peyron R, Mertens P, Gregoire MC, Lavenne F, Bonnefoi F, Mauguiere F, Laurent B, Sindou M: Positron emission tomography during motor cortex stimulation for pain control. *Stereotact Funct Neurosurg* 68: 141-148, 1997
- 4) Garcia-Larrea L, Peyron R, Mertens P, Gregoire MC, Lavenne F, Le Bars D, Convers P, Mauguiere F, Sindou M, Laurent B: Electrical stimulation of motor cortex for pain control: a combined PET-scan and electrophysiological study. *Pain* 83: 259-273, 1999
- 5) Garcia-Larrea L, Peyron R, Mertens P, Laurent B, Mauguiere F, Sindou M: Functional imaging and neurophysiological assessment of spinal and brain therapeutic modulation in humans. *Arch Med Res* 31: 248-257, 2000
- 6) Hirato M, Watanabe K, Takahashi A, Hayase N, Horikoshi S, Shibasaki T, Ohye C: Pathophysiology of central (thalamic) pain: combined change of sensory thalamus with cerebral cortex around central sulcus. *Stereotact Funct Neurosurg* 62: 300-303, 1994
- 7) Katayama Y, Fukaya C, Yamamoto T: Poststroke pain control by chronic motor cortex stimulation: neurological characteristics predicting a favorable response. *J Neurosurg* 89: 585-591, 1998
- 8) Katayama Y, Yamamoto T, Kobayashi K, Kasai M, Oshima H, Fukaya C: Motor cortex stimulation for phantom limb pain: comprehensive therapy with spinal cord and thalamic stimulation. *Stereotact Funct Neurosurg* 77: 159-162, 2001
- 9) Kishima H, Saitoh Y, Osaki Y, Nishimura H, Kato A, Hatazawa J, Yoshimine T: Motor cortex stimulation in patients with deafferentation pain: activation of the posterior insula and thalamus. *J Neurosurg* 107: 43-48, 2007
- 10) Lenz FA, Kwan HC, Dostrovsky JO, Tasker RR: Characteristics of the bursting pattern of action potentials that occurs in the thalamus of patients with central pain. *Brain Res* 496: 357-360, 1989
- 11) Lenz FA, Tasker RR, Dostrovsky JO, Kwan HC, Gorecki J, Hirayama T, Murphy JT: Abnormal single-unit activity recorded in the somatosensory thalamus of a quadriplegic patient with central pain. *Pain* 31: 225-236, 1987
- 12) Maarrawi J, Peyron R, Mertens P, Costes N, Magnin M, Sindou M, Laurent B, Garcia-Larrea L: Motor cortex stimulation for pain control induces changes in the endogenous opioid system. *Neurology* 69: 827-834, 2007
- 13) Meyerson BA: Neurosurgical approaches to pain treatment. *Acta Anaesthesiol Scand* 45: 1108-1113, 2001
- 14) Nandi D, Aziz TZ: Deep brain stimulation in the management of neuropathic pain and multiple sclerosis tremor. *J Clin Neurophysiol* 21: 31-39, 2004
- 15) Nguyen JP, Lefaucher JP, Le Guerinel C, Eizenbaum JF, Nakano N, Carpentier A, Brugieres P, Pollin B, Rostaing S, Keravel Y: Motor cortex stimulation in the treatment of central and neuropathic pain. *Arch Med Res* 31: 263-265, 2000
- 16) Peyron R, Frot M, Schneider F, Garcia-Larrea L, Mertens P, Barral FG, Sindou M, Laurent B, Mauguiere F: Role of operculoinsular cortices in human pain processing: converging evidence from PET, fMRI, dipole modeling, and intracerebral recordings of evoked potentials. *Neuroimage* 17: 1336-1346, 2002
- 17) Peyron R, Garcia-Larrea L, Deiber MP, Cinotti L, Convers P, Sindou M, Mauguiere F, Laurent B: Electrical stimulation of precentral cortical area in the treatment of central pain: electrophysiological and PET study. *Pain* 62: 275-286, 1995
- 18) Previnaire JG, Nguyen JP, Perrouin-Verbe B, Fattal C:

- Chronic neuropathic pain in spinal cord injury: efficiency of deep brain and motor cortex stimulation therapies for neuropathic pain in spinal cord injury patients. *Ann Phys Rehabil Med* 52: 188-193, 2009
- 19) Rasche D, Rinaldi PC, Young RF, Tronnier VM: Deep brain stimulation for the treatment of various chronic pain syndromes. *Neurosurg Focus* 21(6): E8, 2006
- 20) Rasche D, Ruppolt M, Stippich C, Unterberg A, Tronnier VM: Motor cortex stimulation for long-term relief of chronic neuropathic pain: a 10 year experience. *Pain* 121: 43-52, 2006
- 21) Saitoh Y, Shibata M, Hirano S, Hirata M, Mashimo T, Yoshimine T: Motor cortex stimulation for central and peripheral deafferentation pain. Report of eight cases. *J Neurosurg* 92: 150-155, 2000
- 22) Saitoh Y, Yoshimine T: Stimulation of primary motor cortex for intractable deafferentation pain. *Acta Neurochir Suppl* 97: 51-56, 2007
- 23) Tani N, Saitoh Y, Hirata M, Kato A, Yoshimine T: Bilateral cortical stimulation for deafferentation pain after spinal cord injury. Case report. *J Neurosurg* 101: 687-689, 2004
- 24) Tasker RR, DeCarvalho GT, Dolan EJ: Intractable pain of spinal cord origin: clinical features and implications for surgery. *J Neurosurg* 77: 373-378, 1992
- 25) Tsubokawa T, Katayama Y, Yamamoto T, Hirayama T, Koyama S: Chronic motor cortex stimulation for the treatment of central pain. *Acta Neurochir Suppl (Wien)* 52: 137-139, 1991
- 26) Tsubokawa T, Katayama Y, Yamamoto T, Hirayama T, Koyama S: Chronic motor cortex stimulation in patients with thalamic pain. *J Neurosurg* 78: 393-401, 1993
- 27) Young RF: Brain stimulation. *Neurosurg Clin N Am* 1: 865-879, 1990

Address reprint requests to: Takafumi Tanei, MD, Department of Neurosurgery, Nagoya Central Hospital, 3-7-7 Taiko, Nakamura-ku, Nagoya 453-0801, Japan.
e-mail: nsgtakasyun@msn.com