

# Severe Parkinsonism Following Endoscopic Third Ventriculostomy for Non-communicating Hydrocephalus

## —Case Report—

Takenori AKIYAMA,<sup>1</sup> Yoshio TANIZAKI,<sup>2</sup> Kazunori AKAJI,<sup>2</sup> Kenji HIRAGA,<sup>2</sup>  
Takekazu AKIYAMA,<sup>2</sup> Masaki TAKAO,<sup>3</sup> and Takayuki OHIRA<sup>1</sup>

<sup>1</sup>Department of Neurosurgery, Keio University School of Medicine, Tokyo;  
Departments of <sup>2</sup>Neurosurgery and <sup>3</sup>Neurology, Mihara Memorial Hospital, Isezaki, Gunma

### Abstract

A 23-year-old male with non-communicating hydrocephalus caused by intraventricular hemorrhage from an arteriovenous malformation was treated by endoscopic third ventriculostomy (ETV) after repeated ventricular cerebrospinal fluid drainage and removal of ventriculoperitoneal shunt due to infection. Postoperatively, the patient developed robust rigidity and akinesia with mutism, suggesting secondary parkinsonism. These symptoms showed marked improvement after administration of levodopa, and were not aggravated after discontinuation. The pathophysiology of this case might involve dysfunction of the dopaminergic system caused by repeated compression and release of the paraventricular white matter. Careful perioperative management not leading to excessive dilation of the the ventricles should be considered for ETV for non-communicating hydrocephalus to avoid this unexpected complication.

Key words: non-communicating hydrocephalus, parkinsonism, endoscopic third ventriculostomy, levodopa

### Introduction

Two uncommon complications related to treatment for non-communicating hydrocephalus have been reported, parkinsonism and akinetic mutism, both of which have been successfully treated with dopaminergic medication.<sup>1–4,10,11,14,16–18</sup> We treated a patient who developed severe parkinsonism or akinetic mutism after endoscopic third ventriculostomy (ETV) for non-communicating hydrocephalus.

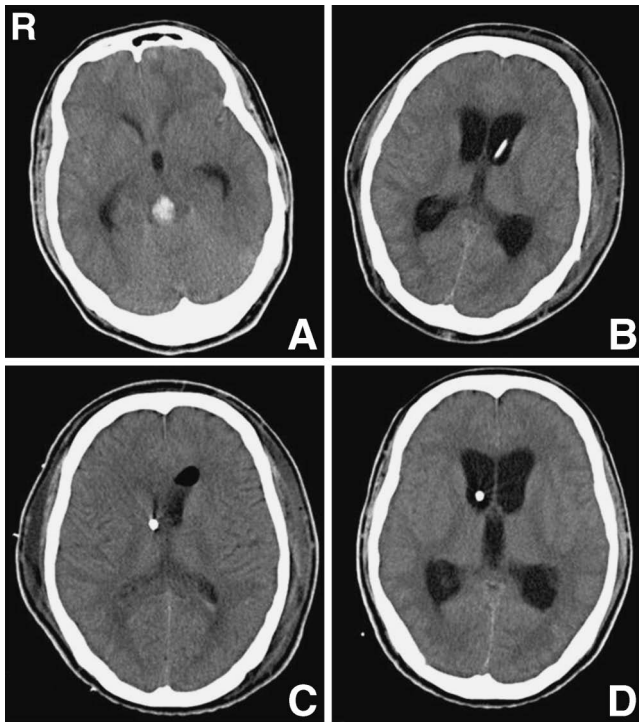
### Case Report

A 23-year-old male presented with an incidentally identified arteriovenous malformation (AVM) located on the dorsal surface of the midbrain in 2001. Gamma knife radiosurgery was performed on the lesion in the same year at another institution. Marginal prescription dose and maximum dose were 17 Gy and 34 Gy, respectively. Complete obliteration of the AVM was not achieved and the lesion annually followed up by magnetic resonance (MR) imaging. He became aware of speech disturbance and dizziness 7 years after gamma knife radiosurgery, and voluntarily requested admission by ambulance. He was emergently transferred to our hospital, as his consciousness level rapidly fell from E3V4M5 on the Glasgow Coma

Scale (GCS) to E1V1M3 in the ambulance.

Head computed tomography (CT) on admission revealed hemorrhage in the dorsal midbrain and the fourth ventricle with obstructive hydrocephalus (Fig. 1A). His consciousness level continued to deteriorate and the hydrocephalus became worse on the next day, so emergent cerebrospinal fluid (CSF) drainage was performed by tapping into the anterior horn of the lateral ventricle. His consciousness recovered to E4V5M6 immediately after the intervention. Bilateral ptosis and restriction of vertical eye movement due to midbrain dysfunction were noted without long tract signs. Endovascular embolization of the AVM nidus using liquid material was performed 10 days after the onset at another institute. N-butyl cyanoacrylate (NBCA) was injected from the main feeding artery, resulting in partial embolization of the nidus. Three weeks after the ventricular drainage, CSF drainage was tentatively stopped. However, hydrocephalus recurred with deterioration of consciousness (Fig. 1B). Therefore, a ventriculoperitoneal (VP) shunt procedure using a pressure-programmable valve was performed 3 weeks after the hemorrhage (Fig. 1C). Although his consciousness recovered fully, the patient developed a high fever several days after the VP shunt was installed. Subcutaneous pus along the shunt system was observed in addition to signs of meningitis in the CSF test. Therefore, the shunt system was removed and ventricular drainage was begun again.

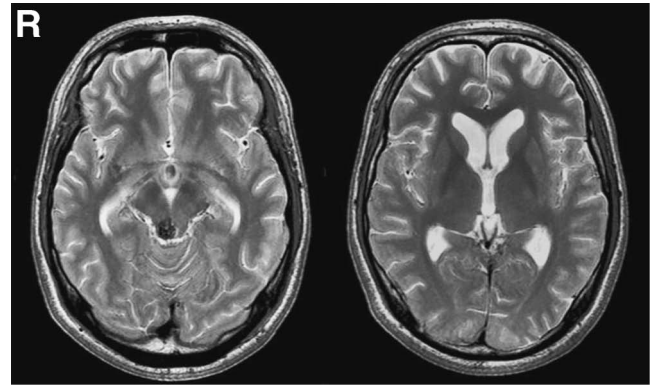
Following remission of the meningitis after thorough



**Fig. 1** A: Computed tomography (CT) scan demonstrating hemorrhage in the dorsal midbrain and the fourth ventricle. B: CT scan after cerebrospinal fluid drainage was tentatively clamped, showing marked ventriculomegaly. C: CT scan after ventriculoperitoneal shunt. D: CT scan just before endoscopic third ventriculostomy.

antibiotic therapy, ETV was scheduled. External CSF drainage had been opened at 15 cm above the level of external auditory meatus during antibiotic therapy. Twelve hours before ETV, the drainage level was raised to 18 cm, then at 8 hours before surgery to 20 cm, and completely clamped 4 hours before ETV to prevent overdrainage of the CSF, and to increase safety of endoscopic manipulation in the ventricles by keeping the ventricles expanded (Fig. 1D). During the preoperative preparation, the patient's consciousness slightly deteriorated to GCS E2V3M5. Our previous experience suggested that his consciousness would recover after reopening of the CSF drainage, so we performed ETV under general anesthesia as scheduled. The operation was performed through the left anterior horn approach using the rigid endoscope. Through the endoscope, obstruction of the midbrain aqueduct by old organized hematoma was observed, but the ventricular walls remained intact, ruling out ventriculitis and encephalitis. The floor of the third ventricle was firm due to acute hydrocephalus, but opening of the floor by blunt forceps and Fogarty balloon catheter was successfully performed without any trouble. The external CSF drainage was opened again in case of acute obstruction of the stoma.

Postoperative serial CT and MR imaging showed the size of the ventricles remained normal. Consciousness level improved to GCS E4V4M6 immediately after the ETV.



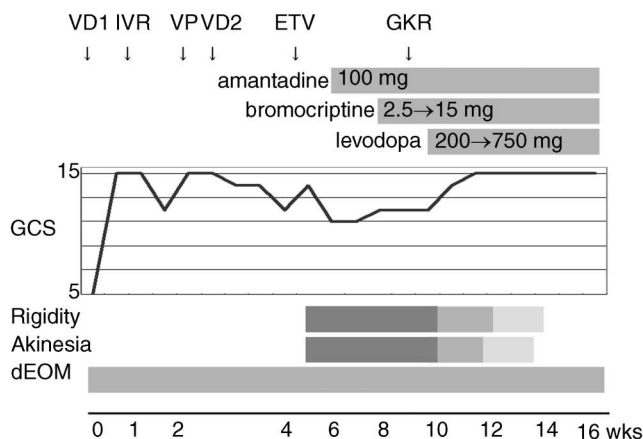
**Fig. 2** T<sub>2</sub>-weighted magnetic resonance images after endoscopic third ventriculostomy, demonstrating normal ventricular size, an arteriovenous malformation nidus on the dorsal surface of the midbrain, and no signal changes in the brain parenchyma.

Movement of the limbs was not disturbed although subtle increase of muscular tonus was observed in both lower limbs. Neither consciousness deterioration nor ventricular expansion on CT were observed after the drain was tentatively obliterated, then completely removed. However, the volume of his voice decreased gradually, the movement of his tongue, lips, and pharynx decreased prominently, and oral intake became difficult.

Ten days after the ETV, he became almost mute and immobile although with some nodding, and required total nursing care with tube feeding. The sleep cycle was undisturbed. Severe cogwheel rigidity was observed in his limbs and trunk. Tremor was not observed. Accentuations of the tendon reflex and strong clonus were observed in the bilateral lower limbs, but not in the upper limbs. Follow-up MR imaging detected no signs of ventricular enlargement, nor any change in the intensity of the brain parenchyma, ruling out encephalitis (Fig. 2). MR angiography showed no abnormal findings except for the distal posterior cerebral artery harboring the AVM. CSF examination showed remission of meningitis. Electroencephalography (EEG) revealed dominant slow waves in the frontal area without epileptic discharges. Blood tests including hormonal and inflammatory responses showed no abnormalities. Cerebral blood flow (CBF) by xenon CT was markedly decreased to 32 ml/100 g/min in the right hemisphere and 24 ml/100 g/min in the left.

We suspected that these symptoms were similar to those of secondary parkinsonism or akinetic mutism due to the obstructive hydrocephalus. Amantadine hydrochloride 100 mg per day was prescribed 2 weeks after the ETV (Fig. 3). Bromocriptine 2.5 mg per day was initiated 2 weeks later and gradually increased up to 15 mg per day. Slight improvements were observed, such as longer eye opening period and decreased muscle tonus of his neck. However, akinesia, mute state, and severe rigidity of the limbs and the trunk did not change and he remained completely bedridden.

Second gamma knife radiosurgery to the remaining ni-



**Fig. 3** Clinical course of this case. dEOM: disturbed extraocular movement, ETV: endoscopic third ventriculostomy, GCS: Glasgow Coma Scale, GKR: gamma knife radiosurgery, IVR: interventional radiology (liquid embolization of arteriovenous malformation nidus), VD1: first ventricular drainage, VD2: second ventricular drainage, VP: ventriculoperitoneal shunt.

dus was performed 5 weeks after the ETV, with marginal dose of 18 Gy and maximum dose of 36 Gy. Six weeks after the ETV, levodopa 200 mg per day was administered. After only 3 days, the amount of his speech dramatically increased, and the rigidity of the tongue and the arm was suddenly alleviated. The dose of levodopa was gradually increased up to 750 mg per day within the next month. Improvement of the rigidity of the lower limbs was also observed with some delay. In the early stage of his recovery, difficulties in initiating speech were observed, which could be improved by presenting verbal cues.

All symptoms improved with the increase of levodopa dose, and he started oral intake 2 months after the ETV, was able to walk with a cane in another 2 weeks, and could walk without assistance 3 months after the ETV. He reported afterwards, "I understood all conversations around me when I could not speak. I could not move my mouth, hands, and body parts at all because my whole body was so heavy." He was discharged home on foot and independent in activities of daily living with diplopia due to midbrain dysfunction 4 months after the ETV. Thereafter, levodopa was gradually withdrawn and discontinued without recurrence of his symptoms.

## Discussion

The present patient developed robust rigidity and akinesia, and recovery clearly correlated with the dosage of levodopa, although tremor was not found. Therefore, we suppose that these symptoms were equivalent to parkinsonism. Parkinsonism has been associated with repeated obstruction of the VP shunt for non-communicating hydrocephalus, especially in patients with aqueduct stenosis.<sup>3,4,10,14,16,18</sup> Intracranial pressure and its effect on the white matter fibers surrounding the ventricles due to shunt failure and subsequent release leads to malfunction-

ing of the dopaminergic pathway causing secondary parkinsonism. Another suspected mechanism involves the development and persistence of a transtentorial pressure gradient that could lead to global dysfunction of the upper midbrain.<sup>6</sup> In this case, until ETV was successfully performed, several episodes of enlarged ventricles occurred with increased intracranial pressure and subsequent release. We believe that a similar mechanism to secondary parkinsonism after acute shunt failure was the cause of the unusual symptoms in this patient, although parkinsonism after successful ETV has not been reported.

Akinetic mutism is also a rare manifestation of VP shunt failure in patients with aqueduct stenosis.<sup>4,11,12,17</sup> The present case can also be classified as akinetic mutism<sup>5</sup> because there was no involuntary movement or speech with the maintained sleep cycle. The brainstem ascending reticular formation activating system starts from the midbrain tegmental area, and projects into the diencephalon, and the striatum is supposed to be the center responsible for akinetic mutism, as well as the area including the bilateral medial frontal lobes and the cingulate gyrus.<sup>5,9,13,15</sup> This system is dopaminergic and projects through the paraventricular area which can be damaged by stretching of the ventricular wall. Therefore, repeated dramatic changes in ventricular size before or after intervention to non-communicating hydrocephalus, such as shunt failure or clamping the CSF drainage, can induce damage to the ascending dopaminergic projections leading to akinetic mutism or secondary parkinsonism which can be treated by dopaminergic agents.

We supposed that the characteristics of this case were more similar to secondary parkinsonism rather than akinetic mutism from the viewpoint of the symptoms. However, findings atypical of pure parkinsonism, including cortical slow wave in EEG, decreased CBF in the cortex, and pyramidal tract signs, were observed. These results indicate that not only the dopaminergic pathway but also other areas of the paraventricular white matter were damaged. Such bilateral pyramidal tract signs were observed in a patient originally considered to have akinetic mutism.<sup>5</sup> Akinetic mutism and parkinsonism manifesting secondary to treatment for non-communicating hydrocephalus caused by aqueduct stenosis may be similar in character and can coincide.<sup>4</sup> Most previous cases reported as parkinsonism or akinetic mutism contained both characters and have been treated by similar concepts. This case might also have both characteristics, so we think that this pathophysiology can be considered as "dysfunction of ascending dopaminergic pathway" or "acute dopamine deficiency syndrome" due to the drastic changes in the size of the ventricles, not as a single independent syndrome such as "secondary parkinsonism" or "akinetic mutism."

Other mechanisms explaining this symptom besides temporary damage to the paraventricular dopaminergic pathway can be postulated, such as decrease in dopamine production in the substantia nigra compacta due to midbrain hemorrhage, trans-arterially injected NBCA toxicity to the midbrain, dysfunction of basal ganglia due to meningitis or encephalitis, and others. The distinct effec-

tiveness of dopamine administration indicates that the dopaminergic system was important in this case regardless of the underlying mechanism.

Amantadine and bromocriptine did not show the expected responses in the symptoms based on previous.<sup>2,11,15)</sup> On the other hand, levodopa increased from 200 mg up to 750 mg per day showed marked responses and symptoms did not recur after discontinuation. We suppose that the dose of bromocriptine (15 mg per day) was insufficient to exhibit the expected clinical improvement because 15 mg of bromocriptine is equivalent to only 150 mg of levodopa.<sup>8)</sup> We cannot exclude the possibility of spontaneous recovery in this case, although the marked remission of arm and trunk rigidity and the dramatic increase of verbal response only 3 days after levodopa initiation supports the efficacy of levodopa on this pathology. Furthermore, the observation that dose escalation of levodopa from 200 mg to 750 mg per day led to a more prominent recovery of leg rigidity also supports this idea as the clinical symptoms changed parallel to the dosage of dopamine agonist in a previous case.<sup>2)</sup>

Complications of neuroendoscopic surgery for hydrocephalus include transient akinetic mutism in a patient with intraventricular hemorrhage after opening of the third ventricle cyst<sup>15)</sup> and in a patient with thalamic damage after ETV.<sup>7)</sup> Our patient presented with severe parkinsonism during the peri-operative period after successful ETV. This case implies that repeated trials of drainage clamping are required to decide whether the ventricular drainage can be removed and if the intended size increase of the ventricles to minimize the risk of neuroendoscopic manipulation during ETV carries any risk to induce dopaminergic dysfunction. We should pay close attention to avoid excessive expansion of the ventricular walls and prevent this unexpected complication in patients with aqueduct stenosis or occlusion indicated for ETV.

The present patient presented with severe rigidity, akinesia, and mutism after ETV. The pathophysiology of this case might represent dysfunction of the dopaminergic system caused by repeated compression and release of the paraventricular white matter. Administration of levodopa was effective for this patient although spontaneous recovery cannot completely be ruled out. This case indicates that careful preoperative management of the patients undergoing ETV for non-communicating hydrocephalus is mandatory to avoid episodes of repeated overdistention of the ventricles.

## References

- 1) Abekura M: Akinetic mutism and magnetic resonance imaging in obstructive hydrocephalus. Case illustration. *J Neurosurg* 88: 161, 1998
- 2) Anderson B: Relief of akinetic mutism from obstructive hydrocephalus using bromocriptine and ephedrine. Case report. *J Neurosurg* 76: 152–155, 1992
- 3) Asamoto S, Sugiyama H, Doi H, Yokochi M, Hirabayashi K, Tanaka S, Sugiura K, Nakama H, Matsumoto K: Levodopa effective parkinsonism associated with aqueductal stenosis: a case report and review of the literature. *No Shinkei Geka* 26: 1089–1092, 1998
- 4) Berger L, Gauthier S, Leblanc R: Akinetic mutism and parkinsonism associated with obstructive hydrocephalus. *Can J Neurol Sci* 12: 255–258, 1985
- 5) Cairns H, Oldfield R, Pennybacker J, Whitteridge D: Akinetic mutism with an epidermoid cyst of the 3rd ventricle. With a report on the associated disturbance of brain potentials. *Brain* 64: 273–290, 1941
- 6) Cinalli G, Sainte-Rose C, Simon I, Lot G, Sgouros S: Sylvian aqueduct syndrome and global rostral midbrain dysfunction associated with shunt malfunction. *J Neurosurg* 90: 227–236, 1999
- 7) Cinalli G, Spennato P, Ruggiero C, Aliberti F, Trischitta V, Buonocore MC, Cianciulli E, Maggi G: Complications following endoscopic intracranial procedures in children. *Childs Nerv Syst* 23: 633–644, 2007
- 8) Deuschl G, Schade-Brittinger C, Krack P, Volkmann J, Schafer H, Botzel K, Daniels C, Deutschlander A, Dillmann U, Eisner W, Gruber D, Hamel W, Herzog J, Hilker R, Klebe S, Kloss M, Koy J, Krause M, Kupsch A, Lorenz D, Lorenz S, Mehdorn HM, Moringlane JR, Oertel W, Pinski MO, Reichmann H, Reuss A, Schneider GH, Schnitzler A, Steude U, Sturm V, Timmermann L, Tronnier V, Trottenberg T, Wojtecki L, Wolf E, Poewe W, Voges J: A randomized trial of deep-brain stimulation for Parkinson's disease. *N Engl J Med* 355: 896–908, 2006
- 9) Kadota Y, Kondo T, Sato K: Akinetic mutism and involuntary movements following radical resection of hypothalamic glioma—case report. *Neurol Med Chir (Tokyo)* 36: 447–450, 1996
- 10) Kim MJ, Chung SJ, Sung YH, Lee MC, Im JH: Levodopa-responsive parkinsonism associated with hydrocephalus. *Mov Disord* 21: 1279–1281, 2006
- 11) Kim MS, Rhee JJ, Lee SJ, Kwon SJ, Lee CH: Akinetic mutism responsive to bromocriptine following subdural hematoma evacuation in a patient with hydrocephalus. *Neurol Med Chir (Tokyo)* 47: 419–423, 2007
- 12) Messert B, Henke TK, Langheim W: Syndrome of akinetic mutism associated with obstructive hydrocephalus. *Neurology* 16: 635–649, 1966
- 13) Nemeth G, Hegedus K, Molnar L: Akinetic mutism associated with bicingular lesions: clinicopathological and functional anatomical correlates. *Eur Arch Psychiatry Neurol Sci* 237: 218–222, 1988
- 14) Ochiai H, Yamakawa Y, Miyata S, Kawasoe T: [L-dopa effective parkinsonism appeared after shunt revision of the aqueductal stenosis: report of two cases]. *No To Shinkei* 52: 425–429, 2000 (Japanese)
- 15) Psarros T, Zouros A, Coimbra C: Bromocriptine-responsive akinetic mutism following endoscopy for ventricular neurocysticercosis. Case report and review of the literature. *J Neurosurg* 99: 397–401, 2003
- 16) Tokunaga H, Shigeto H, Inamura T, Kawajiri M, Nakasaki K, Furuya H, Kira J: [A case of severe parkinsonism induced by failure of ventriculo-peritoneal shunt for aqueductal stenosis]. *Rinsho Shinkeigaku* 43: 427–430, 2003 (Japanese)
- 17) Tsutsumi K, Yoshioka T, Hiu T, Matsuo Y, Yokoyama H: [Transient akinetic mutism induced by malfunction of a ventriculo-peritoneal shunt for obstructive hydrocephalus associated with aqueductal stenosis: case report]. *No Shinkei Geka Journal* 14: 469–475, 2005 (Japanese)
- 18) Zeidler M, Dorman PJ, Ferguson IT, Bateman DE: Parkinsonism associated with obstructive hydrocephalus due to idiopathic aqueductal stenosis. *J Neurol Neurosurg Psychiatry* 64: 657–659, 1998

Address reprint requests to: Takenori Akiyama, MD, Department of Neurosurgery, Keio University School of Medicine, 35 Shinano-machi, Shinjuku-ku, Tokyo 160-8582, Japan.  
e-mail: takiyama-jscn@umin.ac.jp