

Reactive Expansive Intracerebral Process as a Complication of Endovascular Coil Treatment of an Unruptured Intracranial Aneurysm: Case Report

Marton König, MD*
 Søren Jacob Bakke, MD, PhD‡
 David Scheie, MD, PhD§
 Wilhelm Sorteberg, MD, PhD*
 Torstein Ragnar Meling, MD, PhD*

Departments of *Neurosurgery, ‡Neuroradiology, and §Pathology, Oslo University Hospital, Rikshospitalet, Oslo, Norway

Correspondence:

Torstein R. Meling, MD, PhD,
 Head of Section,
 Department of Neurosurgery,
 Oslo University Hospital,
 Rikshospitalet,
 0027 Oslo, Norway.
 E-mail: torstein.meling@rikshospitalet.no

Received, October 9, 2009.

Accepted, April 27, 2010.

Copyright © 2011 by the
 Congress of Neurological Surgeons

BACKGROUND AND IMPORTANCE: As a consequence of the increased use of endovascular coiling of intracranial aneurysms, a growing number of case reports on complications are being reported. This article presents a case with a previously undescribed complication of coil treatment: a reactive, noninfectious process after coiling of an unruptured intracranial aneurysm

CLINICAL PRESENTATION: A 60-year-old hypertensive woman with hypoxic encephalopathy after respiratory arrest following a total thyroidectomy had extensive intentional myoclonus and reduced quality of life as sequelae. An asymptomatic 15-mm internal carotid artery bifurcation aneurysm was discovered on magnetic resonance imaging (MRI) 6 months after the thyroidectomy. After documented growth, the aneurysm was treated endovascularly with bare platinum Guglielmi detachable coils. Three months later, an expansion in the right frontal lobe cranially to the coiled aneurysm was observed. The lesion had grown at the 12-month postcoil MRI and, because of its increasing mass effect, was resected through a craniotomy 2 years after the coiling. As a result of lesion regrowth and cyst formation, she underwent a new craniotomy 5 years later with excision of the now 21-mm large coiled aneurysm, internal carotid artery clip reconstruction, and lesionectomy. Five months postoperatively, the process had not recurred. No signs of malignancy or infection were observed during the histological evaluation of the resected tissue. The tissue is described as a reactive, noninfectious process, most likely resulting from the coils acting as a foreign body.

CONCLUSION: This article presents a case with a reactive expansive intracerebral process as a complication to endovascular coil treatment of an unruptured intracranial aneurysm.

KEY WORDS: Complications, Endovascular treatment, Intracranial aneurysm, Neuropathology, Neurovascular surgery

Neurosurgery 68:E1468–E1474, 2011

DOI: 10.1227/NEU.0b013e318210c7c0

www.neurosurgery-online.com

Previously, intracranial aneurysm repair was exclusively surgical with most aneurysms being clipped.¹ However, since its introduction in 1991,² endovascular aneurysm repair has grown in popularity.^{3,4} Consequently, a growing number of case reports on complications of this treatment such as incomplete aneurysm coiling,^{5,6} aneurysm regrowth,⁷ aneurysm rupture,⁸ and failure to alleviate symptoms related to mass effect⁹ have been published.

ABBREVIATIONS: CRP, C-reactive protein; ICA, internal carotid artery; SR, sedimentation rate; WCC, white cell count

Bare platinum coils within an aneurysm exert a hemodynamic effect, resulting in an immediate major reduction in aneurysm blood flow.¹⁰ This may trigger the initial thrombus formation within the coil-filled sac that is gradually followed by inflammatory cellular responses around the coil material.¹¹ Approximately 2 weeks after treatment, the inflammatory changes are followed by the formation of granulation tissue, occasionally including foreign-body-type giant cells. Myofibroblasts and fibrocellular components such as collagen then progressively replace the initial thrombus, and fibrous scar tissue formation can be seen 1 month after treatment.¹¹

The inflammatory responses, formation of granulation tissue, and fibrous tissue formation after aneurysm coil placement may be looked on as wanted effects. Indeed, second-generation coils containing bioactive materials to facilitate or enhance the aneurysm healing process have been developed. Bioabsorbable polymeric material-coated coils are now part of the standard armamentarium in endovascular aneurysm repair. However, because bioabsorbable polymeric material coils elicit a greater inflammatory response, complications seen after the use of these coils include symptomatic chemical meningitis,¹² perimural edema,¹³ and hydrocephalus.¹³⁻¹⁵

In this report, we present a case of exaggerated immunological response to endovascular aneurysm repair with only bare platinum coils. After treatment of a 17-mm unruptured internal carotid artery (ICA) bifurcation aneurysm, a 60-year-old female patient developed over time a 50-mm large noninfectious reactive process in the perianeurysmal region. This reactive tissue response did stop until the coiled aneurysm was excised from the brain.

CASE REPORT

Clinical Presentation

Our patient, a 60-year-old hypertensive woman, underwent total thyroidectomy in February 2000 because of nodular goiter. The surgery was complicated by a postoperative respiratory arrest and a generalized tonic-clonic seizure lasting approximately 6 to 8 minutes. She underwent emergency tracheostomy and needed respiratory support for the following 14 days. She sustained hypoxic brain damage and developed an extensive intentional myoclonus, which still reduces her quality of life and general condition. Her myoclonus is being treated with clonazepam, and she receives thyroxin substitution therapy.

On cerebral magnetic resonance imaging (MRI) 6 months after the thyroid surgery, a 15-mm asymptomatic intracranial ICA bifurcation aneurysm was discovered (Figure 1). After the aneurysm grew from 15 to 17 mm, she was admitted to our department in December 2001 for aneurysm treatment. Cerebral digital subtraction angiography showed that the aneurysm had a small neck and contained no thrombus.

Intervention and Technique

Because the standard treatment of ICA bifurcation aneurysms < 20 mm at our department is endovascular, our patient underwent aneurysm coiling with multiple bare platinum Guglielmi detachable coils (Figure 2A and 2B). A neck remnant remained. The coiling procedure was carried out under total intravenous anesthesia and lasted 2 hours 20 minutes. No perioperative antimicrobial therapy was administered. Before treatment, the patient had a normal body temperature and a normal blood C-reactive protein (CRP) concentration (< 5 mg/L). After treatment, she had a temporary increase in CRP (peak value, 146 mg/L), a slightly increased (18 mm) sedimentation rate (SR), but a normal ($8.8 \times 10.9/L$) white cell count (WCC). She had no postoperative fever, headache, nuchal rigidity, or photophobia. Postoperative urine analysis and chest x-ray showed no sign of infection. She was discharged from our hospital 3 days after the coiling.

At the 3-month follow-up, she reported a decrease in her gait function and worsening of her myoclonus from approximately 2 weeks after the treatment. MRI scans demonstrated a perianeurysmal edema measuring

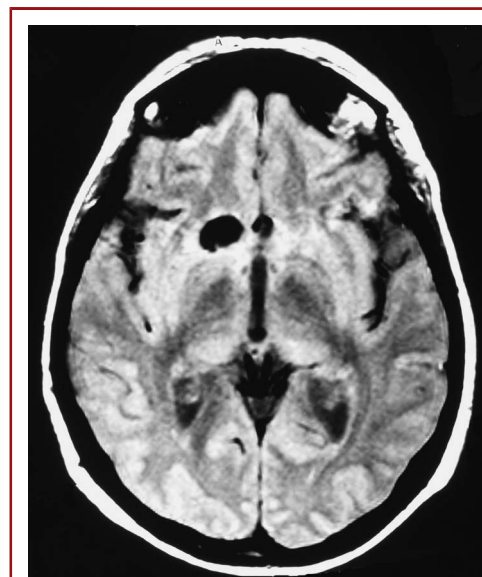


FIGURE 1. Magnetic resonance image showing a right-sided unruptured internal carotid artery bifurcation aneurysm measuring 15 mm.

approximately 25 mm in diameter (Figure 3). Both MR angiography and digital subtraction angiography showed moderate coil compaction in the aneurysm. A blood count showed no sign of infection (CRP < 5 mg/L; WCC: $4.9 \times 10^9/L$). No cerebrospinal fluid (CSF) analysis was performed. We decided on no medical treatment of the perianeurysmal edema and no recoiling of the aneurysm. She was discharged to her home and scheduled for a follow-up 12 months later.

Shortly before the scheduled follow-up, the patient was readmitted to our department because of complete loss of gait function, urine incontinence, visual hallucinations, and worsening of her cognitive functions. The MRI now showed a 22-mm perianeurysmal expansive

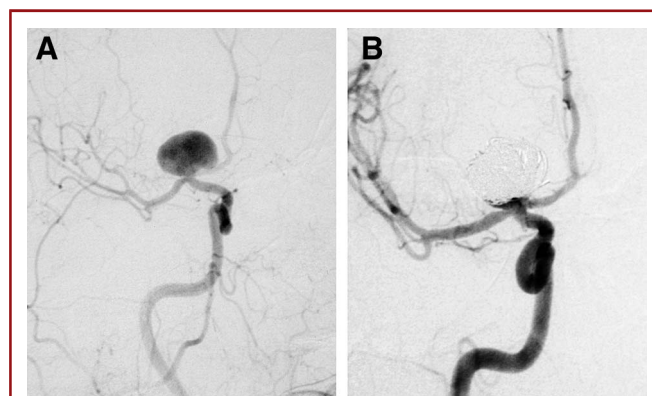


FIGURE 2. A, digital subtraction angiography (DSA) before endovascular treatment of the aneurysm with Guglielmi detachable coils (GDCs). B, DSA after endovascular treatment of the aneurysm with GDCs.

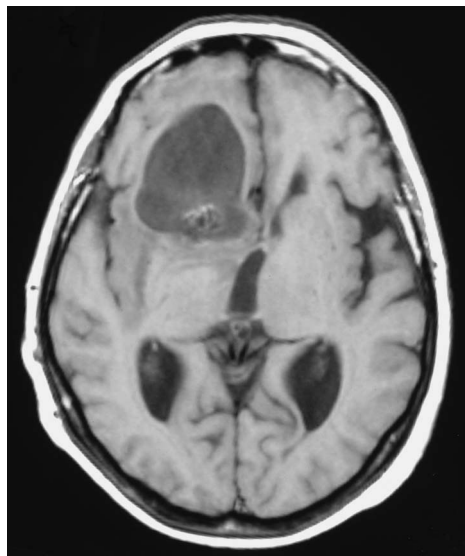


FIGURE 3. A 3-month postoperative magnetic resonance image showing an expansive process around the coiled aneurysm (axial section).

process (Figure 4). MR angiography documented considerable coil compaction with recirculation in a major part of the aneurysm. After routine urine investigation showed a lower urinary tract infection, she was treated with trimethoprim 320 mg/24 h PO 5 days preoperatively. The aneurysm was successfully recoiled, requiring 1.25 m of GDC. The procedure lasted 1 hour 40 minutes and was carried out under total intravenous anesthesia. Postoperative full blood count showed a temporary increase in CRP with a peak value of 30 mg/L 2 days after the intervention. Her WCC and SR remained within reference values throughout the stay.

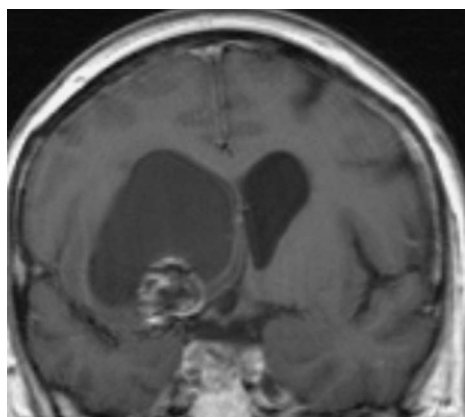
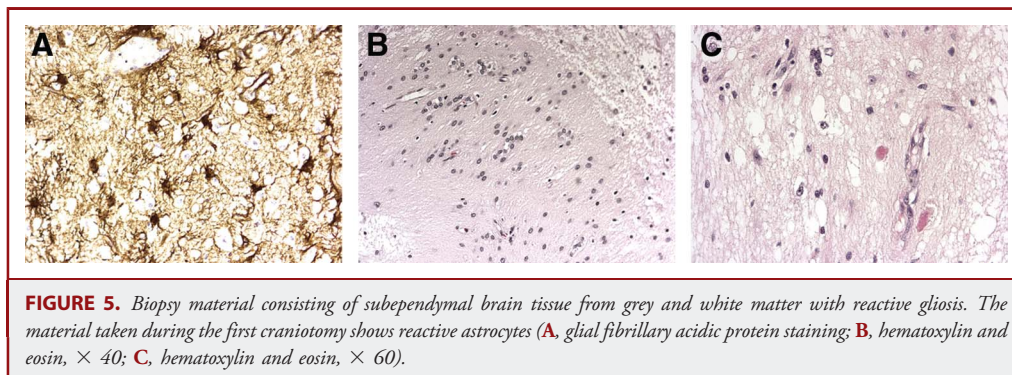


FIGURE 4. Magnetic resonance image taken before the first craniotomy showing the expansive process lifting the floor of the lateral ventricle on the right side (coronal section).

One month later, a new MRI showed further growth of the perianeurysmal process, now measuring 50 mm in diameter and with a perilesional cyst growing toward the foramen of Monroe. There was no contrast enhancement in the mass. A low-grade tumor was suspected. MR angiography showed no circulation within the expansion. A urinary tract infection was diagnosed and treated with trimethoprim 600 mg/24 h PO and ciprofloxacin 1 g/24 h PO through 3 and 4 days, respectively. Full blood count showed CRP, WCC, and SR within reference values. Because of her progressive neurological symptoms, she underwent a craniotomy with fenestration of the cystic lesion and a lesionectomy. The resected tissue had mucous characteristics. Numerous biopsies were taken from the periphery of the lesion. The biopsy material consisted of small fragments of subependymal brain tissue from grey and white matter with reactive gliosis, scattered eosinophilic granular bodies, and small perivascular aggregates of lymphocytes. Granulomas or foreign-body-type giant cells were not observed. Glial fibrillary acidic protein staining confirmed the presence of reactive astrocytes. Perls Prussian blue staining demonstrated no sign of iron deposition. Tumor tissue was not observed (Figure 5). The patient received perioperative steroid treatment with an intravenous methylprednisolone bolus of 40 mg followed by 80 mg/24 h, which was decreased to 10 mg/24 h IV over a period of 8 days and then stopped. A standard dose of cefalotin 2 g IV was administered at the start of the operation. Treatment with peroral ciprofloxacin 1 g/24 h was continued until the third postoperative day. After surgery, there were temporary increases in CRP (peak, 16 mg/dL), WCC ($11.4 \times 10^9/L$), and SR (18 mm). The patient was discharged after an uneventful recovery. At a check-up 3 months after surgery, improvement was seen in her clinical performance, and an MRI showed no regrowth of the expansion (Figure 6).

In subsequent years, she had follow-ups at her local neurological department. Repeat MRI investigations showed a continuous growth of the expansion surrounding the previously coiled aneurysm (Figure 7A and 7B). She was readmitted to our department as an emergency case 5 years after the surgical treatment (November 2008) as a result of increasing confusion, seizures, aphasia, and decreasing level of consciousness. Cerebral computed tomography (CT) showed enlarged lateral ventricles and a multicystic lesion on the right side occluding the foramen of Monroe. She was treated with endoscopic third ventriculostomy and attempted fenestration of the cysts, together with placement of an external ventricular drain and intracerebral pressure sensor. During surgery, 2 g cefalotin was administered intravenously as prophylactic antimicrobial treatment. On the day of the surgery, CSF analysis showed glucose concentration of 5 mmol/L, total protein concentration of 1.58 g/L, and a WCC of 0 and $1 \times 10^6/L$.

The clinical condition of the patient, however, did not improve, and serial computed tomography imaging demonstrated cyst regrowth and secondary midline shift (Figure 8). The senior author (T.R.M.) therefore opted for a craniotomy to excise the coiled ICA aneurysm (now measuring 21 mm), thus removing the anticipated cause of the immunological reaction (Figure 9). Intraoperatively, part of the coil material was located outside the aneurysm wall and in contact with the gliotic, scarred brain tissue. The coiled aneurysm was excised under temporary clip ligation of the ICA, and the ICA bifurcation was subsequently reconstructed with a Sugita 15 and a Yasargil 710 clip. The remaining cysts were fenestrated, the lamina terminalis was opened, and numerous biopsies were taken from the perilesional area. Histological examination also demonstrated this time brain tissue with reactive gliosis and small collections of CD68-positive macrophages. Granulomas or foreign-body-type giant cells were not observed. Again, there were no signs of



tumor tissue or infection (Figure 10). During the aneurysm surgery, a total of 6 g cefalotin was administered intravenously as prophylactic antimicrobial treatment.

The patient had later undergone intracerebral pressure monitoring to evaluate her cerebral hydrodynamics and had a ventriculoperitoneal shunt implanted. Routine CSF and blood investigations carried out perioperatively showed no evidence of infection. At a later follow-up, she was awake, alert, and able to communicate. She is using a wheelchair because of her hypoxic encephalopathy and receives daily nursing care. Postoperative MRI taken 5 months after the last aneurysm craniotomy has shown no evidence of regrowth of the expansion (Figure 11).

DISCUSSION

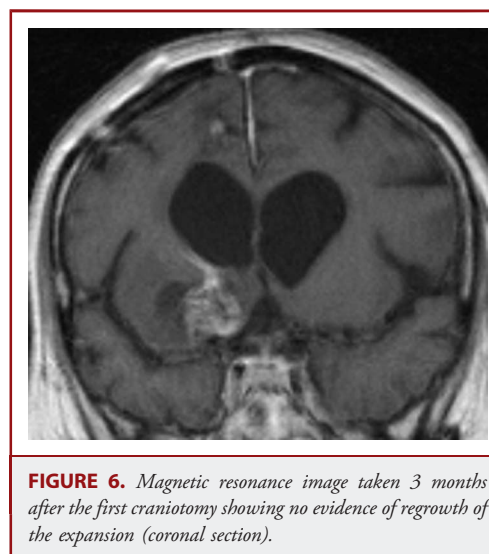
This case report describes a woman who developed an expansive intracerebral process secondary to endovascular coil treatment of an unruptured intracranial aneurysm with bare platinum coils. The response triggered in the brain tissue seemed to be acting slowly, lasted a period of years, and did not end until the coiled aneurysm was excised from the brain. She also developed secondary hydrocephalus that required shunt placement.

The perianeurysmal edema seen on MRI scans at the 3-month follow-up in our case resembles that seen in 1 of the 2 cases reported by Meyers et al¹² on chemical meningitis after aneurysm treatment with 2 second-generation aneurysm coils. In their cases, the MRI findings were seen 3 weeks after the coil treatment. Their patients had symptoms and signs of meningitis, a clinical picture not seen in our patient.

The blood-brain barrier, critical to the maintenance of homeostasis within nervous system tissue, is carried out by highly specialized brain microvascular endothelial cells, which lack pinocytotic vesicles and fenestrae but possess intercellular tight junctions.¹⁶ These features limit transcellular and paracellular movement of molecules and cells. During immune-mediated events, however, blood-brain barrier function is lost, and cellular components of the immune system gain access to the nervous system.^{17,18} Edema frequently accompanies these events. Our finding during aneurysm surgery that part of the coil material was located outside the aneurysm wall and in direct contact with the surrounding brain tissue could possibly have allowed exposure of the coil material to the brain cells.

Colonization of coils, which act as a foreign-body nidus, may rarely lead to localized infection.¹⁹⁻²⁴ The infective microorganism that colonizes the coils may be introduced at the time of endovascular coil placement or may be released in the circulation in the course of a concomitant infection that leads to hematogenous dissemination. Bacteremia has been documented to occur at a rate of 32% in therapeutic angiography procedures lasting > 2 hours.^{22,25,26} However, infectious complications are rare because the endovascular approach does not affect the brain-blood barrier significantly,¹⁹ and thus only a few cases of infection, usually brain abscesses, of the central nervous system attributable to coils and cyanoacrylate have been reported.¹⁹⁻²⁴

The histological evaluation of multiple biopsies, taken from the periphery and from the perianeurysmal area, in our patient demonstrated no signs of a neoplastic process or infection, only reactive gliosis and a slight, unspecific inflammation. The time interval between coil placement and the onset of the reactive event was longer than in the previously described cases¹⁹⁻²⁴ and persisted after administration of several antimicrobial agents. The



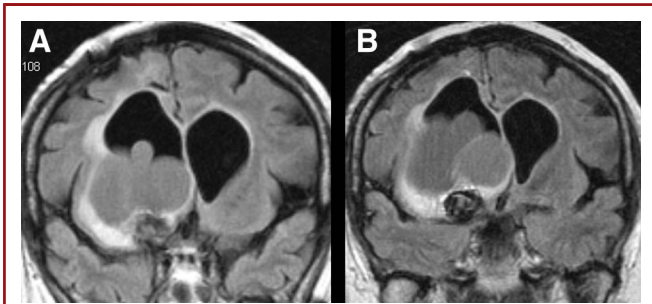


FIGURE 7. Magnetic resonance image follow-up at 20 (A) and 27 (B) months postoperatively showing growth of the expansive process around the previously coiled aneurysm with surrounding edema of the brain tissue, causing midline shift (coronal sections).

patient received antimicrobial therapy several times connected to her multiple treatments, and septic follow-ups did not show evidence of infection (CRP, WCC, SR). Consequently, an infectious etiology is unlikely. Moreover, the histological evaluation of the resected tissue samples demonstrated an exaggerated immunological tissue process. Although granulomas or foreign-body-type giant cells were not observed, we interpret the reactive changes as secondary to the coil material.

Despite having been treated with opening of the lamina terminalis during aneurysm surgery, thus creating an additional CSF route, our patient needed shunt placement to resolve her hydrodynamic problems. Except for mechanical blocking of CSF flow from the mass effect of giant aneurysms, development of

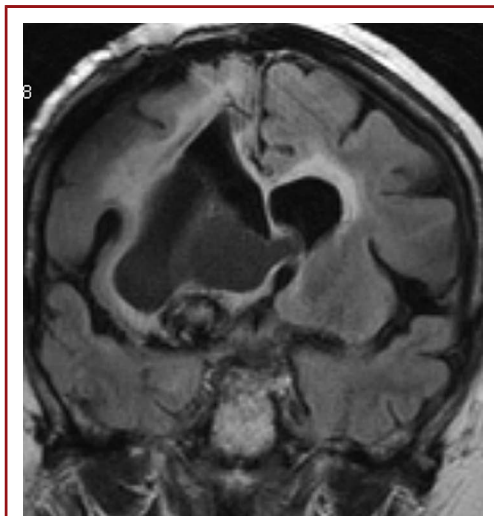


FIGURE 8. Magnetic resonance image showing the expansive process above the previously coiled aneurysm 5 years after the first craniotomy, a few days before the second craniotomy (coronal section).

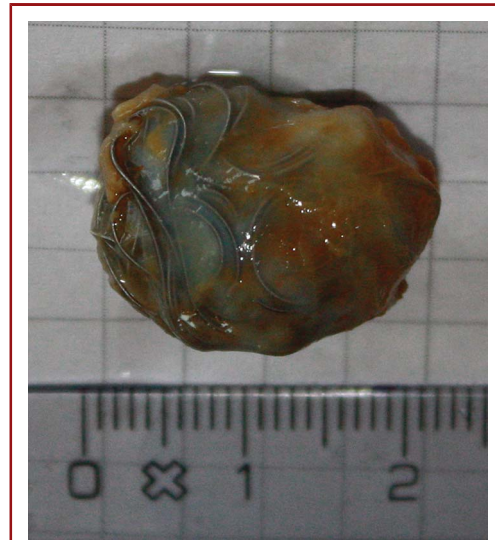


FIGURE 9. Photograph of the excised internal carotid artery bifurcation aneurysm with endovascular coils outside the aneurysm wall.

delayed hydrocephalus secondary to coiling of unruptured aneurysms is rare. Recently, communicating hydrocephalus has been described secondary to the use of second-generation bioactive coils in the treatment of unruptured intracranial aneurysms.¹³⁻¹⁵ In the series of Marchan et al¹⁴ in which 29 patients were treated with HydroCoils, the “clean” results of the CSF analysis suggest that neither inflammation nor infection was the cause of hydrocephalus in the 4 patients who developed secondary hydrocephalus. In addition, they considered aseptic meningitis not to be the cause of the secondary hydrocephalus in their cases. In the 2 cases of secondary hydrocephalus after use of HydroCoils reported by Mitha et al,¹⁵ the inserted shunt later had to be revised owing to shunt failure. In both cases, they found the ventricular catheter to be partially obstructed by a clear gelatinous material, with histopathological analysis of the shunt

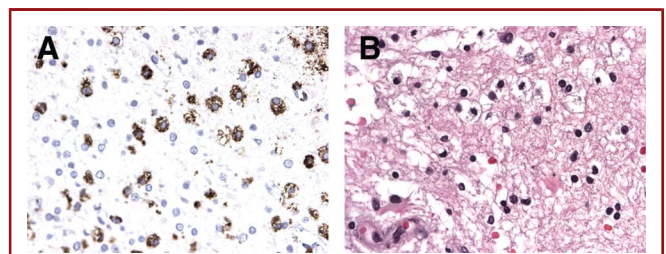


FIGURE 10. Biopsy material taken during the second craniotomy showing reactive gliosis similar to the material taken after the first craniotomy and small collections of CD68-positive macrophages. No sign of tumor tissue (A, CD68; B, hematoxylin and eosin, × 60).

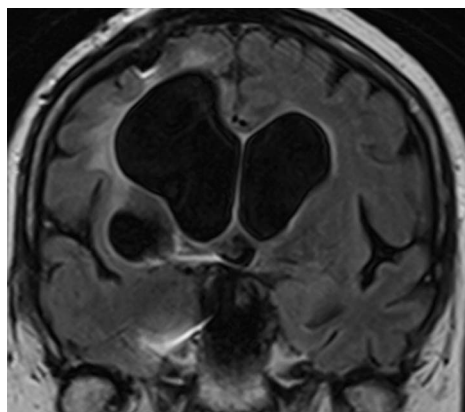


FIGURE 11. Magnetic resonance image taken 5 months after the second craniotomy.

revealing a basophilic, nonreactive, acellular, and amorphous foreign material with associated granulomatous inflammation. A possible explanation for the hydrocephalus secondary to the use of HydroCoils was that, by reaching the CSF, the Hydrogel polymer or an associated breakdown product altered cerebral hydrodynamics to a degree causing secondary hydrocephalus. In contrast, there was no exposure to such products in our patient.

CONCLUSION

We report on a female patient who over time developed an expansive intracerebral process secondary to endovascular coil treatment with only bare platinum coils. The response in the brain did not stop until the aneurysm with its platinum coils was excised. Except for her prior episode of major cerebral hypoxia, no previous serious damage to the brain before the aneurysm coiling could be documented or linked to her exaggerated immunological response.

Disclosure

The authors have no personal financial or institutional interest in any of the drugs, materials, or devices described in this article.

REFERENCES

- Raftopoulos C, Goffette P, Vaz G, et al. Surgical clipping may lead to better results than coil embolization: results from a series of 101 consecutive unruptured intracranial aneurysms. *Neurosurgery*. 2003;52(6):1280-1287.
- Guglielmi G. History of the genesis of detachable coils: a review. *J Neurosurg*. 2009;111(1):1-8.
- Levy EI, Siddiqui AH, Hopkins LN, Langer DJ, Ogilvy CS. Cerebrovascular surgery: evolution or obsolescence. *J Neurosurg*. 2009;111(1):195-197.
- Higashida RT, Lahue BJ, Torbey MT, Hopkins LN, Leip E, Hanley DF. Treatment of unruptured intracranial aneurysms: a nationwide assessment of effectiveness. *AJNR Am J Neuroradiol*. 2007;28(1):146-151.
- Ferns SP, Sprengers ME, van Rooij WJ, et al. Coiling of intracranial aneurysms: a systematic review on initial occlusion and reopening and retreatment rates. *Stroke*. 2009;40(8):e523-e529.
- Henkes H, Fischer S, Liebig T, et al. Repeated endovascular coil occlusion in 350 of 2759 intracranial aneurysms: safety and effectiveness aspects. *Neurosurgery*. 2006;58(2):224-232.
- van Rooij WJ, Sprengers ME, Sluzewski M, Beute GN. Intracranial aneurysms that repeatedly reopen over time after coiling: imaging characteristics and treatment outcome. *Neuroradiology*. 2007;49(4):343-349.
- Molyneux AJ, Kerr RS, Birks J, et al. Risk of recurrent subarachnoid haemorrhage, death, or dependence and standardised mortality ratios after clipping or coiling of an intracranial aneurysm in the International Subarachnoid Aneurysm Trial (ISAT): long-term follow-up. *Lancet Neurol*. 2009;8(5):427-433.
- Tawk RG, Villalobos HJ, Levy EI, Hopkins LN. Surgical decompression and coil removal for the recovery of vision after coiling and proximal occlusion of a clinoidal segment aneurysm: technical case report. *Neurosurgery*. 2006;58(6):E1217.
- Sorteberg A, Sorteberg W, Rappe A, Strother CM. Effect of Guglielmi detachable coils on intraaneurysmal flow: experimental study in canines. *AJNR Am J Neuroradiol*. 2002;23(2):288-294.
- Yuki I, Lee D, Murayama Y, et al. Thrombus organization and healing in an experimental aneurysm model, part II: the effect of various types of bioactive bioabsorbable polymeric coils. *J Neurosurg*. 2007;107(1):109-120.
- Meyers PM, Lavine SD, Fitzsimmons BF, et al. Chemical meningitis after cerebral aneurysm treatment using two second-generation aneurysm coils: report of two cases. *Neurosurgery*. 2004;55(5):1222.
- Fanning NF, Willinsky RA, ter Brugge KG. Wall enhancement, edema, and hydrocephalus after endovascular coil occlusion of intradural cerebral aneurysms. *J Neurosurg*. 2008;108(6):1074-1086.
- Marchan EM, Sekula RF Jr, Ku A, et al. Hydrogel coil-related delayed hydrocephalus in patients with unruptured aneurysms. *J Neurosurg*. 2008;109(2):186-190.
- Mitha AP, Wong JH, Lu JQ, Morrish WF, Hudon ME, Hu WY. Communicating hydrocephalus after endovascular coiling of unruptured aneurysms: report of 2 cases. *J Neurosurg*. 2008;108(6):1241-1244.
- Gloor SM, Wachtel M, Bolliger MF, Ishihara H, Landmann R, Frei K. Molecular and cellular permeability control at the blood-brain barrier. *Brain Res Brain Res Rev*. 2001;36(2-3):258-264.
- Engelhardt B, Ransohoff RM. The ins and outs of T-lymphocyte trafficking to the CNS: anatomical sites and molecular mechanisms. *Trends Immunol*. 2005;26(9):485-495.
- Ransohoff RM, Kivisakk P, Kidd G. Three or more routes for leukocyte migration into the central nervous system. *Nat Rev Immunol*. 2003;3(7):569-581.
- Jenkinson MD, Javadpour M, Nixon T, Warnke P. Intracerebral abscess formation following embolisation of an internal carotid artery aneurysm using Guglielmi detachable coils. *Acta Neurochir (Wien)*. 2003;145(8):703-705.
- Mourier KL, Bellec C, Lot G, et al. Pyogenic parenchymatous and nidus infection after embolization of an arteriovenous malformation: an unusual complication: case report. *Acta Neurochir (Wien)*. 1993;122(1-2):130-133.
- Zurin AA, Ushikoshi S, Houkin K, Kikuchi Y, Abe H, Saitoh H. Cerebral abscess as an unusual complication of coil embolization in a dural arteriovenous fistula: case report. *J Neurosurg*. 1997;87(1):109-112.
- Al-Okaili R, Patel SJ. Brain abscess after endovascular coiling of a saccular aneurysm: case report. *AJNR Am J Neuroradiol*. 2002;23(4):697-699.
- Kirollos RW, Bosma JJ, Radhakrishnan J, Pigott TD. Endovascularly treated cerebral aneurysm using Guglielmi detachable coils acting as a nidus for brain abscess formation secondary to Salmonella bacteremia: case report. *Neurosurgery*. 2002;51(1):234-237.
- Diaz-Romero R, Zenteno M, Santos-Franco JA, Soto-Hernandez JL, Lee A. Perianeurysmal abscess and meningitis after endovascular coil placement for an intracranial aneurysm. *Surg Infect (Larchmt)*. 2009;10(4):359-362.
- Meyer P, Reizine D, Merland JJ, Guerin JM. Nosocomial septicemia and therapeutic angiography: apropos of 4 cases [in French]. *Ann Radiol (Paris)*. 1988;31(1):34-36.
- Shawker TH, Kluge RM, Ayella RJ. Bacteremia associated with angiography. *JAMA*. 1974;229(8):1090-1092.

COMMENT

König et al report an interesting case of a patient with an intracranial aneurysm treated with bare platinum coils who developed a significant and prolonged inflammatory response. This subsequently led to further endovascular treatment, endoscopic cyst fenestration, and then

ultimately excision of the aneurysm and clip reconstruction of the parent vessel. Postcoiling inflammatory reactions have been previously reported with virtually every type of aneurysm coil. Nevertheless, there are a few interesting findings in this case report. Notably, despite the exuberant reaction to the coil mass, the aneurysm still recurred in a manner that required retreatment, which is paradoxical to bioactive coil data that a biological response to the coil mass may enhance aneurysm obliteration. In addition, the progression of the patient's inflammatory process occurred over a long follow-up period, which demonstrated that even with delayed steroid treatment, it was not a self-limiting process,

ultimately requiring microsurgical intervention. Finally, given some of the eosinophilic bodies identified on initial histology, it would be interesting to test the patient for metallurgic allergies, given that even bare platinum coils can contain some trace impurities. Fortunately, severe inflammatory reactions after aneurysm coil embolization are exceedingly uncommon and are typically self-limiting with medical treatment. However, as illustrated in this report, in suspected cases, close clinical and radiographic follow-up is mandatory.

Louis J. Kim
Seattle, Washington