

MAJOR REVIEW

Migraine-like Visual Aura Due to Focal Cerebral Lesions: Case Series and Review

Pari N. Shams, BSc, MRCP, MRCOphth,^{1,2} and Gordon T. Plant, MD, FRCP, FRCOphth^{1,2,3}

¹The National Hospital for Neurology & Neurosurgery, London; ²Moorfields Eye Hospital, London; and ³St Thomas' Hospital, London, UK

Abstract. Visual aura is a common presenting symptom of migraine to both neurologists and ophthalmologists. Features such as photopsia, fortification spectra, and the slow propagation of a scintillating scotoma across the visual field are usually considered diagnostic features of the visual aura of migraine. In the vast majority of cases, the diagnosis can be made without the need for further investigations. We present 9 patients and a further 31 cases from the literature who experienced visual aura fulfilling the diagnostic criteria for migraines but caused by focal occipital pathology. Key clinical features that could help to differentiate between the visual aura of migraine and those suggestive of a structural lesion are outlined. We review current scientific theories into the pathophysiology of visual aura, drawing on clinical and basic science research, including human functional imaging studies of migraine aura and advances in the genetic characterization of familial channelopathies, in order to explain the overlap which occurs in the clinical features of visual aura associated with migraine, cortical lesions, and epilepsy. We conclude that any disease process that is able to create a state of neuronal hyperexcitability can therefore increase an individual's susceptibility to the development of cortical spreading depression, the electrophysiological correlate of the visual aura. (*Surv Ophthalmol* 56:135–161, 2011. © 2011 Elsevier Inc. All rights reserved.)

Key words. cerebral lesions • epileptic aura • migraine visual aura • neuronal hyperexcitability • occipital lobe epilepsy • visual hallucinations

I. Introduction

Ten percent (10%) of the general population are active migraineurs,⁹⁴ and a third of all migraine attacks are associated with aura.⁹⁶ Positive, episodic visual phenomena are the most common form of aura in migraine (99%);⁹⁴ may also be the first and only ictal manifestation of occipital lobe epilepsy^{75,104} or seizures arising from any part of the visual pathway; and can occur in the context of focal cerebral pathology, in particular of the visual cortex. Notably, post-ictal headaches often indistinguishable from

migraine occur in over 50% of patients, even after brief visual seizures;^{84,85} following a similar “asymptomatic interval” as seen in migraine.¹¹ Headache also occurs in more than 60% of patients with brain tumors over the course of their disease.¹⁰⁰

II. The Classic Visual Aura of Migraine

Most patients with typical migrainous visual aura experience a biphasic aura preceding the onset of headache that consists of a homonymous scotoma of shimmering lights (positive visual phenomena), in

most cases originating from the primary visual cortex, usually restricted to one half of the visual field. Typically the scotoma arises near to fixation and gradually enlarges in the form of an arc, with scintillating or sparkling zigzag lines at its leading edge. The arc gradually moves to the periphery of the affected hemifield with the size of the zigzag lines increasing with retinal eccentricity as predicted by the cortical magnification factor. Within minutes this is followed in the affected area by negative symptoms such as a blank scotoma or hemianopia. There are many variations on this theme: for example, some patients experience a visual disturbance which is akin to “heat-haze,” others fractured vision—as if looking in a broken mirror. The electrophysiological phenomenon thought to underlie the migraine visual aura is known as cortical spreading depression (CSD).⁵⁶ First hypothesized by the clinical observations of Milner⁶⁹ and Lashley,⁵⁴ and based on the experiments of Leão in the rabbit,^{58–60} CSD is a slowly propagating wave of neuronal and glial depolarization, followed by long lasting suppression of cortical activity, that spreads across the cortex at a rate of 3 mm/minute, the same rate at which the scintillating scotoma propagates from the centre to the periphery of the visual field during a migraine aura.⁵³ This in turn can trigger the cascade of pathophysiological events, for example, activation of cells in the trigeminal nucleus caudalis in the medulla,^{12,34} that lead to the headache and other autonomic disturbances of migraine.

III. Typical Migraine-like Visual Aura Not Due to Migraine

The diagnostic criteria for typical migraine visual aura as defined by the International Classification of Headache Disorders (ICHD)⁴³ excludes any organic disease that may cause headache (Table 1). It is a commonly held view that the visual disturbances caused by cortical lesions do not conform to the time, pattern, appearance, or manner of spread of migraine scintillations.⁴¹ Migraine-like visual aura otherwise fulfilling the ICHD criteria, however, have been reported to occur with a variety of cerebral lesions,^{7,16,17,25,27,36,42,45,48,50,52,63,64,74,79,88,98,101,105,110,113,114,121} with or without associated headache.

Because the lifetime prevalence of migraine in the general population is approximately 18%,¹⁰⁶ it would not be unusual for a patient with a cerebral lesion, even one within the visual pathway, to have coincidental migraine and visual aura. Studies comparing the semiology of migraine-like visual aura and the visual phenomena of occipital lobe epilepsy have emphasised the duration and specific clinical features of the aura that could distinguish between the two conditions.^{83,84}

Table 1

Diagnostic Criteria for Typical Migraine Visual Aura

-
- A. At least two attacks fulfilling criteria B–D
 - B. Aura consisting of at least one of the following, but no motor weakness:
 1. Fully reversible visual symptoms including positive features (e.g., flickering lights, spots, or lines) and/or negative features (i.e., loss of vision)
 2. Fully reversible sensory symptoms including positive features (i.e., pins and needles) and/or negative features (i.e., numbness)
 3. Fully reversible dysphasic speech disturbance
 - C. At least two of the following:
 1. Homonymous visual symptoms and/or unilateral sensory symptoms
 2. At least one aura symptom develops gradually over ≥ 5 minutes and/or different aura symptoms occur in succession over ≥ 5 minutes
 3. Each symptom lasts ≥ 5 and ≤ 60 minutes
 - D. Headache begins during the aura or follows aura within 60 minutes
 - E. Not attributed to another disorder
-

As defined by the International Classification of Headache Disorders (ICHD).⁴³

IV. Migraine-like Visual Aura: Migraine or Structural Intracranial Pathology? The Evidence

A third of migraineurs, or 1–3% of the general population, will present to their general practitioner, neurologist, or ophthalmologist complaining of visual aura. The occurrence of typical migraine-like visual aura as the result of a structural lesion, in the absence of other neurological signs or symptoms, is rare, yet knowing which patient requires neuroimaging is a common clinical problem.

In order to critically examine the true nature of visual aura secondary to structural lesions and compare them to those of migraine, we carried out a detailed prospective observational study of nine patients presenting with migraine-like visual aura caused by focal cerebral lesions seen in the practice of one neuro-ophthalmologist (GTP) at the National Hospital for Neurology and Neurosurgery and Moorfields Eye Hospital London between 1986 and 2009. The clinical histories were compiled using case notes and patient interviews. See the Appendix (Case histories) for a detailed description; Table 2 provides a summary of these nine cases. Table 3 is a compilation of a further thirty-one case histories from the world literature of patients with migraine-like visual aura secondary to cerebral lesions.^{7,16,17,25,27,36,42,45,48,50,52,63,64,74,79,88,98,101,105,110,113,114,121}

V. Migraine or Structural Intracranial Pathology? Key Diagnostic and Differentiating Clinical Features of the Visual Aura

A. CLINICAL FEATURES THAT CANNOT RELIABLY DIFFERENTIATE THE VISUAL AURA OF MIGRAINE FROM THOSE DUE TO A STRUCTURAL LESION

1. Scintillating Scotoma or Teichopsia

The semiology of the visual aura of typical migraine varies considerably; however, the most common is the fortification spectrum—otherwise known as teichopsia—⁸⁹ an expanding arc of zigzag lines orientated at 60° with respect to one another, generated from activation of the orientation specific ocular dominance columns in the striate cortex.³⁸ All nine of our cases had been diagnosed as idiopathic migraine on the basis of the semiology of their visual aura and serve to illustrate the point that structural cerebral lesions can induce visual aura that closely resemble those of typical migraine. *Table 4* compares the frequency with which various features of a typical migraine visual aura were also present in our 9 cases and the 31 cases from the literature. Regarding the description given of the visual aura (*Table 4*, row a), 68% of patients from the literature and 78% of our cases described patterns of aura which were consistent with the visual aura of typical migraine. This important observation illustrates that the presence of positive visual phenomena, the characteristic build-up and march of scintillating scotoma, does not exclude a structural cerebral lesion as a cause for the aura. Therefore this classic history cannot always be used to make a definitive diagnosis of migraine, and other aspects of the history must be taken into account.

Arteriovenous malformations (AVMs) located in the occipital lobes are rarely able to mimic the complete clinical symptom complex of migraine with aura.^{51,110,114} The visual symptoms of AVMs, however, are usually brief (less than 5 minutes), episodic, and unformed.^{51,109} These elementary visual phenomena are more frequently attributed to the symptom complex of occipital epilepsy and are similar to the visual sensations produced by direct cortical stimulation.¹⁵ Epileptic discharges from cortical area 18 and 19 cause photopsia that remain stationary and flicker rapidly,³² which was a feature of the frequent daily visual phenomena experienced by cases 1, 4, 5 and 6.

There are other reports in the literature of patients with cortical lesions and supposed migraine-like visual aura. However, either the description of the aura did not fit the ICHD⁴³ criteria for migraine or an insufficient description was given

to make a diagnosis of migraine-like aura possible.^{8,17,20,22,29,51,61,70,73,74,80,86,99}

2. Duration of the Visual Aura

The ICHD diagnostic criteria for migraine with aura⁴³ stipulate that the aura symptoms develop gradually over 5 or more minutes and last no more than 60 minutes (*Table 1*). Our experience however suggests that visual aura caused by cerebral lesions cannot be reliably differentiated from migraine on the basis of the duration of the aura. The average length of the visual aura experienced by our cases and those from the literature was 23 and 31.5 minutes, respectively (*Table 4*, row b), excluding three cases with exceptionally long aura.^{16,25,121} In a population-based study of 4000 Danes, 159 experienced migraine with visual aura.⁹⁴ The total duration of the aura was 5–30 minutes in 69%, and no aura lasted less than 5 minutes.

3. Visual Aura Recurring in the Same Hemifield

In migraine the laterality of headache and visual aura are not correlated. A questionnaire-based study of 100 migraineurs failed to identify a correlation between unilateral headaches and the location of visual aura. In fact, visual aura were found to be bilateral more frequently than unilateral.⁹¹ The relationship between the location of migraine visual aura and headache laterality has been reported as predominantly contralateral,^{78,95} ipsilateral,⁸⁷ or variable.^{44,65} In general the location of the visual aura in an individual with typical migraine is likely to vary from one attack to another, but there is no published data on the frequency of exceptions to this rule.

However, unlike typical migraine, every feature of a visual aura caused by a structural cerebral lesion is likely to be highly stereotyped and constant from one episode to another, and this is particularly true of the location of the perceived aura in the visual field. In 100% of our cases and 86% of cases from the literature review (*Table 4*, row c) the aura was repeatedly experienced in same location in the visual field and contralateral to the lesion (*Table 4*, row d). Although a visual aura repeatedly recurring in the same hemifield cannot differentiate between migraine and a cerebral lesion, one which has affected both hemifields, on different occasions, is unlikely to be caused by a cerebral lesion.

4. Past History of Migraine with or without Aura

Length of migraine history—even decades—cannot reliably exclude a non-migrainous cause. Sixty-seven percent of our cases and 55% from the

Table 2
Characteristics of the Nine Case Study Patients

	A1	A2	A3	A4	A5	A6	A7	A8	A9
Age at Presentation	36	34	62	23	24	33	55	51	76
Type of Cerebral Lesion	Occipital cavernous hemangioma	Occipital infarction	Occipital meningioma	Occipital meningioma	Occipital capillary hemangioma	Occipital arteriovenous malformation	Occipital meningioma	Parieto-occipital oligodendroglioma	Occipital cavernous hemangioma
New Onset or Old Aura	Old	New- in pregnancy	Old	New	Old	New	Old	Old	Both
Age at Onset of Aura	20	34	42	23	16	33	53	43	20
Past Hx of Visual Aura (years)	16	—	20	—	8	—	2	8	56
Duration of Aura (minutes)	First aura: 60 Second aura: <1 (star shaped flashes of light)	15	5	First aura: 30 (blurring) Second aura: 2 (repetitive flashes of light)	5-10	35	5-30	2-5	30
Change in Frequency of aura	Increase	Increase with menses	No	Increase	Increase	Increase	Increase	Decrease	Increase
Location of Aura in Visual Field	Right inferior hemifield	Right hemifield	Right hemifield	Left inferior hemifield	Right paracentral scotoma	Left paracentral scotoma	Right superior hemifield	Right hemifield	Left inferior hemiscotoma and hemifield
Aura Recurring in Same Location in the Visual Field	Yes	Yes	Yes	Yes	Yes	Yes	Yes	Yes	Yes
Location of Lesion	Left occipital lobe	Left occipital lobe	Left occipital lobe	Right occipital lobe	Left occipital lobe	Right occipital lobe	Left occipital lobe	Left parieto-occipital lobe	Right occipital lobe
VFD on Perimetry	No	Yes	Yes	Yes	Yes	Yes	Yes	No	—
Pattern of VFD	Normal	Right superior homonymous quadrantanopia	Right homonymous hemianopia	Partial left homonymous quadrantanopia	Right paracentral homonymous scotoma	Left homonymous scotoma	Right central quadrantic homonymous scotoma	Normal	NA
Subjective Persistence of VFD	Yes	Yes	No	Yes	Yes	Yes	No (only after Rx)	No	No
Semiology of Aura (more like migraine or seizure)	Migraine	Migraine	Migraine	Both	Both	Both	Migraine	Both	Both
Headache Associated with Aura	Yes	Yes	Yes	No	Yes	Yes	Yes	Yes	No
Hx of Seizures	One episode of nocturnal	Yes (negative EEG)	No	No	Yes	No	No	Yes	Yes
Aura Responsive to Antimigraine Rx	No	—	—	—	No	No (headache only)	No	—	—
Aura Responsive to Anticonvulsant	Yes	—	—	—	Yes	—	—	—	—

EEG = electroencephalogram; Hx = history; NA = not applicable; Rx = treatment; VFD = visual field defect.

literature had experienced their visual aura for many years (Table 4, row e), with a mean length of aura history of 12.2 and 9.3 years, respectively (Table 4, row f).

B. CLINICAL FEATURES WHICH SHOULD RAISE DOUBTS ABOUT A DIAGNOSIS OF MIGRAINE

1. Migraine-like Visual Aura without Headache

The lifetime prevalence of migraine aura without headache is estimated to be 0.95%⁹² and the disorder affects 5–10% of migraineurs over the age of 40.^{55,94} Twenty-two percent (22%) of cases in our series and 3% of those from the literature had no headache in association with their visual aura (Table 4, row g). Late onset acephalgic visual migraine (migraine aura without headache⁴³) is more likely to be investigated as a transient ischemic attack than as a manifestation of a structural cerebral lesion. The prevalence of acephalgic migraine in the Framingham study was 0.71%, and 42% of subjects had no headache history.¹²⁰ In 77% of subjects these visual aura began for the first time after the age of 50 (mean 56.2 years \pm 18.7), 65% were stereotyped and 69% had experienced 10 or more episodes. There was no increased risk of stroke. Acephalgic migraine is a diagnosis of exclusion and is especially suspicious in those under age 50.

2. Brief Visual Aura Lasting Seconds or Less than 5 Minutes

In distinguishing the visual aura of migraine from that of epilepsy, it is commonly accepted that a visual aura lasting longer than 5 minutes favors migraine, but less than 5 minutes is more characteristic of a seizure-related aura;^{66,84,85} brief flashes of light are especially suggestive of the latter. Two of our cases had a second aura type that met these criteria. Therefore visual aura lasting less than 5 minutes should be investigated.

3. Age Greater than 40, Especially without a Past History of Migraine

Ninety percent of migraine begins before the age of 50; however, it may occur at any age.⁴⁰ Epidemiological studies have shown the prevalence of migraine headache to vary by age, to peak around the age of 40 years, and to decline thereafter in both men and women.⁶² The mean age at presentation in our series and the 31 cases from the literature were 43.8 and 40.5 years respectively (Table 4, row h), whereas the mean age at onset of first visual aura was 31.6 years and 31.3 years (Table 4, row i). The peak incidence of typical migraine with aura is 5 years of age in males

and 12–13 in females.^{106,107} Onset of visual aura for the first time in the fifth and sixth decade is therefore atypical of migraine, even though late life migraine accompaniments are well recognized.³¹ In the Framingham study cohort late onset, first-ever, transient visual phenomena, were found to occur in 1.23% of the study population.¹²⁰ Another study of 659 women aged 40 to 74 years found a 3.8% prevalence of active migraine visual aura,⁶⁷ and although the prevalence of migraine headaches declined with age, at a rate of 50% per decade, the prevalence, duration, and frequency of migraine visual aura were not related to age. Age at the onset of visual aura or length of migraine history cannot reliably exclude a non-migrainous cause for the visual aura.

C. CLINICAL FEATURES WARRANTING NEUROIMAGING

1. Stereotypical Visual Aura

In 100% of our cases and 86% of cases from the literature the aura was highly stereotypical with respect to the visual percept, the duration, and its location within the visual field (Table 4, row c). Importantly, the visual aura was repeatedly experienced in only one hemifield, and this was contralateral to the side of lesion within the cortex (Table 4, row d), as expected. As previously mentioned, in migraine the laterality of visual aura are not consistent and although attacks are similar to one and other, they are seldom identical in every respect.

2. Increase in Frequency or Change in the Pattern of Longstanding Visual Aura

A change, particularly an increase, in the frequency of pre-existing visual aura with or without headache should bring a diagnosis of migraine into question. It is not unusual to find patients whose cerebral lesions were only discovered when there was an increase in frequency of longstanding stereotypical visual aura.^{45,98,110,114} A marked increase in the frequency of longstanding visual aura immediately prior to presentation was present in 67% in our cases and 58% of cases from the literature (Table 4, row j). At the time of presentation, 32% of cases from the literature reported daily visual aura. Unlike epileptic visual phenomena, migraine visual aura rarely occur daily.⁸⁴

3. Sudden Alteration in Aura Characteristics

Just as a patient with a history of a “first or worst” headache has a greater likelihood of harboring an ominous cause for his or her headache, so too is a new visual aura, or one which is distinct from previous or

Table 3

Summary of Published Cases of Patients with Migrainous Visual Aura Secondary to Cerebral Lesions

Type of Cerebral Lesion	Number of Cases	Location of Lesion	Description of Visual Aura	Location of Visual Aura in Visual Field	VFD or Persistence of VFD	Frequency	Duration (minutes)	Increase in Frequency at Time of Presentation	Headache with Aura	Previous Hx Migraine aura	Age at Presentation	Age at Onset of Aura	Presence of Seizure Disorder	Author
Subependymoma	1	Intraventricular	Flickering scotoma, zig-zag fortification	Left hemifield	Not mentioned	1x per week for 3 months	10–180	N	Y	N (3 months)	47	47	Abnormal EEG	Debryne ²⁷
Intracranial calcification	1 (case 2)	Bilateral parieto-occipital	Bilateral scintillating scotoma	Bilateral	Not mentioned	4–6 x/year	Few minutes	N	Y	Y (3 years)	15	12	N	Battistella ⁷
Venous sinus thrombosis	1 (case 2)	Transverse venous sinus	Visual blurring, vertical wavy lines, and teichopsia	Entire visual field	Automated perimetry normal	Sudden onset of frequent episodes	10–30	N	Y	N	52	52	N	Newman ⁷⁴
Metastatic adenocarcinoma	1	Left parietal lobe	Moving colored stars	Right visual field	Not mentioned	3x /week	20	Y	Y	Y (3 months)	44	44	N	Pepin ⁸⁸
Astrocytoma	1	Left temporal	Bilateral amaurosis fugax (few minutes) followed by clouding of vision, scintillating scotoma, and image distortion	Bilateral entire visual field affected	—	—	15	Y (10 month history)	Y (left sided)	N (3 months)	31	31	N (focal theta activity)	Magrotti ⁶³
Un-specified mass	1	Right occipital lobe	Transient flashing blue lights and bright yellow zig-zag patterns	Left visual field	A detailed visual field assessment was normal	1–2x /week	20–60	Y	Y	N	60	60	EEG- asymmetric slowing of activity in right occipital lobe	Verma ¹¹³
Head injury	1	Right occipital lobe	1) Wavy lines moving in lower visual field, 2) scintillating scotoma and 3) flashing lights in temporal visual fields	1) Inferior visual field, 2) Bitemporal visual fields	Not mentioned	1x/ day	30–60	N	Y	N	39	39	N	Husid ⁴²

Meningioma and dural AV shunts	1	Left occipital	Flash of light, crinkling, jagged bars of blue light, positive scotoma with shimmering edges which eventually became	Right inferior homonymous hemiopic scotoma	persistent scotoma at right inferior hemifield	1-2x / week	30	Y	Y	Y (32 years)	47	15	N	Selhorst ⁹⁸
AVM	1 (case 1)	Right occipital lobe	Difficulty reading and kaleidoscope images	Left homonymous hemifield	Normal visual field	2-3x /week	60	N	Y	N	46	46	N (aura improved on anticonvulsants)	Kupersmith ⁵⁰
AVM	1 (case 2)	Right occipital lobe	Flashing light in area of persistent scotoma, one episode of palinopsia	Left inferior visual field	Left inferior partial quadrantanopia on threshold Humphrey perimetry	Episodic over 6/12	30	N	N	N (6 months)	51	51	Y	Kupersmith ⁵⁰
AVM	1 (case 3)	Left occipital lobe	'Flame-like' visual field disturbance, speech disturbance	Right homonymous visual field	Not mentioned	3 over a 1 month period	120	N	Y	N (1 month)	43	43	Speech disturbance responded to anticonvulsants	Kupersmith ⁵⁰
AVM	1 (case 4)	Right occipital lobe	Flashes of multicoloured lights, micropsia, micropsia and metamorphopsia, formed hallucination	Entire left homonymous hemifield	Dense Left superior quadrantanopia	Episodic over 1 year	10-120	N	Y	Y (1 year)	57	56	N	Kupersmith ⁵⁰
AVM	1	Right Occipital lobe	Scintillating bright lights expanding over minutes	Left visual field	Not mentioned	1x/ month	several minutes	N	Y	N	34	34	N	Kurita ⁵²
AVM	1	Right occipital lobe	Flash of light followed by an enlarging white oval scotoma with a crescent of coloured lights	Oval shaped area immediately to left of fixation	Persistent blank visual field defect left of fixation	1x/ 3 weeks	15	Y	Y	N (20 years)	34	14	N	Weiskrantz ¹¹⁴
AVM	1	Right occipital lobe	Colourful, pulsatile expanding scintillating scotoma drifting to right inferiorly followed briefly by a single zig-zag luminescent line.	Left hemifield expanding to centre then tight hemifield, persistent VFD for 5 minutes	No Visual field defect on repeated examinations	1x/day	30	Y	Y	Y (13 years)	20	7	N	Troost ¹¹⁰
AVM	1	Right occipital lobe	Scintillating bright lights moving from centre to periphery	Left visual field	Pre-op visual fields exam not mentioned	1x/day	30	Y	Y	Y (23 years)	38	15	N	Kattah ⁴⁵

(continued on next page)

TABLE 3 (continued)

Type of Cerebral Lesion	Number of Cases	Location of Lesion	Description of Visual Aura	Location of Visual Aura in Visual Field	VFD or Persistence of VFD	Frequency	Duration (minutes)	Increase in Frequency at Time of Presentation	Headache with Aura	Previous Hx Migraine aura	Age at Presentation	Age at Onset of Aura	Presence of Seizure Disorder	Author
AVM	1 (case 1)	Right temporal and occipital lobe	Sudden onset left HH	Left homonymous hemianopia persisted into headache phase with recovery within 1 hour	Not mentioned	Monthly	Less than 1 hour	N	Y	Y (2 years)	19	17	N	Silvestrini ¹⁰¹
AVM	1	Right Occipital lobe	Positive visual scotoma	Right homonymous visual field -	Not mentioned	Frequent / daily	10–15	Y	Y	N	32	32	N	Kowacs ⁴⁸
AVM	1 (case 1)	Left Parietal lobe	Constriction of visual fields, coloured zig-zag lines and blurred vision	Right visual fields	Right inferior quadrantanopia	> 1x per week	10–20	Y	Y	Y (7 years)	33	26	N	Haas ³⁶
AVM	1 (case 2)	Left parieto-occipital lobe	Flashing balls of light	Right homonymous hemifield. Temporary right homonymous hemianopia	No visual field defect	6–12 per month	15–30	Y	Y	N	26	26	N	Haas ³⁶
AVM	1	Left occipito-temporal lobe	Horizontal lack squiggly lines moving slowly downward	Right visual field	Not mentioned	Daily	10–15	Y	Y	Y (25 years)	51	26	N	Spierings ¹⁰⁵
AVM	1	Right occipital lobe	Scintillating scotoma, resolved following surgical treatment	-	Left inferior quadrantanopia	1 per 3–4 weeks	24–48 hours	N, but increased severity	Y	Y (5 years)	59	54	N	Witt Kowsky ¹²¹
AVM	1 (case 7)	Right medial occipital lobe	Scintillating scotomas and multi-coloured kaleidoscope of stereotyped images	Left homonymous visual field	Left inferior homonymous quadrantanopia	1–2 per month	30	N	Y	Y (15 years)	24	9	Y	Bruyn ¹⁷
AVM	1 (case one)	Right occipital lobe	Scintillating scotoma and teicopsia	Right homonymous visual field	Not mentioned	1 per week then 2-3 per week	6	Y	Y	Y (7 years)	53	46	N	Bruyn ¹⁷

Cavernous haemangioma	1	Midbrain	Bilateral blurring of vision and flashing lights during aura and tunnel vision during headache	Scattered throughout the visual field	Not mentioned	3–4 per week	5	Y	Y	N	35	35	N	Malik ⁶⁴
Aneurysm	1	Right middle cerebral artery	Shining scotoma and hemianopia	Hemi-field (side not stated)	Not mentioned	7 per month	2–4 days	Y	Y	Y (20 years)	48	28	N	de Filippis ²⁵
Ischaemic infarction secondary to ICA dissection	1 (case 1)	Left cerebral hemisphere	Homonymous hemianopia	Right homonymous visual field	Not mentioned	Flurry of attacks	30	Y	Y (but not all attacks)	N	40	40	N	Olesen ⁷⁹
Ischaemic infarction secondary to ICA dissection	1 (case 2)	Right cerebral hemisphere	Hazy vision with flickering spots and occasional zigzag lines	Left visual field	Not mentioned	Daily	15	Y	Y	Y (20 years)	42	22	N	Olesen ⁷⁹
Ischaemic infarction secondary to ICA occlusion	1 (case 3)	Right Middle cerebral artery territory	Flickering scotoma	Left visual field. Subjective Left homonymous hemianopia	Not mentioned	Daily	30	Y	Y	Y (35 years)	50	15	N	Olesen ⁷⁹
Spreading hypoperfusion on IC angiography	1 (case 9)	Right and Left cerebral hemispheres	Flickering zigzag lines (left hemifield), luminescent black rings (right hemifield)	Homonymous visual field	Not mentioned	Frequent	10–15	Y	Y	Y (23 years)	37	14	N	Olesen ⁷⁹
Abscess	1	Left Occipital lobe	Scintillating scotoma, fortification spectra and scotoma	—	Right homonymous hemianopia	Every 2 weeks	> 72 hours	Y (headache and aura lasting longer)	Y	Y (37 years)	51	14	N	Bruera ¹⁶

AVM = arteriovenous malformation; Hx = history; N = No; VFD = visual field defect; x/ = number of times per; Y = yes.

Table 4

Frequency with which Various Features of a Typical Migraine Visual Aura Were Also Present in the Reported Cases

	Features of Migrainous Visual Aura	Migraine with Aura	Our Cases (n = 9)	Cases from Literature Review (n = 31)
a	Description of visual aura fits with “classic” / typical migraine	100%	7 (78%)	21 (68%)
b	Mean duration of the visual aura (minutes)	27 (range 5–60) ⁴³	22.6 (range 5–60)	31.5 (range 5–120)
c	Teichopsia always recurring in same location in the visual field	Variable ~ 50%	9 (100%)	29 (86%)
d	Location of aura in visual field in relation to the location of lesion in cortex	NA	9 (100%) contralateral	<ul style="list-style-type: none"> • 19/23 (82%) contralateral • 2/23 (9%) ipsilateral • 2/23 (9%) ipsilateral
e	Past history of migraine ± aura	18% = life time prevalence ⁹⁶	67% (6 of 9)	55% (17 of 31)
f	Past history of visual aura (years)	6% = life time prevalence of long aura history ^{94,96}	12.2	9.3
g	Migraine aura without headache/ acephalgic migraine	5–10% prevalence in migraineurs over 40 years ^{94,95} Population prevalence = 0.71% ¹²⁰ to 0.95% ⁹²	2 (22%)	1 (3%)
h	Mean age at presentation of migraine ± aura	Bimodal peak prevalence: 14–16 and 40 years ⁶²	43.8 (range 23–76)	40.5 (range 15–60)
i	Mean age at onset of first migraine-like aura	5–13 = peak incidence of migraine aura ^{106,107}	31.6 (range 16–53)	31.3 (range 7–60)
j	Increase in frequency of visual aura [in those with past history of aura]	1.5/ month 10% have weekly attacks ¹⁰⁶	7 (78%) [4/6 (67%)]	19 (61%) [11/19 (58%)]
k	Sudden alteration in aura characteristics	An individual typically experiences one or more stereotyped aura, with minor variations, alternating between them	8 (89%) experienced a completely new visual aura instead of or as well as established aura	—
l	Visual field defect	Rarely with migraine-related ischemic CVA	6/8 (75%)	8/13 (61.5%)
m	Subjective awareness of persistent scotoma following aura	Rarely with migraine-related ischemic CVA	5/9 (56%)	2/13 (15.4%)

CVA = cerebrovascular accident.

longstanding aura, more likely to have a more serious underlying cause. Eighty-nine percent of our cases (Table 4, row k) experienced a notable change in one or more features of their aura, which then remained altered thereafter. An aura occurring without headache when previously associated with headache, an aura persisting throughout or beyond the headache, or any significant new features warrant closer scrutiny.

4. Any Unexplained Visual Field Defect and/ or Subjective Persistence of a Scotoma Following a Typical Visual Aura

Homonymous visual field defects (VFDs) that occur as part of the typical migraine syndrome, are almost always transient, but occasionally persist.⁴⁰ The patient with a permanent defect has usually experienced recurrent, transient scintillating scotoma in the same

region of the visual space before the permanent event occurs. These transient episodes often occur in a crescendo fashion, become more frequent, and last progressively longer, over the preceding days to weeks.

Visual field testing revealed a homonymous VFD in 75% (6/8) of our patients (Table 2) and 61.5% (8/13) of cases from the literature (Table 4, row l) where information regarding the visual field was provided. Assessment of the visual field is thus a very useful investigative tool where there are atypical features associated with visual aura. Any unexplained VFD, even unilateral, must be further investigated.

A normal visual field test, however, does not exclude the possibility of a space occupying lesion. Two patients in our series had a normal visual fields using both Humphrey and Goldmann perimetry. In case 1, where the lesion was a cavernoma, this might be expected, since this is a developmental anomaly and therefore present at the time of cortical development. The visual cortex presumably developed surrounding the cavernoma, hence retaining its normal spatial organization. It is, however, the case that cavernomas do increase in size due to recurrent hemorrhage and do commonly give rise to homonymous VFDs when located in the occipital lobe. In case 8 a parieto-occipital oligodendroglioma was located rostral to the visual cortex in the precuneus. This suggests that the visual aura experienced by the patient was not caused by the physical presence of the lesion, rather by the spread of neuronal depolarization into the visual cortex.

Patients are likely to seek medical attention for the first time when a visual field disturbance or defect fails to fully resolve in the usual manner following an aura.³⁷ Such visual field disturbances are typically negative visual phenomena, and 56% (5/9) of our patients experienced a subjective persistence of their scotoma following a typical visual aura. A recent study highlighted the phenomenon of “persistent darkening or dimming” of a homonymous region of the visual field, common also following occipital seizures.⁴⁹ A prolonged yet temporary suppression of the visual field was a prominent feature in all of our patients except case 3, and corresponded to a homonymous hemianopia or scotoma developing at the time of the aura. Following repeated attacks, in all but three patients, the area of suppression became a permanent and symptomatic VFD (Table 4, row m). In case 3 an incidental right homonymous hemianopia was found in the same location where she had consistently experienced her visual aura for 20 years.

A cortical lesion may give rise to a VFD because of local damage caused by the lesion, because of an acute event such as an infarct or haemorrhage, or because the visual aura may itself cause a temporary VFD by a mechanism perhaps similar to that seen in

Todd's post-ictal paresis,¹⁴ thought to be due to “depletion or active inhibition” of neurons.¹⁰ In fact, human studies using neuroimaging techniques^{2,5,57,122} and high field strength functional MRI^{23,37,97,119} strongly support the theory that visual aura are generated by a wave of neuronal excitation spreading across the visual cortex at a constant speed, leaving behind a transient neuronal depression that produces a temporary scotoma. In one study the slowly propagating neurovascular changes in the visual cortex of the patient occurred simultaneously with the experience of the visual aura.³⁷

5. Co-existence of Seizures

Five of our nine cases (59%) experienced at least one seizure, and in two the visual aura responded to anticonvulsant therapy (Table 2). The patient in case 1 experienced a single nocturnal seizure; in case 5 the patient developed two exercise-induced generalized convulsions preceded by his usual visual aura and in case 8 right-sided weakness, twitching, and paraesthesia, followed his typical visual aura. Both patients in cases 5 and 8 had experienced their visual aura for many years prior to the onset of seizures. At the time of her presumed seizures, the patient in case 2 did not exhibit motor convulsions but lost consciousness associated with straightening of her limbs. Clouding of consciousness, faintness, and syncope are uncommon in migraine.⁶ Severe brain stem symptoms in migraine may be associated with fainting or loss of consciousness, attributed to basilar artery constriction causing brain stem ischaemia.⁹ Two of the 31 patients (6.5%) from the literature review experienced seizures,⁵⁰ three others (9.7%) had an abnormal electroencephalogram (EEG),^{27,113} and one patient experienced a reduction in the frequency of visual aura after receiving anticonvulsant therapy,⁵⁰ as with the patient in case 1.

VI. Visual Aura: Migraine or Epilepsy?

The relationship between migraine and epilepsy has been debated for more than 100 years.^{1,66} Both are chronic neurological disorders with episodic and overlapping clinical manifestations, characterized by recurrent attacks of central nervous system dysfunction. The biological abnormality in these disorders is sufficiently mild that patients are phenotypically normal between attacks, and factors such as fatigue, stress, exercise, and certain foods can precipitate attacks.⁹⁰ Both conditions can present with headache, and there is also considerable co-morbidity which adds to the complexity of diagnosis. Epidemiological studies indicate an association of migraine

and epilepsy, with an increase in prevalence of migraine in patients with epilepsy, and *visa versa*.¹

Each disorder appears to be able to trigger and mimic the other. The distinctive features of migraine have been found in several pediatric epilepsy syndromes.^{4,18,30,33,46} The strong influence of migraine on children with epilepsy may be caused by the greater frequency of occipital lobe epileptogenic abnormalities in this age group.⁷⁸ Seizure-related visual aura develop more rapidly, within seconds, and appear in the peripheral visual field. As the seizure progresses, the aura moves horizontally across the visual field to the contralateral side. By these criteria the pattern of visual aura in all except case 2, who experienced flashes of light, is more in keeping with migraine than epilepsy; even when preceding a seizure.

An event that begins with an epileptiform discharge can sometimes terminate in cortical spreading depression (CSD), the electrophysiological correlate of the visual aura.¹⁰³ Although the occipital seizure-migraine sequence is more common, migraine aura can also trigger seizures, producing a condition referred to as “migrain epilepsy,”^{1,66} as with the patients in cases 2 and 5, whose visual aura immediately preceded the onset of the seizure activity. The EEG is usually unhelpful in distinguishing between migrainous and epileptic visual aura.¹

A study comparing the visual phenomena of patients with migraine and occipital epilepsy described those of epileptic seizures as predominantly colored and circular patterns as opposed to the black-and-white linear patterns of migraine;⁸³ although color is also frequently reported in migraine aura.⁹⁴ An explanation may be that migraine visual aura are generated by activation of orientation specific cells within ocular dominance columns in the primary visual cortex.³⁸ These cells are rich in cytochrome oxidase and are contained in regions known as interblobs, involved in the processing of shape or form. Interblobs respond best to gratings with high spatial frequencies and fine detail and are thought to be the region where migraine visual aura arise. In contrast, interblobs separate areas known as blobs that are responsible for processing color, low spatial contrast and frequency;³⁹ epileptic visual aura may be generated within blobs. The differences in the metabolic activities of these two regions may play a role in the type of aura generated.

VII. Cortical Hyperexcitability: A Shared Pathophysiology and Unifying Theory?

Alterations in cortical blood flow are no longer regarded as the primary etiology of migraine, but are

secondary to changes in neuronal activity, so-called “vasoneuronal coupling.”⁵⁶ Migraine, like epilepsy, is now considered to be a disorder of neuronal hyperexcitability¹¹⁸ or an expression of disturbed cortical activity.¹¹² It is no surprise then that both inherited and acquired brain diseases are the most important risk factor for the comorbidity of epilepsy and migraine.⁸² Disorders which alter the state of neuronal excitability, whether inherited or acquired, increase the brain’s susceptibility to CSD by lowering the threshold for spontaneous neuronal depolarization.^{3,21,118} This is clinically manifest as visual phenomena, headache, seizures, and so forth, when the individual is subjected to internal or external triggers (Fig. 1).

There are several lines of evidence, outlined in A-E below, supporting the hypothesis that neuronal hyperexcitability plays an important role in the pathogenesis and clinical manifestations of migraine, epilepsy, and other cortical diseases.

A. FUNCTIONALLY HYPEREXCITABLE “INTER-ICTAL” VISUAL CORTEX IN PATIENTS WITH MIGRAINE AND EPILEPSY

Using transcranial magnetic stimulation, the threshold level of stimulus required to evoke phosphenes (the experience of light with nonluminous stimulation) in patients with migraine was demonstrated to be significantly lower than in control subjects.^{72,111} Similarly, anticonvulsants were shown to reduce cortical excitability in idiopathic epilepsy, as assessed by magnetic stimulation of the motor cortex;⁹³ a possible mechanism of action of anticonvulsant therapy. Establishing the patho-aetiology of hyperexcitability, whether due to excessive excitation or defective inhibition, the latter being the more plausible in migraine, has important implications for the development of therapeutic strategies.²¹

B. PHYSIOLOGICAL BASIS FOR CORTICAL HYPEREXCITABILITY IN PATIENTS WITH MIGRAINE

Calcium dysregulation,⁸¹ abnormal concentrations of GABA,¹¹⁷ magnesium,¹¹⁶ glutamate,^{24,118} nitric oxide,⁷⁷ potassium,¹¹⁸ hydrogen and abnormalities in arachidonic acid, prostaglandin, and mitochondrial oxidative phosphorylation¹¹⁶ have all been implicated in the pathogenesis of migraine. CSD can also be induced by elevated extracellular potassium, glutamate, and inhibition of Na⁺/K⁺ adenosine triphosphatase.³⁵ Failure to maintain homeostasis within the extracellular neuronal microenvironment,¹⁰² due to any inherited or acquired disorder, can result in abnormal ion distributions that lower the threshold and increase

susceptibility to the initiation of CSD; which is clinically manifest as seizures or visual aura.

C. PROVEN EFFICACY OF MIGRAINE PROPHYLACTIC AGENTS

Calcium channel blockers and anticonvulsants, such as sodium valproate, gabapentin, and topiramate, can alter the properties of ion channels and thus stabilise cell membrane excitability.¹¹⁵ In fact, centrally acting GABA-agonists such as sodium valproate have been shown to reduce the frequency of migraine attacks by up to 50 % in double-blind trials⁴⁷ and to lower cortical excitability in patients with migraine.^{13,71} In case one sodium valproate was able to reduce the frequency of the patient's visual aura and headache to almost nil. This response is considerably better than would be expected in migraine.

D. DISORDERS OF NEURONAL MEMBRANE EXCITABILITY CAUSED BY MUTATIONS OF ION CHANNELS

Molecular characterization of disorders such as familial hemiplegic migraine (FHM), a rare autosomal dominant subtype of migraine, have identified mutations of ion channel proteins.^{26,28,81} FHM is a "channelopathy," one of a family of episodic disorders characterized by defect in ion channels, ultimately resulting in membrane hyperexcitability and thus increasing susceptibility to CSD. So far, mutation in genes regulating a brain specific calcium channel,⁸¹

encoding a Na⁺, K⁺-ATPase,²⁶ and a neuronal sodium channel²⁸ have been identified in pedigrees with this disease, many of whom also have seizures. Different types of epilepsy have similarly been associated with mutation in genes encoding subunits of Na and K channels;⁶⁸ substantiating the molecular links between migraine and epilepsy, and the notion that they are both fundamentally disorders of altered neuronal excitability.

E. NEURONAL HYPEREXCITABILITY AND CSD INDUCED BY ACQUIRED CORTICAL LESIONS

Ischemic injury to the human brain has been shown to generate "spontaneous" waves that propagate through the penumbra of cortical infarcts or traumatized cortex into normally perfused tissue, where they take on the characteristic features of CSD.¹⁰⁸ Seizures induced by brain injury may be caused by a similar mechanism. The co-existence of migraine and stroke in the disorders MELAS¹¹⁶ (mitochondrial encephalomyopathy, with lactic acidosis and stroke-like episodes) and CADASIL¹⁹ (cerebral autosomal dominant arteriopathy with subcortical infarction and leucoencephalopathy) also suggest a common pathogenic mechanism.

Transient hypoxic ischemic events alone can, without requisite tissue injury, induce CSD. A recent study demonstrated that microemboli injected into the carotid artery triggered hypoperfusion and CSD in rodent brain often without causing microinfarction.⁷⁶ The authors postulate that paradoxical embolization may link cardiac right-to-left shunts to migraine aura and that a subset of migraine aura may belong to a spectrum of hypoperfusion disorders along with transient ischemic attacks and silent infarcts.

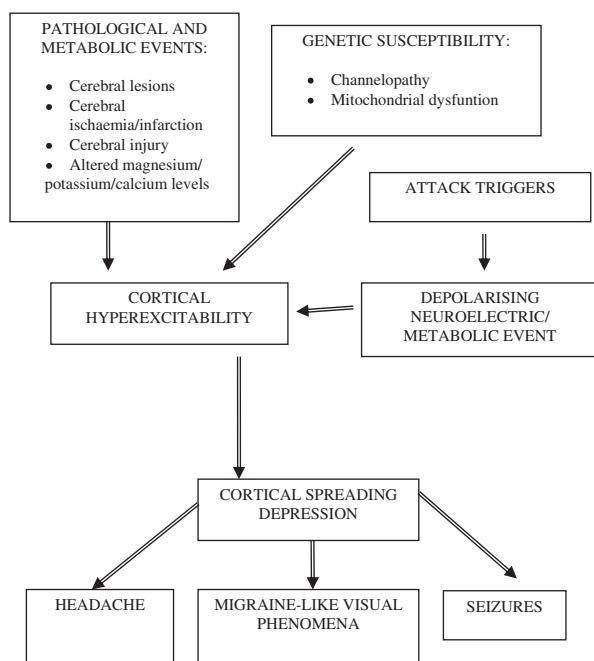


Fig. 1. Schematic flow diagram illustrating the sequence of events culminating in the generation of migraine-like visual aura and seizure related visual phenomena.

VIII. Conclusion

We hypothesize that, when structural lesions produce visual symptoms with the semiology of migraine, they share a common pathophysiology: namely, a state of neuronal hyperexcitability. Whether due to a genetic predisposition, acquired through brain injury, ionic dysregulation, or a structural lesion, a state of neuronal hyperexcitability is thought to increase susceptibility to the generation of CSD, the electrophysiological correlate of the visual aura in migraine. The propagation of spreading depression through the visual cortex will create similar visual phenomena whatever the cause, but focusing on the details of the clinical history and associated features may assist in predicting those rare cases that are associated with an underlying structural lesion. Based on the 40 cases reviewed here, we have outlined the most significant

Table 5

Clinical Features Differentiating the Visual Aura of Migraine from those of Structural Cortical Lesions

-
- 1) Clinical features which cannot reliably differentiate the visual aura of migraine from those due to structural lesions:
 - ▶ The presence of scintillating scotoma
 - ▶ Duration of visual aura
 - ▶ Visual aura recurring in the same hemifield
 - ▶ Previous history of migraine with or without aura
 - 2) Clinical features which should raise doubts about a diagnosis of idiopathic migraine:
 - ▶ Absence of headache, especially if less than 50 years old
 - ▶ Brief visual aura lasting seconds or less than 5 minutes
 - ▶ Age greater than 40, especially without a past history of migraine
 - 3) Clinical features warranting neuroimaging are:
 - ▶ Stereotypical visual aura
 - ▶ Increase in frequency of visual aura
 - ▶ Change in the pattern or characteristics of longstanding visual aura
 - ▶ Any unexplained visual field defect
 - ▶ Negative visual phenomena/subjective persistence of a scotoma following a typical visual aura
-

clinical features differentiating the visual aura of migraine from those of structural cortical lesions; these are summarized in Table 5. We wish to caution, however, that despite the guidance these cases provide, not all patients with conditions causing migraine-like visual phenomena can be correctly diagnosed using clinical criteria alone.

Neuronal hyperexcitability can explain the comorbidity of disorders such as migraine, epilepsy, and acquired brain lesions, the overlap in clinical features, especially visual aura, and can account for the response to therapeutic agents aimed at restoring neuronal ionic homeostasis. Neuronal hyperexcitability also clarifies why these disorders are so strongly influenced by both environmental factors and genetic make-up. Therapeutic strategies aimed at reducing neuronal hyperactivity and normalizing the neuronal microenvironment may prove to be the most effective in the management of these chronic neurological disorders.

IX. Method of Literature Search

References for the literature review were identified by conducting a Medline search using the PubMed database (National Library of Medicine) and EMBASE search using OVID (Walters Kluwer) from 1950 until December 2009 with the terms *migraine visual aura*, *cerebral lesions*, *visual hallucinations*, *occipital lobe epilepsy*, and *epileptic aura*. Articles were also identified through citations in related articles and neuro-ophthalmic textbooks, in particular Walsh & Hoyt's *Clinical Neuro-Ophthalmology*⁴⁰ and *Ophthalmic Literature* (1947–1998). Only articles published in the English language were reviewed. All case reports of patients with migrainous visual aura secondary to cerebral lesions were systematically and critically reviewed to ensure only those

fulfilling the ICHD⁴³ criteria for migraine with aura were included. Cases not fulfilling these criteria have been cited separately for completeness. In addition to the terms given earlier, the following search words were used for the literature review on the pathogenesis of migraine-like visual aura: *migraine pathogenesis*, *co-morbidity of migraine and epilepsy*, *neuronal hyperexcitability*, *cortical spreading depression*, *functional neuroimaging*, *migraine genetics*, *transcranial magnetic stimulation*.

X. Disclosure

The authors reported no proprietary or commercial interest in any product mentioned or concept discussed in this article.

References

1. Andermann FA. Migraine and epilepsy: an overview, in Andermann FA, Lugaresi E (eds) *Migraine and epilepsy*. Boston, Butterworths, 1987, pp 281–91
2. Andersen AR, Friberg L, Olsen TS, et al. Delayed hyperemia following hypoperfusion in classic migraine. Single photon emission computed tomographic demonstration. *Arch Neurol*. 1988;45(2):154–9
3. Aurora SK, Ahmad BK, Welch KM, et al. Transcranial magnetic stimulation confirms hyperexcitability of occipital cortex in migraine. *Neurology*. 1998;50(4):1111–4
4. Baier KW, Doose H. Migraine and petit mal absence: familial prevalence of migraine and seizures, in Andermann FA, Lugaresi E (eds) *Migraine and epilepsy*. Boston, Butterworths, 1987, pp 293–311
5. Barkley GL, Tepley N, Simkins R, et al. Neuromagnetic fields in migraine: preliminary findings. *Cephalalgia*. 1990; 10(4):171–6
6. Barolin GS. Migraines and epilepsies—a relationship? *Epilepsia*. 1966;7(1):53–66
7. Battistella PA, Mattesi P, Casara GL, et al. Bilateral cerebral occipital calcifications and migraine-like headache. *Cephalalgia*. 1987;7(2):125–9
8. Beekman R, Nijssen PC, van Rooij WJ, et al. Migraine with aura after intracranial endovascular procedures. *Headache*. 2001;41(4):410–3

9. Bickerstaff ER. Impairment of consciousness in migraine. *Lancet*. 1961;2:1057-9
10. Binder DK. A history of Todd and his paralysis. *Neurosurgery*. 2004;54(2):480-6, discussion 6-7.
11. Blau JN. Classical migraine: symptoms between visual aura and headache onset. *Lancet*. 1992;340(8815):355-6
12. Bolay H, Reuter U, Dunn AK, et al. Intrinsic brain activity triggers trigeminal meningeal afferents in a migraine model. *Nat Med*. 2002;8(2):136-42
13. Bowyer SM, Mason KM, Moran JE, et al. Cortical hyperexcitability in migraine patients before and after sodium valproate treatment. *J Clin Neurophysiol*. 2005;22(1):65-7
14. Bravais LF. Recherches sur les symptômes et le traitement de l'épilepsie hémiplégique. Paris, Faculté de Médecine de Paris, 1827
15. Brindley GS, Lewin WS. The sensations produced by electrical stimulation of the visual cortex. *J Physiol*. 1968;196(2):479-93
16. Bruera OC, Lourdes Figuerola M, Gandolfo C, et al. Status migrainosus: an unusual presentation of a brain abscess. *Headache*. 1999;39(1):55-7
17. Bruyn GW. Intracranial arteriovenous malformation and migraine. *Cephalalgia*. 1984;4(3):191-207
18. Camfield PR, Metrakos K, Andermann F. Basilar migraine, seizures, and severe epileptiform EEG abnormalities. *Neurology*. 1978;28(6):584-8
19. Chabriat H, Vahedi K, Iba-Zizen MT, et al. Clinical spectrum of CADASIL: a study of 7 families. Cerebral autosomal dominant arteriopathy with subcortical infarcts and leukoencephalopathy. *Lancet*. 1995;346(8980):934-9
20. Chen JS, Ilsen PF. Parieto-occipital arteriovenous malformation. *Optometry*. 2002;73(8):477-91
21. Chronicle EP, Mulleners WM. Visual system dysfunction in migraine: a review of clinical and psychophysical findings. *Cephalalgia*. 1996;16(8):525-35, discussion 3.
22. Cushing H, Bailey P. Tumours Arising from the Blood Vessels of the Brain: Angiomatous Malformations and Hemangioblastomas. Vol. 3. Springfield, Charles C Thomas, 1928, p 219.
23. Cutrer FM, Sorensen AG, Weisskoff RM, et al. Perfusion-weighted imaging defects during spontaneous migrainous aura. *Ann Neurol*. 1998;43(1):25-31
24. D'Andrea G, Cananzi AR, Joseph R, et al. Platelet glycine, glutamate and aspartate in primary headache. *Cephalalgia*. 1991;11(4):197-200
25. de Filippis S, Salvatori E, Bozzao A, et al. Migraine with aura, bipolar depression, ACM aneurysm. A case report. *J Headache Pain*. 2005;6(2):93-6
26. De Fusco M, Marconi R, Silvestri L, et al. Haploinsufficiency of ATP1A2 encoding the Na⁺/K⁺ pump alpha2 subunit associated with familial hemiplegic migraine type 2. *Nat Genet*. 2003;33(2):192-6
27. Debruyne J, Crevits L, Vander Eecken H. Migraine-like headache in intraventricular tumours. *Clin Neurol Neurosurg*. 1982;84(1):51-7
28. Dichgans M, Freilinger T, Eckstein G, et al. Mutation in the neuronal voltage-gated sodium channel SCN1A in familial hemiplegic migraine. *Lancet*. 2005;366(9483):371-7
29. Donin JF, Keane JR. Migraine, pseudotumor cerebri, blindness and death. Paper presented at the 13th Annual Frank B Walsh Society Meeting. Houston, TX, 1981
30. Dvorkin GS, Andermann FA, Carpenter S. Classical migraine, intractable epilepsy and multiple strokes: a syndrome related to mitochondrial encephalomyopathy, in Andermann FA, Lugaresi E (eds) *Migraine and epilepsy*. Boston, Butterworths, 1987, pp 203-32
31. Fisher CM. Late-life migraine accompaniments as a cause of unexplained transient ischemic attacks. *Can J Neurol Sci*. 1980;7(1):9-17
32. Gassel MM. Occipital lobe syndromes (excluding hemianopia), in Vinken PJ, Bruyn GS (eds) *Handbook of Clinical Neurology*. Amsterdam, North-Holland Publishing Co, 1969, pp 640-79
33. Gastaut H. A new type of epilepsy: benign partial epilepsy of childhood with occipital spike-waves. *Clin Electroencephalogr*. 1982;13(1):13-22
34. Goadsby PJ, Zagami AS, Lambert GA. Neural processing of craniovascular pain: a synthesis of the central structures involved in migraine. *Headache*. 1991;31(6):365-71
35. Grafstein B. Mechanism of spreading cortical depression. *J Neurophysiol*. 1956;19(2):154-71
36. Haas DC. Arteriovenous malformations and migraine: case reports and an analysis of the relationship. *Headache*. 1991;31(8):509-13
37. Hadjikhani N, Sanchez Del Rio M, Wu O, et al. Mechanisms of migraine aura revealed by functional MRI in human visual cortex. *Proc Natl Acad Sci USA*. 2001;98(8):4687-92
38. Hubel DH, Wiesel TN. Sequence regularity and geometry of orientation columns in the monkey striate cortex. *J Comp Neurol*. 1974;158(3):267-305
39. Hubel DH, Livingstone MS. Segregation of form, color, and stereopsis in primate area 18. *J Neurosci*. 1987;7(11):3378-415
40. Hupp SL. Migraine, in Miller NR, Newman NJ, Biousse V, et al (eds) *Walsh & Hoyt's Clinical Neuro-ophthalmology*. Philadelphia, PA, Lippincott Williams & Wilkins, 6th edition 2004, pp 3657-723
41. Hupp SL, Kline LB, Corbett JJ. Visual disturbances of migraine. *Surv Ophthalmol*. 1989;33(4):221-36
42. Husid MS. New onset migraine with aura following head injury: a case report. *Headache*. 2004;44(10):1048-50
43. IHS. The international classification of headache disorders: 2nd edition. *Cephalalgia*. 2004;24(1):1-160
44. Jensen K, Tfelt-Hansen P, Lauritzen M, et al. Classic migraine. A prospective recording of symptoms. *Acta Neurol Scand*. 1986;73(4):359-62
45. Kattah JCL, A.J. Resolution of classic migraine after removal of an occipital lobe AVM. *Ann Neurol*. 1980;7(1):93
46. Kinast M, Lueders H, Rothner AD, et al. Benign focal epileptiform discharges in childhood migraine (BFEDC). *Neurology*. 1982;32(11):1309-11
47. Klapper J. Divalproex sodium in migraine prophylaxis: a dose-controlled study. *Cephalalgia*. 1997;17(2):103-8
48. Kowacs PA, Werneck LC. Atenolol prophylaxis in migraine secondary to an arteriovenous malformation. *Headache*. 1996;36(10):625-7
49. Kun Lee S, Young Lee S, Kim DW, et al. Occipital lobe epilepsy: clinical characteristics, surgical outcome, and role of diagnostic modalities. *Epilepsia*. 2005;46(5):688-95
50. Kupersmith MJ, Berenstein A, Nelson PK, et al. Visual symptoms with dural arteriovenous malformations draining into occipital veins. *Neurology*. 1999;52(1):156-62
51. Kupersmith MJ, Vargas ME, Yashar A, et al. Occipital arteriovenous malformations: visual disturbances and presentation. *Neurology*. 1996;46(4):953-7
52. Kurita H, Shin M, Kirino T. Resolution of migraine with aura caused by an occipital arteriovenous malformation. *Arch Neurol*. 2000;57(8):1219-20
53. Lashley KS. Patterns of cerebral integration indicated by the scotomas of migraine. *Arch Neurol Psychiat*. 1941;46:331-9
54. Lashley KS. Patterns of cerebral integration indicated by the scotomas of migraine. *Arch Neurol Psychiat*. 1941;46:331-9
55. Launer LJ, Terwindt GM, Ferrari MD. The prevalence and characteristics of migraine in a population-based cohort: the GEM study. *Neurology*. 1999;53(3):537-42
56. Lauritzen M. Pathophysiology of the migraine aura. The spreading depression theory. *Brain*. 1994;117(Pt 1):199-210
57. Lauritzen M, Olesen J. Regional cerebral blood flow during migraine attacks by Xenon-133 inhalation and emission tomography. *Brain*. 1984;107(Pt 2):447-61
58. Leao AAP. Spreading depression of activity in cerebral cortex. *J Neurophysiol*. 1944;7:359-90

59. Leao AAP. Pial circulation and spreading depression of activity in the cerebral cortex. *J Neurophysiol.* 1944;7:391–6
60. Leao AAP. Propagation of spreading cortical depression. *J Neurophysiol.* 1945;8:33–46
61. Lees F. The migrainous symptoms of cerebral angiomas. *J Neurol Neurosurg Psychiatry.* 1962;25:45–50
62. Lipton RB, Stewart WF, Diamond S, et al. Prevalence and burden of migraine in the United States: data from the American Migraine Study II. *Headache.* 2001;41(7):646–57
63. Magrotti E, Frascaroli G, Mariani G. Left temporal glioma presenting as migraine with typical aura. *Ital J Neurol Sci.* 1992;13(5):444
64. Malik SN, Young WB. Midbrain cavernous malformation causing migraine-like headache. *Cephalalgia.* 2006;26(8):1016–9
65. Manzoni GC, Farina S, Lanfranchi M, et al. Classic migraine—clinical findings in 164 patients. *Eur Neurol.* 1985;24(3):163–9
66. Marks DA, Ehrenberg BL. Migraine-related seizures in adults with epilepsy, with EEG correlation. *Neurology.* 1993;43(12):2476–83
67. Mattsson P, Svardsudd K, Lundberg PO, et al. The prevalence of migraine in women aged 40–74 years: a population-based study. *Cephalalgia.* 2000;20(10):893–9
68. McCormick DA, Contreras D. On the cellular and network bases of epileptic seizures. *Annu Rev Physiol.* 2001;63:815–46
69. Milner PM. Note on a possible correspondence between the scotomas of migraine and spreading depression of Leao. *Electroencephalogr Clin Neurophysiol.* 1958;10(4):705
70. Monteiro ML, Hoyt WF, Imes RK. Puerperal cerebral blindness. Transient bilateral occipital involvement from presumed cerebral venous thrombosis. *Arch Neurol.* 1984;41(12):1300–1
71. Mulleners WM, Chronicle EP, Vredevelde JW, et al. Visual cortex excitability in migraine before and after valproate prophylaxis: a pilot study using TMS. *Eur J Neurol.* 2002;9(1):35–40
72. Mulleners WM, Chronicle EP, Palmer JE, et al. Visual cortex excitability in migraine with and without aura. *Headache.* 2001;41(6):565–72
73. Nagata S, Morioka T, Natori Y, et al. Surgical treatment of non-ruptured giant occipital arteriovenous malformations with frequent migraine-like headache. *Neurol Med Chir (Tokyo).* 2006;46(9):441–5
74. Newman DS, Levine SR, Curtis VL, et al. Migraine-like visual phenomena associated with cerebral venous thrombosis. *Headache.* 1989;29(2):82–5
75. Niedermeyer E. *Epilepsy and migraine, in The epilepsies. Diagnosis and Management.* Boston, Urban and Schwarzenberg, 1990
76. Nozari A, Dilekoz E, Sukhotinsky I, et al. Microemboli may link spreading depression, migraine aura, and patent foramen ovale. *Ann Neurol.* 2010;67(2):221–9
77. Olesen J, Thomsen LL, Lassen LH, et al. The nitric oxide hypothesis of migraine and other vascular headaches. *Cephalalgia.* 1995;15(2):94–100
78. Olesen J, Friberg L, Olsen TS, et al. Timing and topography of cerebral blood flow, aura, and headache during migraine attacks. *Ann Neurol.* 1990;28(6):791–8
79. Olesen J, Friberg L, Olsen TS, et al. Ischaemia-induced (symptomatic) migraine attacks may be more frequent than migraine-induced ischaemic insults. *Brain.* 1993;116(Pt 1):187–202
80. Olivecrona H. AV aneurysms of the brain. *Acta Neurol Psychiatr.* 1948;59:567–602
81. Ophoff RA, Terwindt GM, Vergouwe MN, et al. Familial hemiplegic migraine and episodic ataxia type-2 are caused by mutations in the Ca²⁺ channel gene CACNL1A4. *Cell.* 1996;87(3):543–52
82. Ottman R, Lipton RB. Comorbidity of migraine and epilepsy. *Neurology.* 1994;44(11):2105–10
83. Panayiotopoulos CP. Elementary visual hallucinations in migraine and epilepsy. *J Neurol Neurosurg Psychiatry.* 1994;57(11):1371–4
84. Panayiotopoulos CP. Visual phenomena and headache in occipital epilepsy: a review, a systematic study and differentiation from migraine. *Epileptic Disord.* 1999;1(4):205–16
85. Panayiotopoulos CP. Elementary visual hallucinations, blindness, and headache in idiopathic occipital epilepsy: differentiation from migraine. *J Neurol Neurosurg Psychiatry.* 1999;66(4):536–40
86. Park-Matsumoto YC, Tazawa T, Shimizu J. Migraine with aura-like headache associated with moyamoya disease. *Acta Neurol Scand.* 1999;100(2):119–21
87. Peatfield RC, Gawel MJ, Rose FC. Asymmetry of the aura and pain in migraine. *J Neurol Neurosurg Psychiatry.* 1981;44(9):846–8
88. Pepin EP. Cerebral metastasis presenting as migraine with aura. *Lancet.* 1990;14(336(8707)):127–8
89. Plant GT. The fortification spectra of migraine. *Br Med J.* 1986;293(6562):1613–7
90. Ptacek LJ. The place of migraine as a channelopathy. *Curr Opin Neurol.* 1998;11(3):217–26
91. Queiroz L, Rapoport AM, Weeks RE, et al. Characteristics of migraine visual aura. *Headache.* 1997;37(3):137–41
92. Rasmussen BK, Jensen R, Olesen J. A population-based analysis of the diagnostic criteria of the International Headache Society. *Cephalalgia.* 1991;11(3):129–34
93. Reutens DC, Berkovic SF, Macdonell RA, et al. Magnetic stimulation of the brain in generalized epilepsy: reversal of cortical hyperexcitability by anticonvulsants. *Ann Neurol.* 1993;34(3):351–5
94. Russell MB, Olesen J. A nosographic analysis of the migraine aura in a general population. *Brain.* 1996;119(Pt 2):355–61
95. Russell MB, Iversen HK, Olesen J. Improved description of the migraine aura by a diagnostic aura diary. *Cephalalgia.* 1994;14(2):107–17
96. Russell MB, Rasmussen BK, Thorvaldsen P, et al. Prevalence and sex ratio of the subtypes of migraine. *Int J Epidemiol.* 1995;24(3):612–8
97. Sanchez del Rio M, Bakker D, Wu O, et al. Perfusion weighted imaging during migraine: spontaneous visual aura and headache. *Cephalalgia.* 1999;19(8):701–7
98. Selhorst JB, Slatkin N, Waybright EA. Migraine, pseudotumor cerebri, blindness and death. Thirty years of visual migraine. Paper presented at the 13th Annual Frank B Walsh Society Meeting. Houston, TX, 1981
99. Sharma K, Wahi J, Phadke RV, et al. Migraine-like visual hallucinations in occipital lesions of cysticercosis. *J Neuroophthalmol.* 2002;22(2):82–7
100. Silberstein SD, Marcellis J. Headache associated with abnormalities in intracranial structure and pressure, in Dalessio DJ, Silberstein SD (eds) *Wolff's Headache and Other Head Pain.* New York, Oxford University Press, 1993, pp 438–61
101. Silvestrini M, Cupini LM, Calabresi P, et al. Migraine with aura-like syndrome due to arteriovenous malformation. The clinical value of transcranial Doppler in early diagnosis. *Cephalalgia.* 1992;12(2):115–9
102. Somjen GG. Ion regulation in the brain: implications for pathophysiology. *Neuroscientist.* 2002;8(3):254–67
103. Somjen GG, Aitken PG. The ionic and metabolic responses associated with neuronal depression of Leao's type in cerebral cortex and in hippocampal formation. *An Acad Bras Cienc.* 1984;56(4):495–504
104. Sowa MV, Pituck S. Prolonged spontaneous complex visual hallucinations and illusions as ictal phenomena. *Epilepsia.* 1989;30(5):524–6
105. Spierings EL. Daily migraine with visual aura associated with an occipital arteriovenous malformation. *Headache.* 2001;41(2):193–7
106. Stewart WF, Shechter A, Rasmussen BK. Migraine prevalence. A review of population-based studies. *Neurology.* 1994;44(6 Suppl. 4):S17–23

107. Stewart WF, Linet MS, Celentano DD, et al. Age- and sex-specific incidence rates of migraine with and without visual aura. *Am J Epidemiol.* 1991;134(10):1111–20
108. Strong AJ, Fabricius M, Boutelle MG, et al. Spreading and synchronous depressions of cortical activity in acutely injured human brain. *Stroke.* 2002;33(12):2738–43
109. Troost BT, Newton TH. Occipital lobe arteriovenous malformations. Clinical and radiologic features in 26 cases with comments on differentiation from migraine. *Arch Ophthalmol.* 1975;93(4):250–6
110. Troost BT, Mark LE, Maroon JC. Resolution of classic migraine after removal of an occipital lobe AVM. *Ann Neurol.* 1979;5(2):199–201
111. van der Kamp W, Maassen VanDenBrink A, Ferrari MD, et al. Interictal cortical hyperexcitability in migraine patients demonstrated with transcranial magnetic stimulation. *J Neurol Sci.* 1996;139(1):106–10
112. Van Harreveld A, Ochs S. Electrical and vascular concomitants of spreading depression. *Am J Physiol.* 1957;189(1):159–66
113. Verma A, Rosenfeld V, Forteza A, et al. Occipital lobe tumor presenting as migraine with typical aura. *Headache.* 1996;36(1):49–52
114. Weiskrantz L, Warrington EK, Sanders MD, et al. Visual capacity in the hemianopic field following a restricted occipital ablation. *Brain.* 1974;97(4):709–28
115. Welch KM. Brain hyperexcitability: the basis for antiepileptic drugs in migraine prevention. *Headache.* 2005;45(Suppl 1):S25–32
116. Welch KM, Ramadan NM. Mitochondria, magnesium and migraine. *J Neurol Sci.* 1995;134(1–2):9–14
117. Welch KM, Chabi E, Bartosh K, et al. Cerebrospinal fluid gamma aminobutyric acid levels in migraine. *Br Med J.* 1975;3(5982):516–7
118. Welch KM, D'Andrea G, Tepley N, et al. The concept of migraine as a state of central neuronal hyperexcitability. *Neurol Clin.* 1990;8(4):817–28
119. Welch KM, Cao Y, Aurora S, et al. MRI of the occipital cortex, red nucleus, and substantia nigra during visual aura of migraine. *Neurology.* 1998;51(5):1465–9
120. Wijman CA, Wolf PA, Kase CS, et al. Migrainous visual accompaniments are not rare in late life: the Framingham Study. *Stroke.* 1998;29(8):1539–43
121. Wittkowsky L. Ophthalmic migraine in arteriovenous aneurysm; symptoms of hemicranias. *Nervenarzt.* 1952;23(4):140–3
122. Woods RP, Iacoboni M, Mazziotta JC. Brief report: bilateral spreading cerebral hypoperfusion during spontaneous migraine headache. *N Engl J Med.* 1994;331(25):1689–92

We wish to thank Mr. Nigel P Davies, Dr Randy H. Kardon and Mr. Timothy D. Matthews for their comments on this manuscript, and Ms. Sara Stock, Ms. Eileen Scrivens and Ms. Debbie Heatlie for their help in obtaining the articles for the review.

Reprint address: Dr Pari Shams, Moorfields Eye Hospital, 162 City Road, London, UK EC1V2PD. e-mail: pari.shams@gmail.com.

Appendix

Case Histories

Case 1: Occipital capillary hemangioma

A 36-year-old civil servant complained of an increase in frequency of migraine headaches with visual aura, which he had experienced since the age of 20. The aura began as a star-shaped pin-point of light in the right lower quadrant and expanded as a circle and then as a horse-shoe of triangular zigzag lines (Fig. A1-A) over several minutes. The horse-shoe finally occupied the entire right peripheral hemifield. This visual aura lasted up to 60 minutes followed by a left occipital headache lasting many hours and relieved by ibuprofen and sleep. On one occasion, he experienced a witnessed nocturnal seizure lasting 30 seconds. At the age of 30 he began to experience daily, 10-second episodes of a small star shaped flashing light. These brief visual phenomena also appeared in the right lower quadrant. Drinking concentrated orange juice could reliably precipitate an attack.

At age 35 following a typical aura he noticed a persistent defect in the right hemifield. Humphrey (Fig. A1-B) and Goldmann (Fig. A1-C) perimetry revealed no visual field defect (VFD). A magnetic resonance imaging (MRI) of the brain revealed a heterogeneous lesion within the left occipital lobe, consistent with a cavernoma (Fig. A1-D). Treatment with oral pizotifen and beta-blockers had no effect, although sodium valproate significantly reduced the

frequency of his migraine aura and headaches (Fig. A1-E). To date he continues to experience the brief star-shaped visual phenomena daily.

Case 2: Occipital infarction

A 34-year-old ballet teacher experienced her very first visual aura when 16 weeks into her first pregnancy. She developed a shimmering visual phenomenon in the right visual field, similar to “light reflected off a swimming pool,” which enlarged to occupy the entire right hemifield. This was followed by a feeling of confusion and an expressive dysphasia. The episode lasted 15 minutes and was followed by a severe headache and nausea lasting 24 hours. During this time she was aware of a disturbance of the right visual field, which resolved over a day or two. There was no past history of headaches or migraine. There was a family history of cluster headaches. She continued to have similar episodes every three to four weeks not associated with headaches but a feeling of exhaustion.

Twenty-three hours into labour she experienced the same visual aura. She became drowsy and incoherent then unresponsive. She appeared pale; there were no convulsive movements. This episode lasted several seconds and she recovered quickly. The baby was immediately delivered by Caesarian section. An MRI scan of the brain showed an infarct in the left posterior cerebral artery territory involving the fusiform gyrus and ventral optic

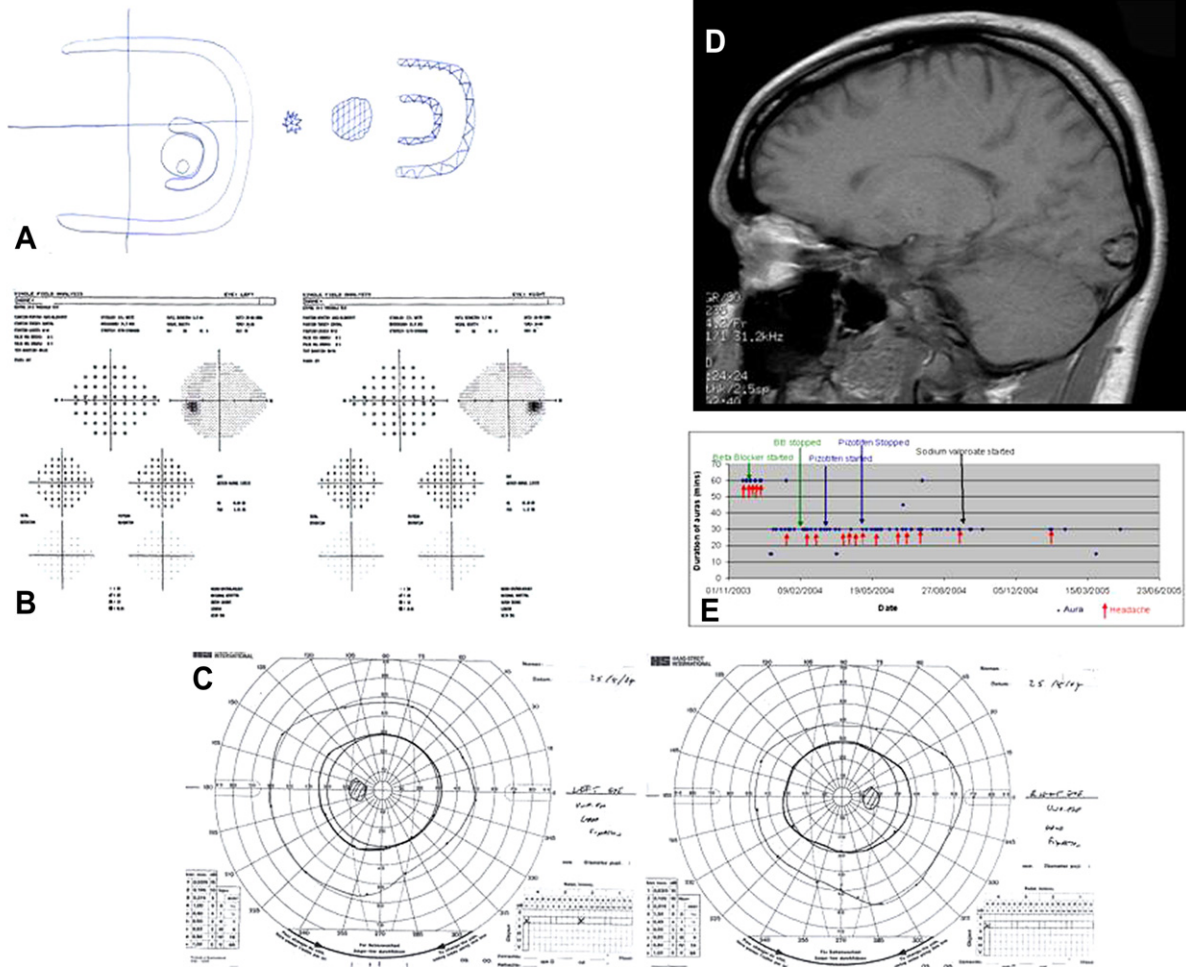


Fig. A1. Case 1. *A:* Visual aura experienced by case one. A star shaped pin-point of light appearing in the right lower quadrant of the visual field, expanding first as a circle and then a horse-shoe of triangular zigzag lines over several minutes and occupying the entire right peripheral hemifield over 2 minutes. *B:* 24-2 Humphrey visual field exam showing a normal visual field in both eyes. *C:* Goldmann perimetry showing a normal visual field in both eyes. *D:* T1 weighted sagittal MRI brain scan showing a heterogeneous lesion within the left occipital lobe, with a hemosiderin rim signal intensity, in keeping with a cavernoma. *E:* Symptom diary showing the frequency of headaches and visual aura over 18 months which were significantly reduced with sodium valproate.

radiations. The age of the infarct could not be determined and extensive investigations failed to reveal an underlying cause.

Over the next 3 years she had two miscarriages and another successful pregnancy. She continued to experience frequent migrainous visual aura but only during pregnancy, labor, and for a short time postpartum or following miscarriage. On four occasions, the visual aura were followed by loss of consciousness. Twenty-four hour ambulatory electroencephalogram (EEG) during pregnancy did not show evidence of epileptiform activity, although she was asymptomatic at the time. Following the birth of her second child her visual aura became extremely frequent occurring several times per day. Then after a typical visual aura she noticed that her right visual

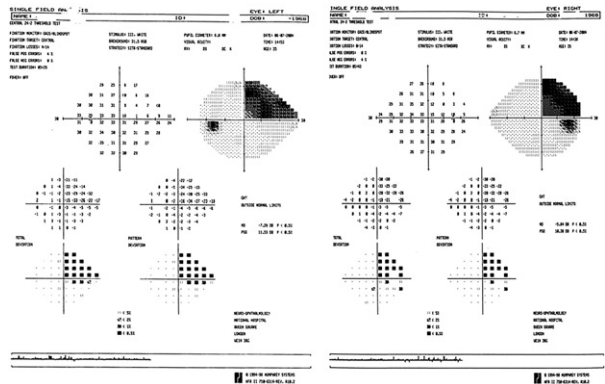


Fig. A2. Case 2. 24-2 Humphrey visual field exam of both eyes, revealing a right superior homonymous quadrantanopia consistent with a known infarction of the left optic radiation.

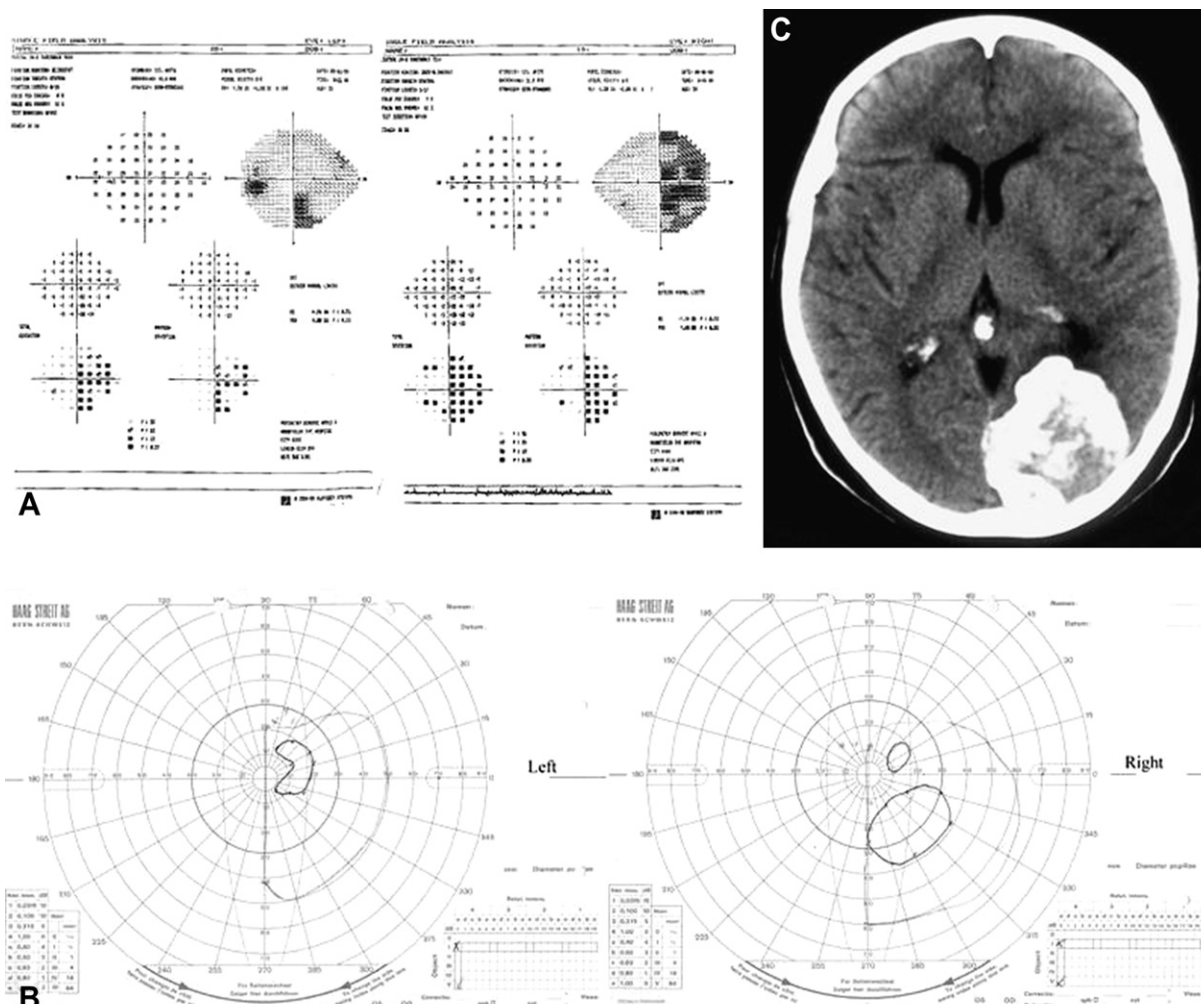


Fig. A3. Case 3. A: 24-2 Humphrey visual field exam of both eyes, showing an incidental and asymptomatic right homonymous hemianopia. B: Goldmann perimetry of both eyes confirming the right homonymous hemianopia. C: Axial contrast enhanced CT brain scan showing a large, partly calcified tumor in the left occipital region, consistent with a meningioma. Some minimal surrounding oedema and anterior displacement of the posterior horn can also be seen.

field disturbance did not fully resolve as before. Humphrey perimetry revealed a right superior homonymous quadrantanopia (Fig. A2). The VFD was consistent with the known infarction of the left optic radiation. She complained of a constant shimmering in this area of her visual field with accompanying persistent visual images. A repeat MRI brain scan showed no change. Oral levetiracetam was commenced and lamotrigine slowly discontinued. At the time of writing her migrainous aura had become associated with an alteration in sensation over the right side of her face, heaviness of the right upper and lower limb, and thirst, followed by a severe headache and nausea. These episodes occurred predictably several days prior to her menses. The visual aspects of the aura remain unchanged.

Case 3: Occipital Meningioma

A 62-year-old retired nurse had experienced weekly migraine headaches associated with visual aura since the age of 40. At 50 these reduced in frequency to once a month. The aura consisted of fortification spectra (expanding zigzag) and transient flashing white lights always recurring in the right visual field followed several minutes later by a moderate to severe left-sided throbbing headache. Episodes of aura lasted minutes and were associated with nausea, photophobia, and headache lasting several hours; relieved by sleep and oral analgesia. She had always been a heavy smoker.

During a routine visit to her local optometrist she was found to have an incidental and asymptomatic right homonymous hemianopia (Figs. A3-A and-B).

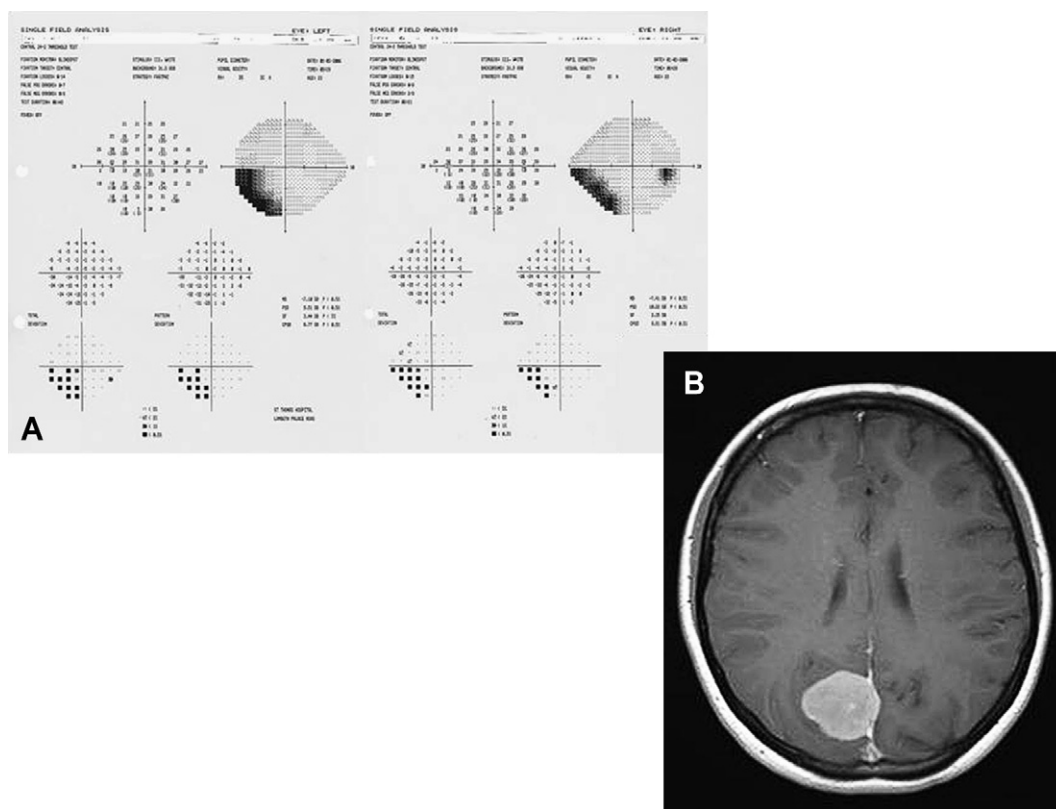


Fig. A4. Case 4. *A:* 24-2 Humphrey visual field exam of both eyes, showing left inferior homonymous quadrantanopia. *B:* Axial contrast enhanced T1 weighted MRI brain scan showing evidence of a uniformly enhancing meningioma, 3 cm in diameter, arising from and incorporating the right side of the posterior falx cerebri and displacing the adjacent right occipital lobe.

A computerized tomography (CT) brain scan revealed a large, partly calcified meningeal tumor in the left occipital region consistent with a meningioma (Fig. A3-C)- with minimal surrounding edema- although the mass itself was seen to displace the trigone of the left lateral ventricle. She declined surgical intervention.

Case 4: Occipital Meningioma

A 23-year-old medical secretary developed intermittent episodes of visual disturbance affecting the left hemifield. She characterized these as repetitive flashes of light similar to those of a photographic camera occurring every 3 seconds and lasting approximately 2 minutes. They were followed by blurring of the left hemifield which gradually shrank and disappeared over 30 minutes. There was no associated headache. She was a non-smoker, with a positive family but no personal history of migraine. There were no identifiable triggers for these attacks. An ophthalmologist diagnosed acephalgic migraine with visual aura. She experienced 10 to 15 such episodes over a 6-month

period. One day following a typical attack she was left with a persistent partial left homonymous quadrantic VFD. She had no other neurological or ophthalmic symptoms. Humphrey (Fig. A4-A) and Goldmann visual field examinations confirmed the left inferior homonymous quadrantanopia and an MRI brain scan showed evidence of a uniformly enhancing mass arising from and incorporating the right side of the posterior falx cerebri (Fig. A4-B), confirmed as a meningioma following surgical excision.

Case 5: Occipital Capillary Hemangioma

A computer programmer began to develop visual aura at age 16. These always commenced with a flashing white light immediately to the right of fixation, along the horizontal meridian, which evolved into a shimmering white zigzag line of light. Surrounding the white light was a blind spot through which he was only able to see objects in outline. He felt his right visual field was impaired and appeared darker. The zigzag lines neither moved across the visual field nor increased in size.

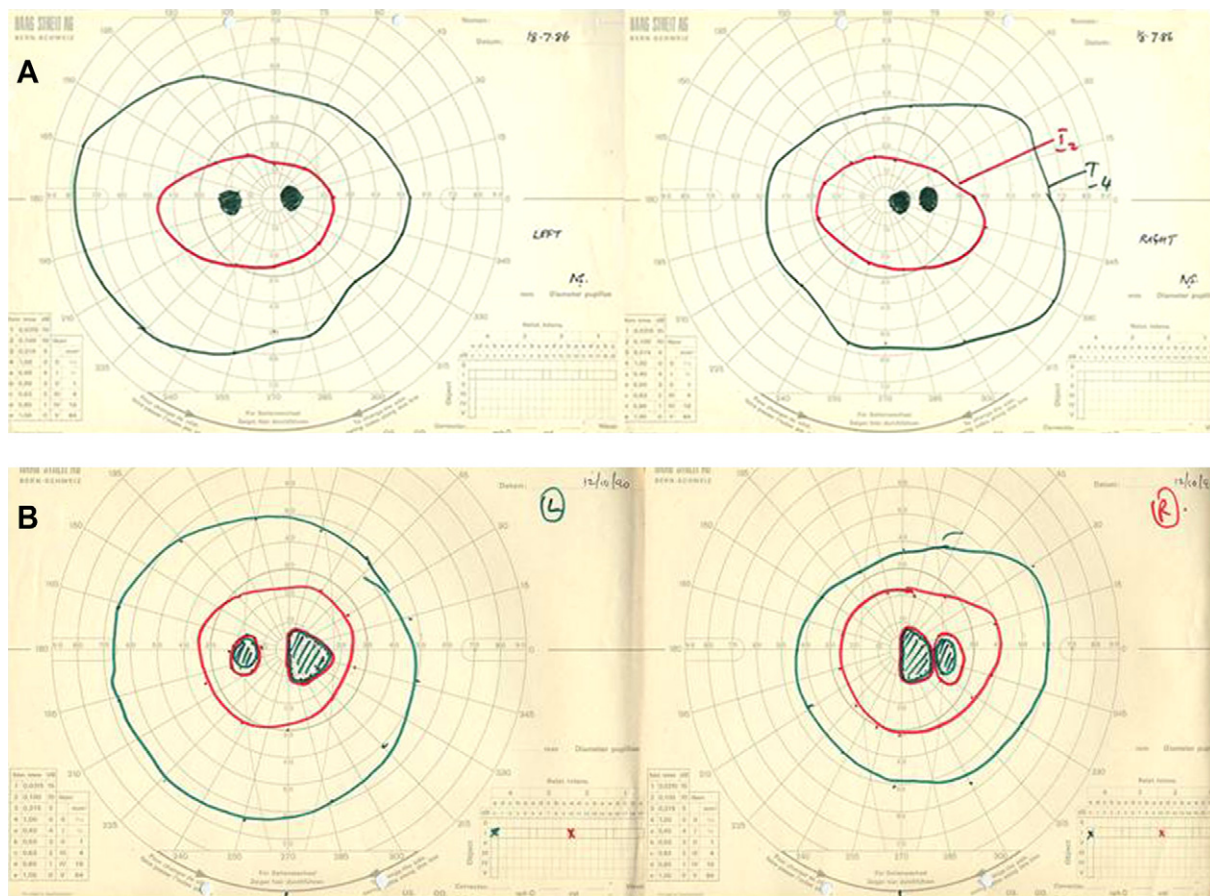


Fig. A5. Case 5. A: Goldmann perimetry of both eyes showing a small right homonymous scotoma. B: Repeat Goldmann perimetry of both eyes 4 years later showing slight enlargement of the right homonymous scotoma.

The visual disturbance lasted 5 to 10 minutes then resolved rapidly. A headache immediately followed the visual aura, localized above the left eye and of moderate severity, lasting 24 hours. Although the first attack occurred while reading- with words dancing across the page- most subsequent attacks were exercise-induced; occurring very predictably after 20 minutes of physical exertion. He played football twice per week and for years experienced attacks on every occasion. Five to ten episodes per year would be induced by intense study. He gave a history of minor head injury at age 7 after falling off a bicycle.

One day, age 22, following a typical attack at a football game, the visual aura was replaced by flashing white lights throughout the visual field. According to an eye witness he was wandering aimlessly and after 10 minutes lost consciousness followed by a 1-minute seizure and incontinence. Afterwards he felt confused but had no headache, neck stiffness, or photophobia. A CT brain scan and EEG were reported as normal. He was commenced on pizotifen.

Following this episode he noted a permanent blind spot to the right of fixation in which there were a cluster of three small bright white flickering spots and eventually became persistent, appearing brighter after alcohol and within 10 minutes of exercise. He was commenced on phenytoin. A small right hemi-scotoma was confirmed using Goldmann perimetry (Fig. A5-A). There were no other neurological signs. A CT brain scan showed a small non-enhancing hyperdense lesion in the left occipital lobe associated with local mass effect. A second EEG found no evidence of seizure activity. Surgical intervention was considered unnecessary and he was discharged home on phenytoin. He remained well over the next 4 years and slowly began to reduce the dose of phenytoin. One evening after a visual aura he was woken by a sudden severe pain behind the left eye and left occipital region exacerbated by the valsalva maneuver associated with neck stiffness and photophobia. He had a positive kernig's sign, a slightly enlarged right homonymous scotoma on repeat Goldmann perimetry (Fig. A5-B), and swelling of the left optic disk. There was a right upper motor neuron facial weakness but no motor or

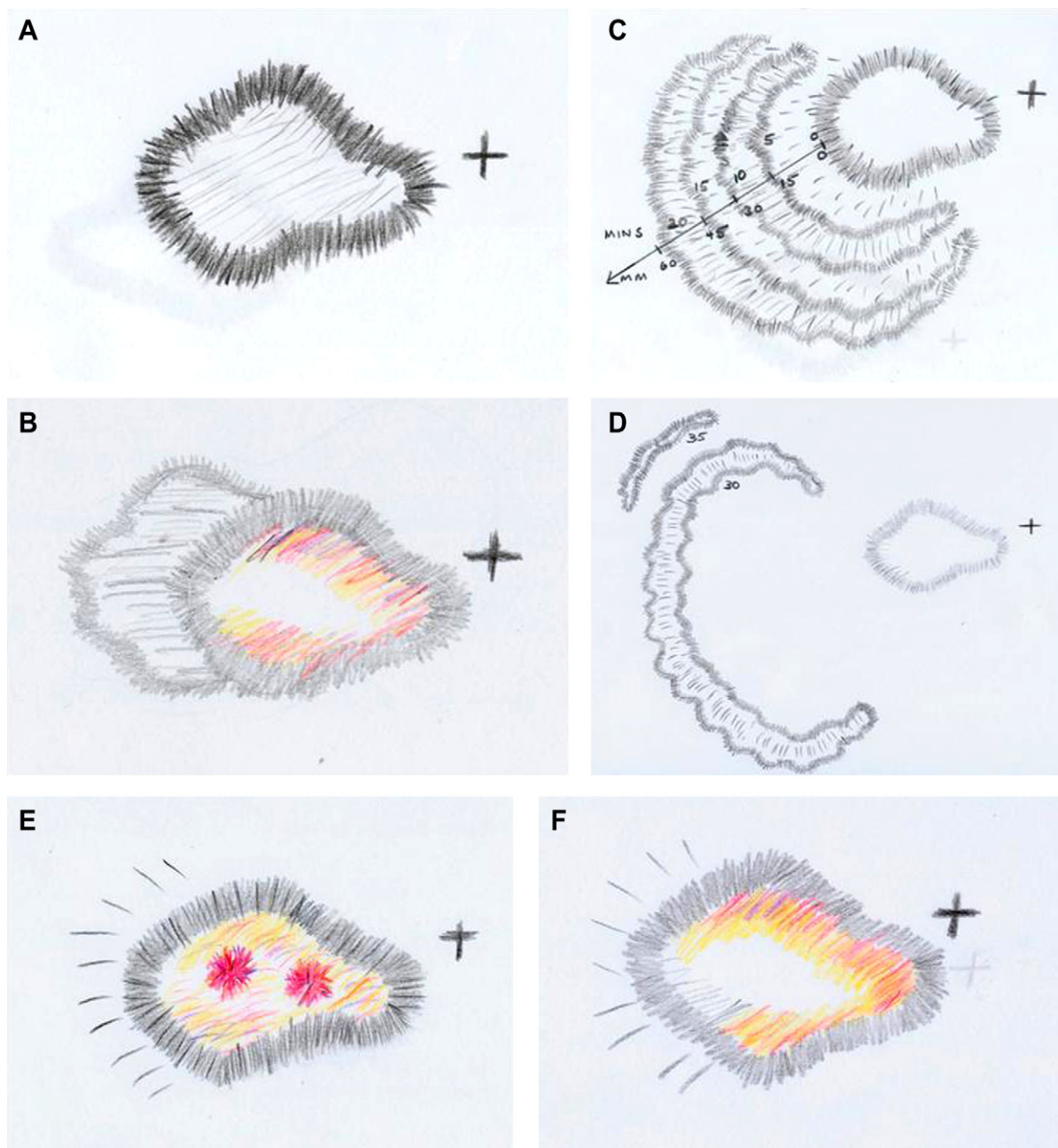


Fig. A6. Case 6. Visual aura experienced by case 6. *A:* The initial circular homonymous scotoma appearing just below the center of the visual field, its edges shimmering and flashing in black and white. *B:* Crescent of light emerging from the left edge of the scotoma five minutes later. *C:* Shimmering zigzag crescents moving leftward across the visual field, at a rate of 3 mm per minute. *D:* The crescent progressively enlarging as it moves across and finally disappearing from the left visual field 35 minutes from the start of the aura. *E:* New visual aura consisting of two spots of multi-colored lights, deep purple and red, within the scotoma, flashing four to five times per second. *F:* Persistent left homonymous scotoma within which the patient perceived brightly colored lights that gently shimmered constantly. *G:* Goldmann perimetry of both eyes confirming the left homonymous scotoma. *H:* Colored fundus photograph of the right eye showing a subhyloid hemorrhage adjacent to the supero-temporal vascular arcade and a normal optic disc. *I:* Axial T2 weighted STIR sequence MRI brain scan showing the presence of a subarachnoid haemorrhage and occipital hematoma. *J:* Catheter angiography revealing the presence of a right occipital arterio-venous malformation (AVM).

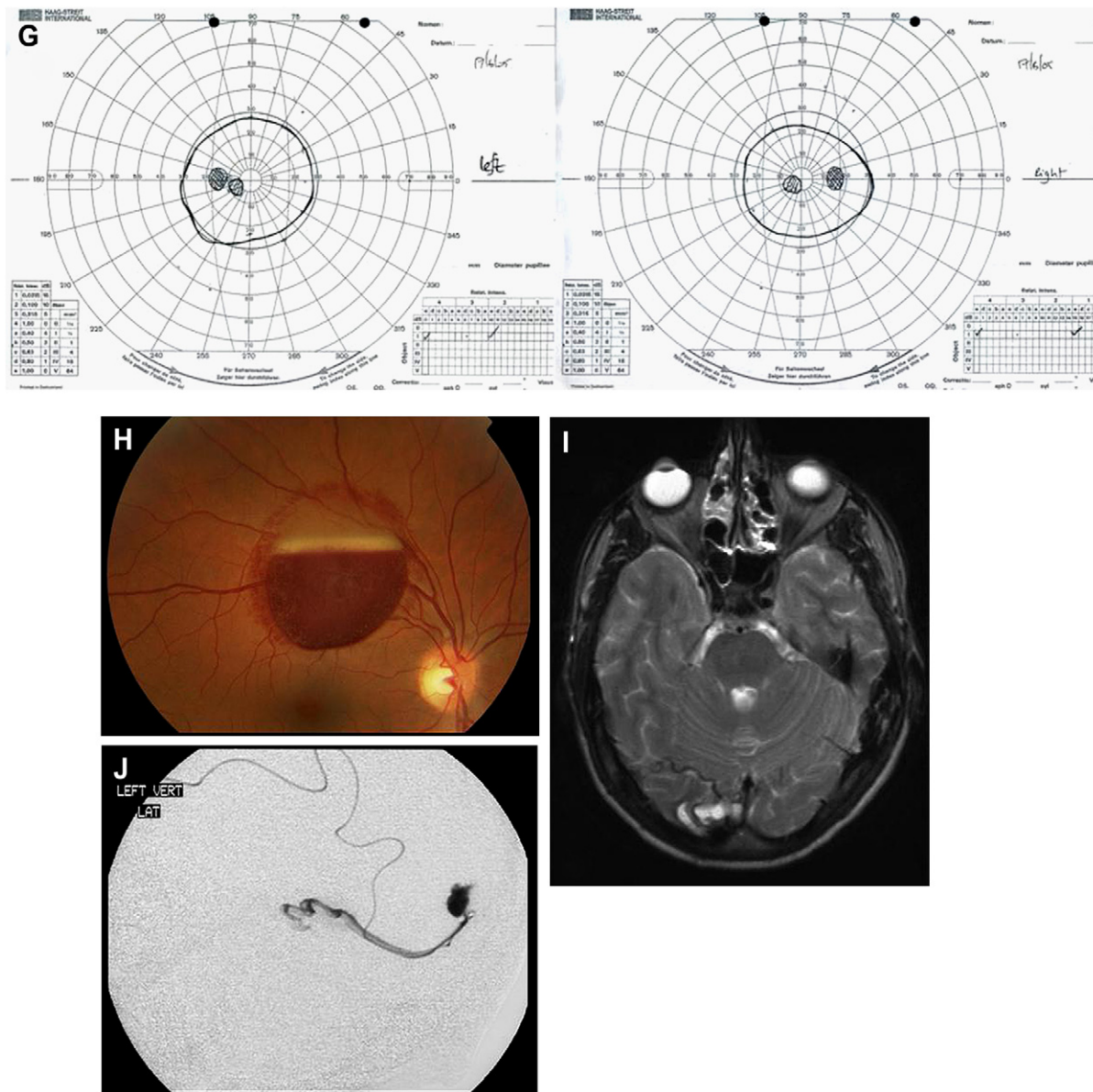


Fig. A6. Continued.

sensory abnormality of the upper or lower limbs or dysphasia. A CT brain scan revealed a hemorrhage in the left occipital lobe. MRI scan of the brain showed a high signal mass in the occipital lobe on T1 and T2 sequences with low signal at its central core consistent with a left hematoma. Surrounding edema and serpiginous structures with flow voids were noted just medial to the mass suggestive of an arterio-venous malformation (AVM). He underwent excision of the lesion which was histologically confirmed as a capillary hemangioma. Following surgery his right paracentral scotoma did not alter and he continued to experience shimmering zigzag lines in the right visual field. He also complained of a persistence of images in the right visual field following resolution of the typical aura. The frequency of his visual aura and associated headaches

reduced. At the time of writing he continues to have visual aura but remains seizure-free on phenytoin.

Case 6: Occipital arteriovenous malformation

A 33-year-old man with no prior history of headache or migraine developed a severe headache of sudden onset over the vertex of the head, on climbing to altitude in an aircraft. The headache was constant in nature and lasted 15 minutes. He did not experience any neurological symptoms. In the days following this episode he developed stereotyped visual aura not associated with a headache. The aura always began just below and to the left of center of the visual field as a circular scotoma, the edges of which appeared to be shimmering and

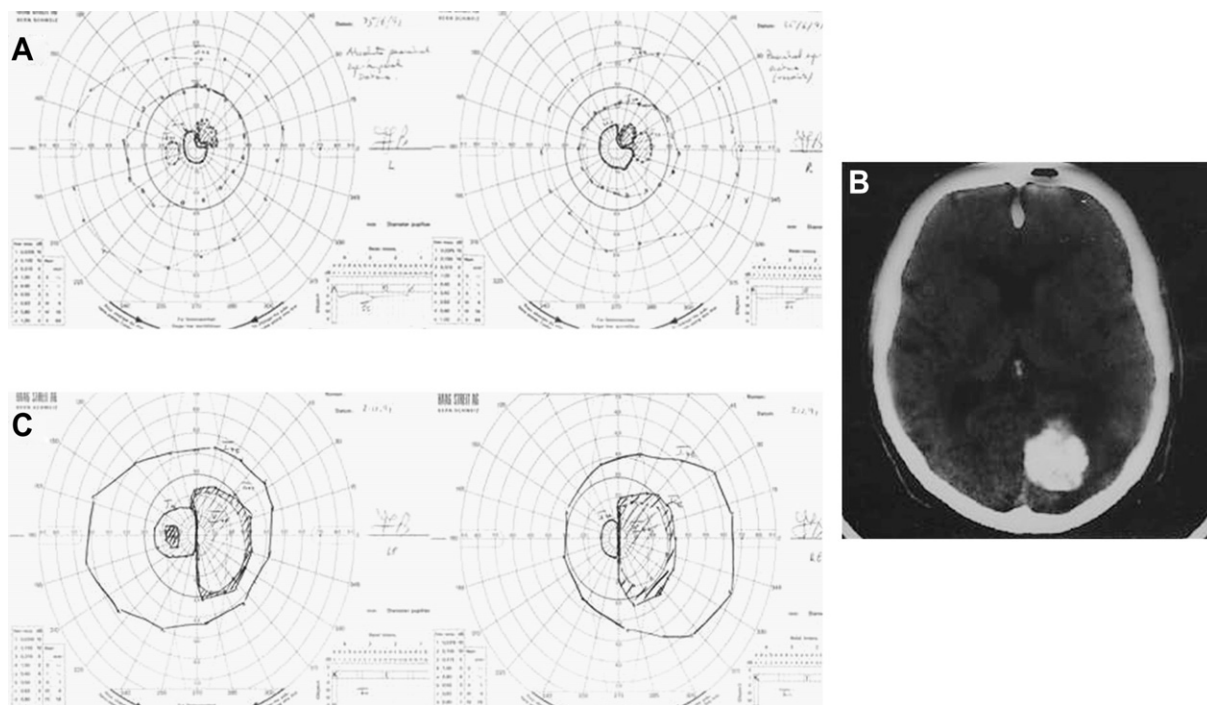


Fig. A7. Case 7. **A:** Goldmann perimetry of both eyes showing a right homonymous supra-temporal quadrantic scotoma. **B:** Left occipital parafalcine/tentorial meningioma. CT head showing a densely calcified large left occipital mass adjacent to the posterior falx cerebri causing moderate mass effect and distortion of the left occipital horn and trigone. There is moderate vasogenic edema and enhancement of the non-calcified anterior portion of the tumor. **C:** Goldmann perimetry of both eyes showing an increase in the size of the visual field defect (VFD) postoperatively to a complete right homonymous hemi-scotoma.

flashing in black and white (Fig. A6-A). After 5 minutes a crescent of light would emerge from the left edge of the scotoma (Fig. A6-B), shimmering intensely as it moved leftward across the visual field, at a rate of 3 mm/minute (Fig. A6-C). The crescent progressively enlarged and its zigzag edges became more pronounced and disappeared once it reached the far periphery of the left visual field (Fig. A6-D), 35 minutes from the start of the aura. Over the next 3 months he experienced six such visual aura.

He then developed a second headache over the vertex, this time of much greater severity than the first. He transiently experience slurred speech, weakness, paraesthesia of the left leg, and a visual aura which began rather differently. There were two flashing spots of multi-colored lights, deep purple and red, within the scotoma (Fig. A6-E). After 10 minutes the flashing lights became smaller with the edges of the scotoma still shimmering. The crescent of light then appeared from the edge of the scotoma as before and began to enlarge and move peripherally. During this episode he was taken by ambulance to the local hospital. He had no investigations and was diagnosed with migraine. He continued to experience a less severe but persistent headache for the following 2 weeks. He also noticed a persistent “blind-spot” just left of the center of his

visual field, which was made of brightly colored lights that gently shimmered at all times (Fig. A6-F). However, immediately following an aura the scotoma become “silent,” inactive and dark persisting for 24 hours before “recovering” to its semi-active resting state. Although he could not see through the scotoma, he was aware of movement within it.

His headaches responded to pizotifen, but there was no effect on his visual aura. A visual field exam confirmed the left homonymous scotoma (Fig. A6-G). Fundoscopy revealed a right subhyloid hemorrhage adjacent to the supero-temporal vascular arcade (Fig. A6-H). An urgent MRI of the brain showed a subarachnoid hemorrhage and occipital hematoma (Fig. A6-I). An angiogram confirmed the presence of a right occipital AVM, which was later embolized (Fig. A6-J). To date he remains well although his scotoma and visual aura persist.

Case 7: Occipital meningioma

A 55-year-old forklift truck driver had a 2-year history of visual phenomena, gradually increasing in frequency. A typical episode was characterized by the sudden appearance of a gray circular patch with undefined margins in the right superior quadrant of his visual field. Thirty seconds later the grey patch

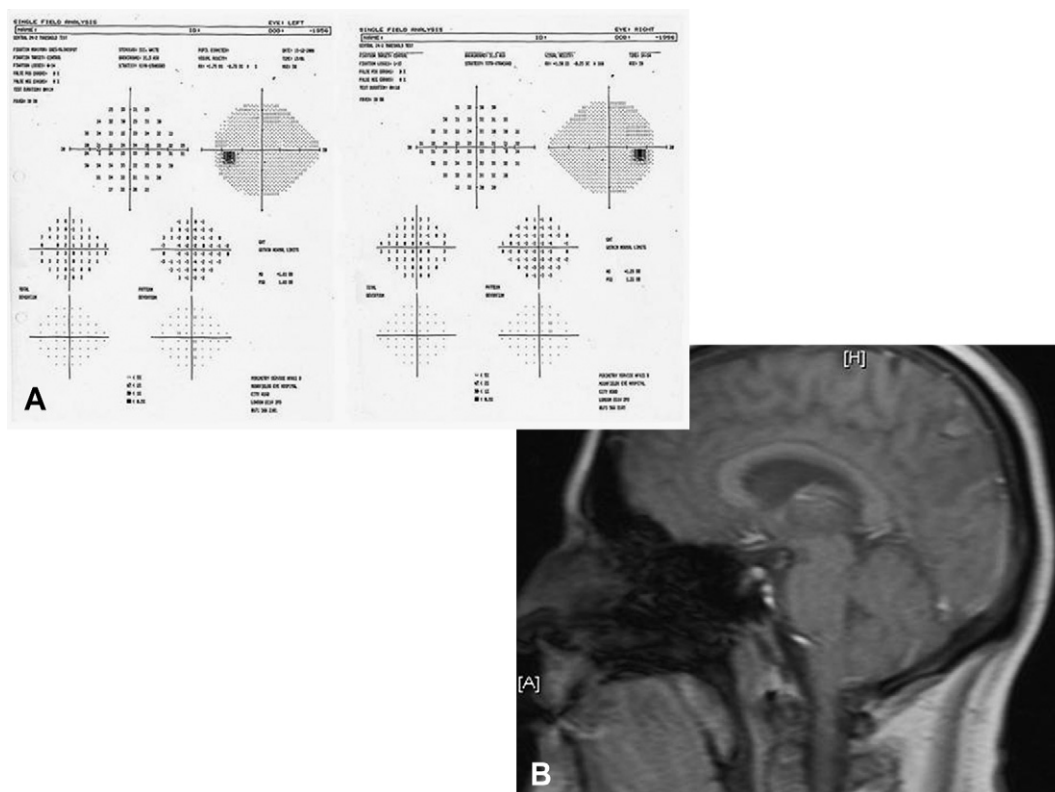


Fig. A8. Case 8. A: 24-2 Humphrey visual field exam showing a normal visual field in both eyes. B: Gadolinium enhanced sagittal T1 weighted MRI brain scan showing an area of signal intensity in the left parieto-occipital region, predominantly involving the precuneus region, immediately rostral to the primary visual cortex.

turned black with well-defined margins and began to pulsate in time with his heartbeat. He noted that this dark circle was surrounded by a white halo. These symptoms lasted between 5 and 30 minutes and were followed minutes later by zigzag lines filling the lower half of the visual field lasting 2 to 3 minutes.

These attacks had recently increased in frequency from once per month to once or twice per day, accompanied by a non-pulsatile headache of moderate intensity, felt over the vertex, lasting 1 to 3 hours. He was investigated for amaurosis fugax; digital subtraction angiography was negative but he was commended on aspirin and treatment for hyperlipidemia. A trial of pizotifen was of no benefit.

A Goldmann visual field examination identified a right central supra-temporal quadrantic homonymous scotoma (Fig. A7-A), which had been missed in the left eye on his previous visual field examination. A CT brain scan revealed a large occipital meningioma with moderate mass effect (Fig. A7-B), histologically confirmed following excision via a left occipital craniotomy.

Postoperatively his VFD increased in size to a complete right homonymous hemi-scotoma (Fig. A7-C). His visual aura disappeared completely. Six weeks postoperatively he developed the new

visual phenomena. Firstly he experienced image preservation in his blind field, with ghost images appearing within his scotoma, usually of objects or people that had crossed his field of vision, persisting for 5 to 6 seconds. Secondly, he described formed visual hallucinations composed of letters of the alphabet in print, spontaneously appearing within his scotoma, then moving and disappearing within a few seconds; he had been a printer years ago. Thirdly, he experienced extensive filling in of his scotoma such that someone walking in front of him would disappear and then reappear at the other edge of the scotoma but there was no impression of a gap in the background. To date these symptoms have persisted but he remains well.

Case 8: Parieto-occipital oligodendroglioma

A 51-year-old courier company supervisor presented with an 8-year history of recurrent transient visual symptoms. These episodes were characterized by a pressure-like sensation across the forehead, lateralizing to the right side and lasting 2 minutes. This was followed by bilateral blurring of the right hemifield, which fully resolved in no more than 3 minutes. He then became aware of a dull pulsatile

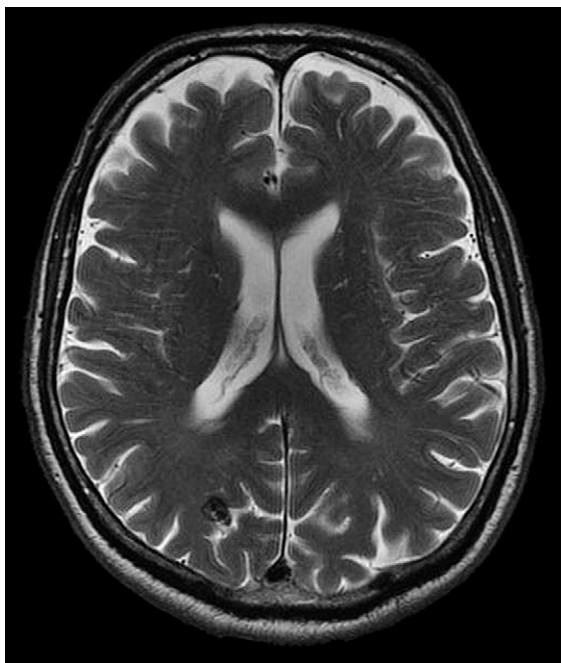

Fig. A9. Case 9. Axial T2 weighted MRI brain scan showing a small cavernous haemangioma within the right occipital lobe.

retro-orbital ache lasting a further 5 minutes. During these attacks he felt well but found it difficult to judge distances. Initially they occurred on a daily basis but after several months reduced in frequency to four times per year. He was on treatment for hypertension and an ex-smoker of 40 cigarettes per day. There was no family history of migraine. Several years earlier he had been investigated for these symptoms, thought to be right amaurosis fugax, but no abnormality was found.

Four weeks prior to his latest presentation and immediately following a typical visual aura he developed motor weakness, twitching, and paresthesia of the right upper and lower limb lasting 30 seconds. He found it difficult to place his feet down while walking, as he could not accurately judge his distance from the floor. His ocular and neurological examination including Humphrey visual fields (Fig. A8 -A)

were entirely normal. A gadolinium enhanced sagittal MRI of the brain (Fig. A8-B) showed an area of signal intensity, consistent with an oligodendroglioma, in the left parieto-occipital region, predominantly involving the cortex immediately rostral to the primary visual cortex, as well as adjacent white matter. He is currently awaiting a tissue biopsy.

Case 9: Occipital capillary hemangioma

A 76-year-old retired dentist began to experience regular episodes of visual migraine at the age of 20 while attending college. These occurred every 3 months and always began in the left inferior quadrant of the visual field where a spot would appear then slowly enlarge into a zigzag as it moved peripherally. These attacks lasted exactly 30 minutes and were never associated with headache or nausea. Shortly after they commenced, he developed a different type of aura, consisting of a bright yellow spot which could be anywhere in the visual field and lasted only seconds. Three such episodes were followed by a grand mal seizure leading to clinical investigations. An air encephalogram and angiogram only revealed several intracerebral calcified lesions which may have resulted from a head injury at the age of 12. His migraine-like visual aura persisted over the years without further seizures.

At the age of 74 he began to develop symptoms of ulcerative colitis and during relapses he began to experience a different type of visual aura, rather more variable than the “old style” aura. They usually began as a left inferior scotoma and gradually enlarged to a typical zigzag pattern lasting approximately 30 minutes, again without headache. Some attacks appeared to suddenly terminate halfway through. At this time he was also diagnosed with scleroderma with no other systemic manifestations. Whenever he felt unwell, his new visual aura occurred 4 to 5 times a day. Due to the marked change in the pattern of his visual aura an MRI scan of brain was organized which revealed a small cavernous hemangioma within the right occipital lobe (Fig. A9).

Outline

- I. Introduction
- II. The classic visual aura of migraine
- III. Typical migraine-like visual aura not due to migraine
- IV. Migraine-like visual aura: migraine or structural intracranial pathology? The evidence

- V. Migraine or structural intracranial pathology? Key diagnostic and differentiating clinical features of visual aura
 - A. Clinical features that cannot reliably differentiate the visual aura of migraine from those due to structural lesions

1. Scintillating scotoma or teichopsia
 2. Duration of the visual aura
 3. Visual aura recurring in the same hemifield
 4. Past history of migraine with or without aura
- B. Clinical features which should raise doubts about a diagnosis of migraine
1. Migraine-like visual aura without headache
 2. Brief visual aura lasting seconds or less than 5 minutes
 3. Age greater than 40, especially without a past history of migraine
- C. Clinical features warranting neuroimaging
1. Stereotypical visual aura
 2. Increase in frequency or change in the pattern of longstanding visual aura
 3. Sudden alteration in aura characteristics
 4. Any unexplained visual field defect and/or subjective persistence of a scotoma following a typical visual aura
 5. Co-existence of seizures
- VI. Visual aura: migraine or epilepsy?
- VII. Cortical hyperexcitability: a shared pathophysiology and unifying theory?
- A. Functionally hyperexcitable “inter-ictal” visual cortex in patients with migraine and epilepsy
 - B. Physiological basis for cortical hyperexcitability in patients with migraine
 - C. Proven efficacy of migraine prophylactic agents
 - D. Disorders of neuronal membrane excitability caused by mutations of ion channels
 - E. Neuronal hyperexcitability and csd induced by acquired cortical lesions
- VIII. Conclusion
- IX. Method of literature search
- X. Disclosure