

Cerebral Venous Sinus Thrombosis Associated With a Combined Contraceptive Ring

Jennifer E. Fugate, DO, Maisha T. Robinson, MD, Alejandro A. Rabinstein, MD, and Eelco F.M. Wijdicks, MD, PhD

Introduction: Combined contraceptive vaginal rings are used as an alternative to oral contraceptives with a purported advantage of allowing lower hormonal doses, and thus potentially confer a lower venous thromboembolism risk. Cerebral venous sinus thrombosis (CVST) has not been previously described in association with use of a combined contraceptive ring.

Case Report: A 32-year-old white woman presented with severe headache progressively worsening over days and subsequently developed acute left sided hemiplegia and sensory loss. Brain imaging revealed acute right parietal cortical infarction and extensive CVST. Evaluation for primary thrombophilia was unrevealing. The sole hypercoagulable risk factor identified was use of a vaginal contraceptive ring. The patient was anticoagulated and demonstrated marked clinical improvement.

Conclusion: We report the first described case of CVST associated with use of a vaginal contraceptive ring. CVST should be recognized as a potentially fatal complication related to this therapy.

Key Words: venous sinus thrombosis, stroke, hypercoagulable

(*The Neurologist* 2011;17:105–106)

The use of oral contraceptives is known to be an independent risk factor in developing cerebral venous sinus thrombosis (CVST).^{1,2} The risk of venous thrombosis in patients taking oral contraceptives decreases with decreasing estrogen dose.³ One alternative to oral contraceptives is a combined contraceptive vaginal ring (NuvaRing). An advantage of the vaginal ring in comparison with oral contraceptives is that in avoiding first-pass hepatic metabolism and gastrointestinal interference with absorption of steroids, lower hormonal doses can be used.⁴ Although previous thrombo-embolism is a contraindication for prescribing the combined contraceptive vaginal ring, the potential for CVST may not be well recognized because it is said to be a safe and reliable method of contraception,⁵ and in a recent review, there is no mention of potential risk of venous thromboembolism.⁶

CASE REPORT

A 32-year-old white woman developed an acute onset of left face and arm weakness preceded by 3 weeks of severe progressive headache. Three days before admission to our hospital her headache worsened and persisted, which prompted presentation to an outside emergency department. She was treated with intravenous hydromor-

phone and was dismissed. Two days later, she awakened with weakness and paresthesias involving her left face and arm and was admitted to the outside hospital. She was a lifelong nonsmoker and took no regular oral medications but was using a combined contraceptive vaginal ring (NuvaRing, etonogestrel/ethinylestradiol). There was no personal or family history of prior venous thromboembolism, thrombophilia, spontaneous miscarriage, or malignancy. There was no history of recent head trauma or dehydration.

On examination, the patient was drowsy but opened her eyes to voice. The temperature was 36.8°C, the blood pressure was 127/67 mm Hg, and the pulse was 75 beats per minute. Speech was fluent and clear. She had a right gaze preference and left visual neglect. Ocular movements were full, and there was no evidence of papilledema. She had left-sided flaccid hemiparesis affecting face and arm greater than leg, with no movement in her left upper extremity to pain and antigravity strength in her lower extremity. There was left-sided extinction to simultaneous tactile stimulation.

Brain magnetic resonance imaging revealed evidence of acute infarction of the cortex and subcortical white matter of the right frontal and parietal lobes with restricted diffusion. In addition, extensive venous sinus thrombosis involving the superior sagittal and right transverse sinuses was seen (Fig. 1). Brain magnetic resonance arterial angiogram was unremarkable. The following morning, the patient had a focal seizure consisting of rhythmic clonic movements involving her left arm and leg. Head computed tomography scan demonstrated hyperattenuation of the right transverse and superior sagittal sinus, hypoattenuation of the right frontal lobe and possible scattered scattered subarachnoid blood in the right fronto-parietal sulci (Fig. 1). She was transferred to our institution for further evaluation and management.

Laboratory studies including antiphospholipid antibodies, activated protein C ratio, protein C activity, protein S activity, and homocysteine, international normalized ratio, prothrombin time, and activated partial thromboplastin time were normal. A serum pregnancy test, factor V Leiden mutation assay, and prothrombin 20210 mutation assay were negative. Doppler evaluation of both lower extremities showed no evidence of deep venous thrombosis.

The patient was treated with intravenous heparin as a bridge to oral warfarin therapy. The vaginal ring was removed. She was maintained on levetiracetam for seizure prophylaxis and had no further clinical seizures. The patient completed 11 days of inpatient rehabilitation. At discharge, she had marked improvement with mild residual weakness involving the left upper extremity and was ambulating independently.

DISCUSSION

To our knowledge, this is the first well-documented case of CVST in association with the use of a combined contraceptive vaginal device (NuvaRing). Cerebral venous thrombosis was mentioned in one study but without any details.⁵ Our patient had a very extensive clot involving major venous tributaries and endovascular lysis was deemed technically challenging if not impossible. No thrombophilia could be demonstrated which might strengthen the possible association with the vaginal ring. Vaginal rings have been used for many years and the sudden appearance of an association with CVST

From the Department of Neurology, Mayo Clinic, Rochester, MN.
Reprints: Jennifer E. Fugate, DO, 200 First St. SW, Rochester, MN 55905.

E-mail: fugate.jennifer@mayo.edu.

Copyright © 2011 by Lippincott Williams & Wilkins

ISSN: 1074-7931/11/1702-105

DOI: 10.1097/NRL.0b013e3181dd904a

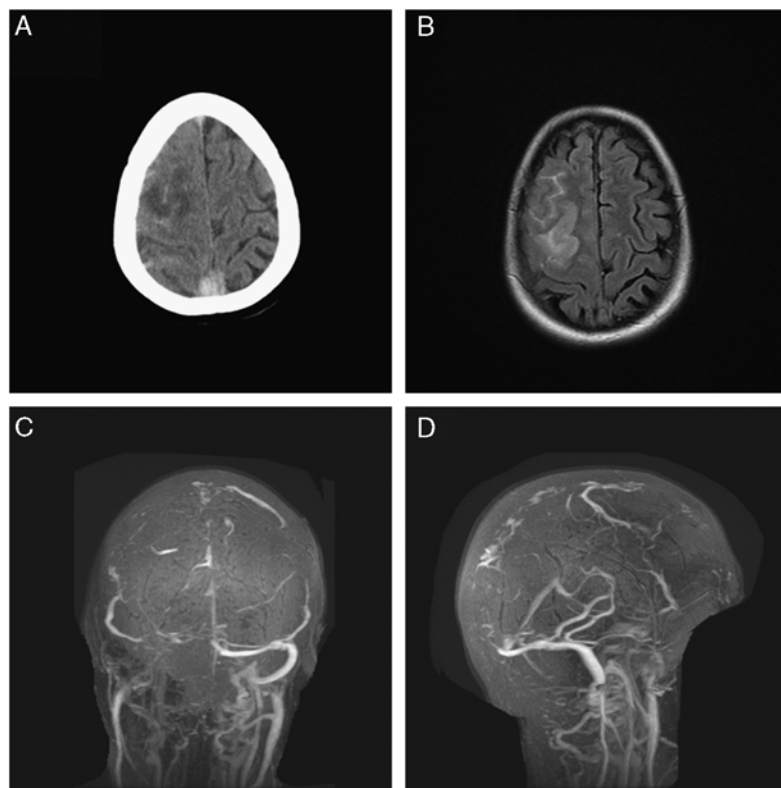


FIGURE 1. Extensive cerebral venous sinus thrombosis. Noncontrast CT demonstrating sagittal sinus hyperdensity and right frontal hypodensity (A). FLAIR MRI shows hyperintensity involving right frontal cortex (B). MRV reveals occlusion of the superior sagittal sinus, right transverse, sigmoid, and jugular vein (C, D), indicative of extensive venous thrombosis.

is surprising. We cannot exclude the possibility that minor cases of CVST are not recognized. The risk of CVST using vaginal delivery devices is low, as with oral contraceptives. Nonetheless, albeit rare, the risk of CVST—and venous thromboembolism in general—should be recognized as a potential complication associated with the use of a combined contraceptive vaginal ring.

REFERENCES

1. Martinelli I, Sacchi E, Landi G, et al. High risk of cerebral-vein thrombosis in carriers of a prothrombin-gene mutation and in users of oral contraceptives. *N Engl J Med.* 1998;338:1793–1797.
2. de Bruijn SF, Stam J, Koopman MM, et al. Case-control study of risk of cerebral sinus thrombosis in oral contraceptive users and in [correction of who are] carriers of hereditary prothrombotic conditions. The Cerebral Venous Sinus Thrombosis Study Group. *BMJ.* 1998;316:589–592.
3. Lidegaard O, Lokkegaard E, Svendsen AL, et al. Hormonal contraception and risk of venous thromboembolism: national follow-up study. *BMJ.* 2009;339:b2890.
4. Timmer CJ, Mulders TM. Pharmacokinetics of etonogestrel and ethinylestradiol released from a combined contraceptive vaginal ring. *Clin Pharmacokinet.* 2000;39:233–242.
5. Roumen FJ, op ten Berg MM, Hoomans EH. The combined contraceptive vaginal ring (NuvaRing): first experience in daily clinical practice in The Netherlands. *Eur J Contracept Reprod Health Care.* 2006;11:14–22.
6. Shimoni N, Westhoff C. Review of the vaginal contraceptive ring (NuvaRing). *J Fam Plann Reprod Health Care.* 2008;34:247–250.