




Disponible en ligne sur
 ScienceDirect
 www.sciencedirect.com

Elsevier Masson France
 EM|consulte
 www.em-consulte.com



Letter to the Editor

Non compaction cardiomyopathy: A rare cause of cerebral infarction in a young adult

La non-compaction isolée du ventricule gauche : une rare cause d'infarctus cérébral du sujet jeune

1. Introduction

Isolated left ventricular noncompaction (LVNC) of the myocardium is a rare, genetically heterogeneous, congenital disorder of the endomyocardial morphogenesis. Its prognosis may be poor, with the appearance, frequently in adulthood, of congestive heart failure (HF), life-threatening arrhythmias and systemic thromboembolism in up to 38% of patients (Chin et al., 1990). Transthoracic echocardiography (TTE) leads to the diagnosis as defined by established diagnostic criteria. We describe a patient admitted to our neurovascular intensive care unit for ischemic stroke, in whom an isolated LVNC was diagnosed.

2. Case report

A 33-year-old man was referred to our stroke unit for sudden onset of right facial paralysis and mutism. His NIH stroke scale was 9. Brain MRI was performed 2 hours and 45 minutes after the onset of symptoms. Diffusion-weighted imaging showed a distal left MCA infarct.

There were clinical signs of congestive HF. TTE revealed a dilated left ventricle, a reduced ejection fraction and the characteristic appearance of isolated LVNC, with numerous, excessively prominent trabeculations at the apex (Fig. 1, panel A) and deep intertrabecular recesses (Fig. 1, panel A), filled by blood from the ventricular cavity (Fig. 1, panel B). The injection of a contrast agent (Sonovue®), confirmed the communication between the LV cavity and the recesses (Fig. 1, panel C). The myocardial wall at the apex consisted of a thickened noncompacted (NC) endocardial layer and a thin compacted (C) epicardial layer. The end-systole ratio NC/C was greater than 2 (Fig. 1, panel A). Furthermore, a small mobile mural thrombus was seen at the apex. Transesophageal echocardiography showed no aortic atheroma and no left atrial thrombosis.

Anticoagulation therapy was started and the clinical signs of HF were treated as recommended (diuretics, angiotensin-converting enzyme inhibitors and later β -blockers).

He improved gradually with the persistence of a slight residual dysarthria one month later.

An echocardiographic assessment of first-degree relatives has been counseled.

3. Discussion

LVNC is isolated when it is not associated with other congenital cardiac malformations. It is thought to represent an arrest of the LV myocardial condensation, since the heart is, in the early embryo, a loose interwoven mesh of muscle fibers (Chin et al., 1990). It is a rare disorder, with a reported prevalence between 0.014% (Elliott et al., 2008) and 0.05% (Ritter et al., 1997) in consecutive echocardiograms. In the report of the 1995 World Health Organisation-International Society and Federation of Cardiology task force on the definition and classification of cardiomyopathies (Richardson et al., 1996) as in the update of the European Society of Cardiology Working Group on Myocardial and Pericardial Diseases, LVNC is categorized as an unclassified cardiomyopathy (Elliott et al., 2008).

The disease is frequently familial, with at least a quarter of asymptomatic relatives having a range of echocardiographic features. TTE leads to the diagnosis [1] in the absence of other cardiac anomalies [2] when numerous and excessively prominent trabeculations are documented, in the association with deep intertrabecular recesses [3] these recesses being filled by direct blood flow from the LV cavity (Jenni et al., 2001). Cardiovascular magnetic resonance also allows the diagnostic of isolated LVNC, when showing a ratio NC/C over 2.3 in diastole, with a sensitivity of 86% and a specificity of 99% (Petersen et al., 2005). The deep intertrabecular recesses predispose to LV mural thrombi, especially when the ejection fraction is low, because of the blood stasis, even though the relation between LVNC and stroke has been questioned by some authors (Finsterer et al., 2008).

It is not clear whether a prophylactic anticoagulation is useful in the absence of thromboembolic events but anti-coagulants are warranted after an episode of systemic embolism, especially when a thrombus is seen on echocardiography. In the presence of a LV systolic dysfunction, the recommended treatment of HF should also be initiated. Furthermore, the identification of an index case implies the

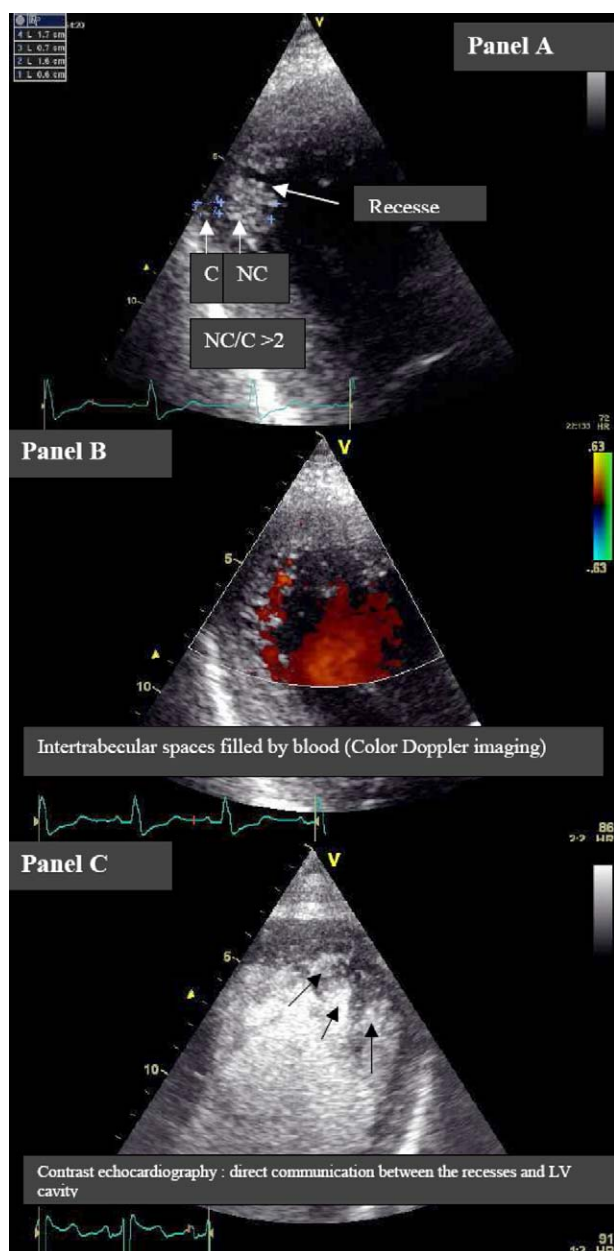


Fig. 1 – Echocardiography. Panel A: prominent trabeculations at the apex and deep intertrabecular recesses, with a thickened noncompacted (NC) endocardial layer and a thin compacted (C) epicardial layer. The end-systole ratio NC/C is greater than 2. Panel B: the recesses are filled by blood from the ventricular cavity. Panel C: the injection of a contrast agent (Sonovue®) shows a communication between the LV cavity and the recesses. *Échocardiographie transthoracique. Planche A : trabéculations proéminentes à l'apex, récessus intertrabéculaires profonds, avec une couche non compactée (NC) et une couche compactée C (NC/C > 2). Planche B : les récessus sont circulants en Doppler couleur. Planche C : l'injection de produit de contraste montre la communication entre la cavité VG et les récessus.*

echocardiographic assessment of first-degree relatives. Finally, more data are needed from stroke units to establish the incidence of cerebrovascular complications of this new cardiomyopathy.

4. Conclusion

Isolated LVNC, a rare congenital cardiomyopathy, is a potential cardiac source of embolism. Early diagnosis allows specific antithrombotic therapy, heart failure therapy when applicable and the assessment of first-degree relatives.

Conflict of interest statement

None.

REFERENCES

- Chin TK, Perloff JK, Williams RG, Jue K, Mohrmann R. Isolated noncompaction of left ventricular myocardium. A study of eight cases. *Circulation* 1990;82:507–13.
- Elliott P, Andersson B, Arbustini E, Bilinska Z, Cecchi F, Charron P, et al. Classification of the cardiomyopathies: a position statement from the European Society Of Cardiology Working Group on Myocardial and Pericardial Diseases. *Eur Heart J* 2008;29:270–6.
- Finsterer J, Stollberger C, Mölzer G, Winkler-Dworak M, Blazek G. Cerebrovascular events in left ventricular hypertrabeculation/noncompaction with and without myopathy. *Int J Cardiol* 2008;130:344–8.
- Jenni R, Oechslin E, Schneider J, Attenhofer Jost C, Kaufmann PA. Echocardiographic and pathoanatomical characteristics of isolated left ventricular noncompaction: a step towards classification as a distinct cardiomyopathy. *Heart* 2001;86:666–71.
- Petersen SE, Selvanayagam JB, Wiesmann F, Robson MD, Francis JM, Anderson RH, et al. Left ventricular noncompaction: insights from cardiovascular magnetic resonance imaging. *J Am Coll Cardiol* 2005;46:101–5.
- Richardson P, McKenna W, Bristow M, Maisch B, Mautner B, O'Connell J, et al. Report of the 1995 World Health Organization/International Society and Federation of Cardiology Task Force on the Definition and Classification of cardiomyopathies. *Circulation* 1996;93:841–2.
- Ritter M, Oechslin E, Sütsch G, Attenhofer C, Schneider J, Jenni R. Isolated noncompaction of the myocardium in adults. *Mayo Clin Proc* 1997;72:26–31.

N. Benyounes^{a,*}, M. Obadia^b, O. Gout^b

^aDepartment of Internal Medicine, Fondation Ophtalmologique Adolphe de Rothschild, 25-29, rue Manin, 75940 Paris cedex 19, France

^bDepartment of Neurology, Fondation Ophtalmologique Adolphe de Rothschild, 25-29, rue Manin, 75940 Paris cedex 19, France

*Corresponding author.

E-mail address: nbenyounes@fo-rothschild.fr (N. Benyounes)

Received 30 august 2010

Received in revised form 19 october 2010

Accepted 26 october 2010

Available online 21 March 2011

0035-3787/\$ – see front matter

© 2011 Elsevier Masson SAS. All rights reserved.

doi:10.1016/j.neurol.2010.10.011