

Case Report

A rare complication in a child undergoing chemotherapy for acute lymphoblastic leukemia: Superior sagittal sinus thrombosis

Ting-Yao Wang^{a,b}, Hsiu-Ju Yen^{a,b,*}, Giun-Yi Hung^{a,b}, Ming-Yun Hsieh^c, Ren-Bin Tang^{a,b}

^aDepartment of Pediatrics, Taipei Veterans General Hospital, Taipei, Taiwan, ROC

^bNational Yang-Ming University School of Medicine, Taipei, Taiwan, ROC

^cDepartment of Pediatrics, Far Eastern Memorial Hospital, Taipei, Taiwan, ROC

Received June 7, 2010; accepted September 10, 2010

Abstract

We report the case of a 4-year-old boy with acute lymphoblastic leukemia in high-risk group who suffered from generalized tonic-clonic seizure evolving into status epilepticus, and subsequent left hemiparesis during his first reinduction chemotherapy, consisting of dexamethasone, vincristine, L-asparaginase, and epirubicin. Superior sagittal sinus and cerebral venous thrombosis, predominantly in right side, were proved by brain magnetic resonance imaging. After aggressive treatment with low-molecular weight heparin (LMWH), left hemiparesis improved in 1 week. And he was fully ambulatory 3 weeks later. The second cycle of reinduction chemotherapy was conducted smoothly with the concomitant use of LMWH. This case illustrates the strong correlation of the rare thrombotic complication, superior sagittal sinus thrombosis, and hypercoagulable status secondary to combination use of L-asparaginase and corticosteroid. Early and vigilant recognition of superior sagittal sinus thrombosis and prompt anticoagulation with LMWH may prevent further neurological damage.

Copyright © 2011 Elsevier Taiwan LLC and the Chinese Medical Association. All rights reserved.

Keywords: Acute lymphoblastic leukemia; L-Asparaginase; Superior sagittal sinus thrombosis

1. Introduction

Leukemia is the most common childhood malignancy worldwide, and acute lymphoblastic leukemia (ALL) comprises most pediatric leukemias. With risk-adapted intensive chemotherapy, the cure rate of pediatric ALL approaches nearly 80%. However, this intensive treatment may also bring about a number of significant morbidities during chemotherapy treatment. Thromboembolic events comprise a great number of morbidities in ALL patients. Most of the thromboembolic events are central venous catheter-related thrombosis. Superior sagittal sinus thrombosis (SSST) is a rare complication. Here, we report a case of SSST in a child undergoing his first reinduction chemotherapy for ALL. The correlation of SSST with

hypercoagulable status and underlying hyperlipidemia, and treatment and prophylaxis of SSST are discussed here.

2. Case report

A 4-year-old boy was diagnosed with ALL at our hospital with the initial presentations of productive cough and intermittent high-grade fever for 2 weeks. His initial white blood cell count was 64,490/ μ L, and bone marrow examination revealed around 50% lymphoblasts, which were positive for CD19 and CD10. Port-A central venous catheter was implanted over left upper chest after diagnosis. He received induction, consolidation, and continuation chemotherapy with TPOG-ALL-2002 high-risk protocol without delay. Six months after diagnosis, he started reinduction chemotherapy (dexamethasone 8 mg/m² on Days 1–8 and 15–21; epirubicin 30 mg/m² on Days 1 and 8; vincristine 1.5 mg/m² on Days 1, 8, and 15; L-asparaginase 5,000 ku/m² every other day for nine doses; triple intrathecal chemotherapy with methotrexate

* Corresponding author. Dr. Hsiu-Ju Yen, Department of Pediatrics, Taipei Veterans General Hospital, 201, Section 2, Shih-Pai Road, Taipei 112, Taiwan, ROC.

E-mail address: hjyen2@vghtpe.gov.tw (H.-J. Yen).

12 mg, hydrocortisone 24 mg, and cytarabine 36 mg on Day 1). During this course of reinduction chemotherapy, only mild skin rash developed after intramuscular injection of L-asparaginase.

However, he developed generalized tonic-clonic seizure attack lasting a few minutes soon after completion of the first reinduction chemotherapy course. Furthermore, generalized tonic-clonic seizure attacks took place and evolved into status epilepticus. Left hemiparesis was noted after these episodes. His parents reported that the patient has neither past history of epilepsy or febrile convulsion, nor any family history of hypercoagulable status. The patient did not have symptoms or signs of acute infection. His activity and appetite was quite well before the seizure.

His initial blood counts at our pediatric emergency department were as follows: white blood cell $5,307/\text{mm}^3$ with 34% neutrophils, 40% lymphocytes, and 24% monocytes, hemoglobin 9.2 g/dL, and platelet $153,000/\text{mm}^3$. Serum electrolytes, biochemistry tests, prothrombin time, activated partial thromboplastin time, and C-reactive protein were within normal limits. The computed tomography revealed an essentially normal brain. After admission, increased opening pressure to 384 mmH₂O was measured by lumbar puncture. The glucose and protein levels in cerebrospinal fluid were 54 and 26.1 mg/dL. No leukocytes, but red blood cells ($117/\text{mm}^3$) were identified in cerebrospinal fluid. Because of clinical suspicion of herpes simplex virus encephalitis, acyclovir and intravenous immunoglobulin were prescribed. Meanwhile, low-molecular weight heparin (LMWH, enoxaparin sodium, Clexane; Aventis Intercontinental, Maisons-Alfort Cedex, France) 1 mg/kg/dose twice daily was initiated for concern of possible thrombosis secondary to hypercoagulable status after combined use of L-asparaginase and dexamethasone. His coagulation profile on the next day was as follows: prothrombin time 10.9 seconds, activated partial thromboplastin time 29.9 seconds, D-dimer 1.8 ug/mL, fibrinogen 307 mg/dL, cholesterol 152 mg/dL, and triglyceride (TG) 154 mg/dL. Electroencephalography showed diffuse cortical dysfunction especially over right hemisphere. Brain magnetic resonance imaging (MRI) on the next day showed some foci of filling defect in the lumen of the superior sagittal sinus with “empty-delta” sign on T2-weighted images (Fig. 1). SSST with acute venous infarction in right anterolateral and parasagittal frontal regions of the brain were diagnosed.

After treatment with LMWH, mannitol, and antiepileptic drugs, his left-side hemiparesis improved within 1 week after hospitalization, and he was fully ambulatory 3 weeks later. Further anticoagulation medication with LMWH in the therapeutic dose (enoxaparin 1 mg/kg twice daily) was maintained. The brain MRI 3 months later showed encephalomalacia with resolution of most intraluminal filling defect (Fig. 2). He went through his second reinduction chemotherapy smoothly with the concomitant use of LMWH in the prophylactic dose (enoxaparin 1 mg/kg once daily). Six months after this episode of SSST, we stopped LMWH after completion of the second reinduction chemotherapy for nearly complete resolution of thrombosis demonstrated by brain MRI (Fig. 3) and no clinical

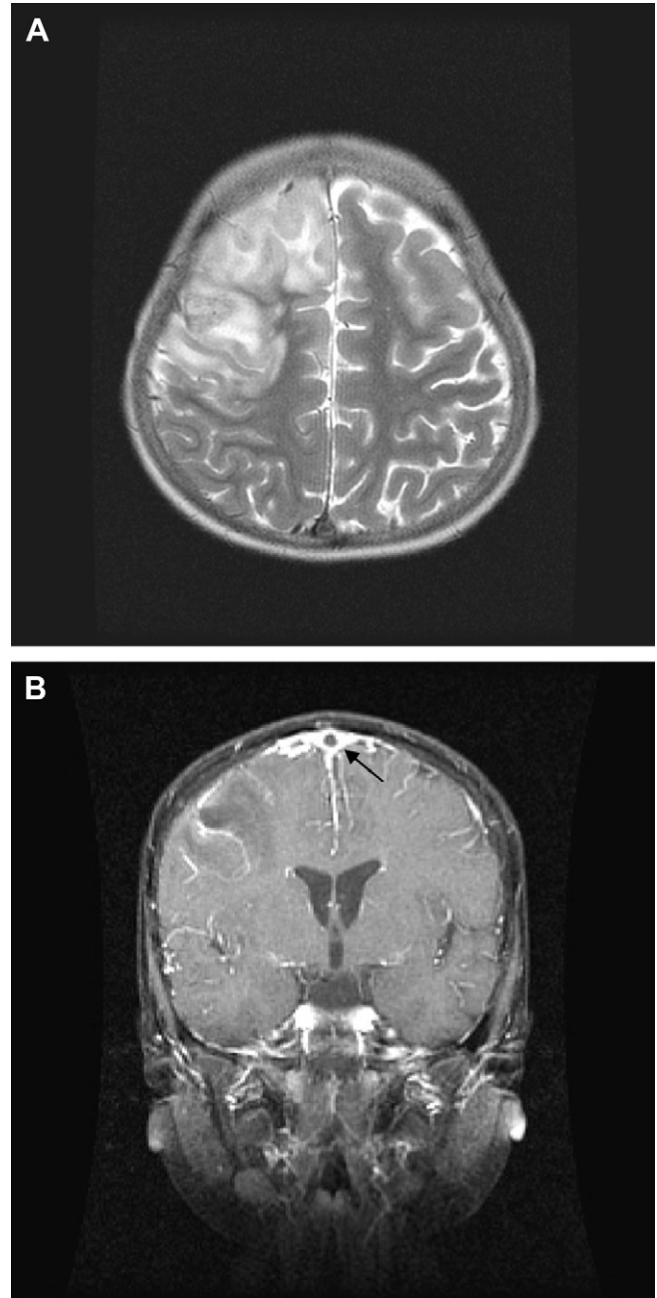


Fig. 1. (A) Axial T2-weighted magnetic resonance imaging shows acute infarction involving right anterolateral and parasagittal frontal lobe and some foci of hemorrhage inside with “bright-up” on diffusion-weighted images. (B) Coronal T1-weighted magnetic resonance imaging reveals low-attenuating thrombus (arrow) within the superior sagittal sinus with “empty-delta” sign, surrounded by a triangular area of enhancement.

symptoms or signs related to thrombosis. In the next few days, he developed a limping gait again, which resolved completely in 1 week after reinitiation with prophylactic LMWH for 1 more month. He had his further continuation chemotherapy without similar adverse events. The thrombophilia screening after discontinuation of LMWH showed protein C 133%, protein S 66%, antithrombin III (AT-III) 135%, and serum homocysteine 4.78 umol/L.

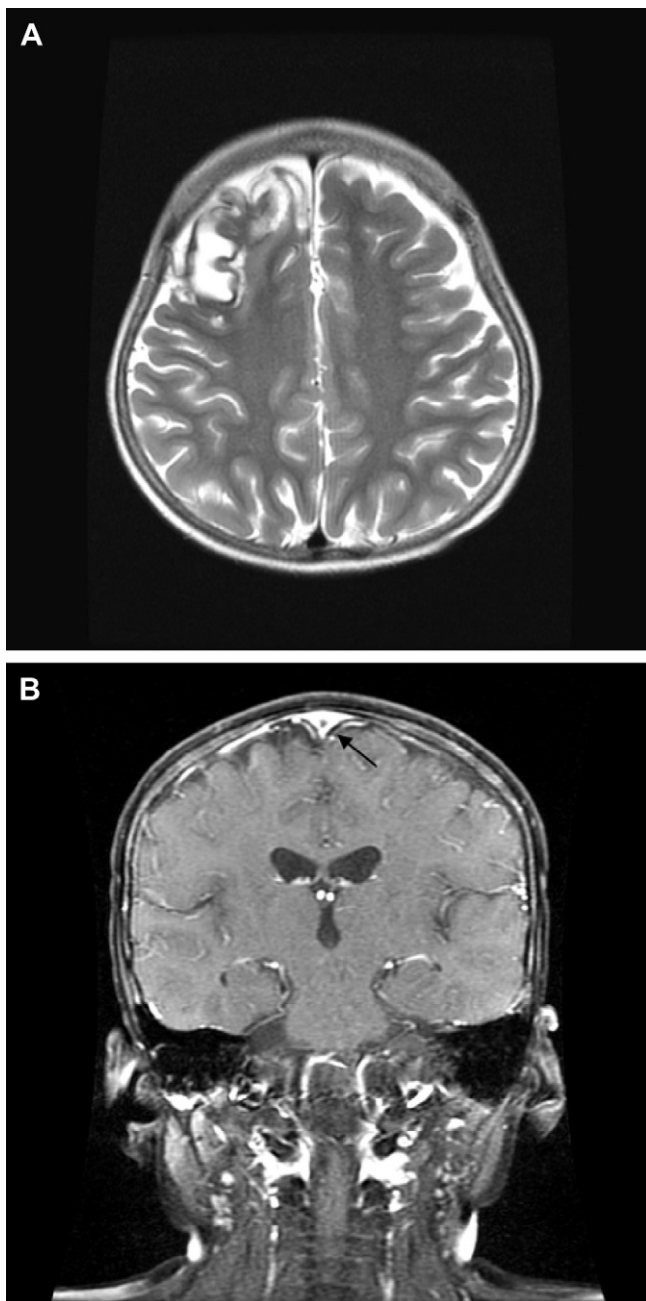


Fig. 2. Three months after superior sagittal sinus thrombosis episode. (A) Axial T2-weighted magnetic resonance imaging shows that the bright-up on diffusion-weighted images was resolving gradually. (B) Coronal T1-weighted magnetic resonance imaging reveals resolution of the low-attenuating thrombus (arrow) within the superior sagittal sinus.

3. Discussion

ALL is the most common malignancy in childhood. With modern intensive chemotherapy, the overall cure rate in ALL children is around 80% at the expense of inevitable morbidity, and possible mortality caused by chemotherapeutic agents, placement of central venous catheter, and infections related to ALL treatment.¹ Mechanisms for thromboembolic events in ALL children include the disease itself, exposure to a combination of steroids and L-asparaginase during induction, and

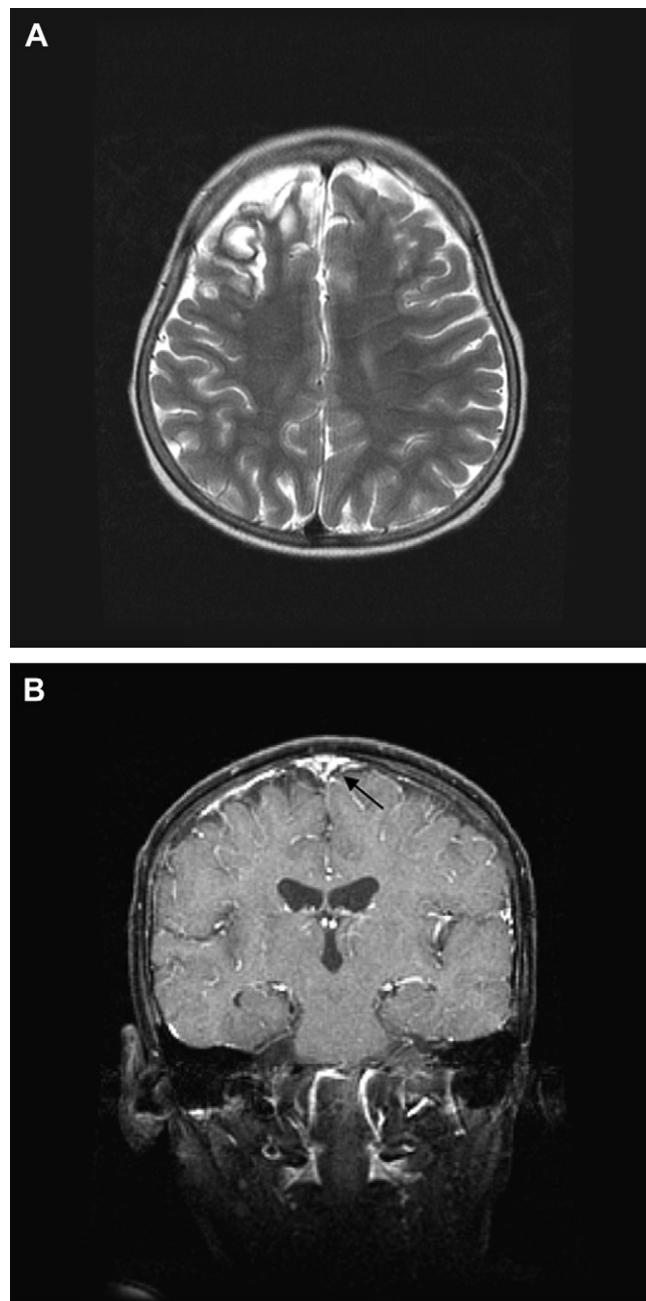


Fig. 3. Six months after superior sagittal sinus thrombosis episode. (A) Axial T2-weighted magnetic resonance imaging shows encephalomalacic tissue loss in right anterior high frontal lobe with hemosiderin deposition. (B) Coronal T1-weighted magnetic resonance imaging reveals nearly total resolution of superior sagittal sinus thrombosis.

early insertion of central venous catheters, increased thrombin generation at diagnosis combined with reduced thrombin inhibitory capacity, and congenital or acquired prothrombotic risk factors.² Venous thrombosis is more frequent in patients treated for ALL than other malignancies. Most symptomatic thromboses is related to central venous catheters and may rarely involve the central nervous system.

SSST has been reported to be caused by coagulopathy following disseminated intravascular coagulation, infection around the sinus, compression from a tumor, infiltration of

tumor, and an inherited deficiency of proteins C and S. But SSST associated with hematological malignancies and L-asparaginase therapy is rare.

L-Asparaginase is a major component in effective ALL treatment. Its well-known adverse effects include allergic reactions, hyperglycemia, pancreatitis, thrombosis, coagulopathy, and hyperbilirubinemia. The inhibition of protein synthesis caused by L-asparaginase is thought to be the basis of its antineoplastic effect, but it also leads to the depletion of other plasma proteins involved in coagulation and fibrinolysis.³ Vicarioto et al.⁴ studied fibrinogen and AT-III sequentially during remission induction in 20 ALL children. There was a significant decrease in the plasma fibrinogen and AT-III in the first 2 weeks. All parameters gradually returned to normal after completion of therapy. Impaired thrombin inhibition by anticoagulant deficiency has been proposed as the main pathogenesis of thrombosis in ALL treatment.⁵ We did not have the protein C, S, and AT-III data before starting LMWH because the preemptive usage of LMWH before SSST was diagnosed by image. But normal thrombophilia screening after the episode excluded the possibility of congenital causes of thrombophilia.

Hyperlipidemia is known to be one of the risk factors for cerebral venous sinus thrombosis. Parsons et al.⁶ studied the fasting lipid and lipoprotein levels in 43 ALL children receiving L-asparaginase and corticosteroid therapy. The mean peak TG level was significantly higher than the level before therapy. A striking temporal association between L-asparaginase therapy and hypertriglyceridemia was observed.⁶ Corticosteroids alone can induce the production of TG-rich particles and activity of lipoprotein lipase (LPL), which may prevent extreme rise in TG on corticosteroid therapy.⁷ But dramatic decline of LPL activity after L-asparaginase results in extensive hypertriglyceridemia,⁷ which may also contribute to the prothrombotic diathesis. The mechanism by which L-asparaginase exerts its effect on LPL activity is not known. It may act by means of a reduction in protein synthesis.⁷

Why did our patient develop SSST during reinduction chemotherapy? First, the deranged coagulation secondary to L-asparaginase and corticosteroid in reinduction chemotherapy may trigger this event. His preference for greasy and high-calorie meals led to the high body mass index 18.77, which is just above the 90–95th percentile of his age- and sex-matched levels.⁸ And combination usage of L-asparaginase and corticosteroid had further impact on the preexisted hyperlipidemia, and led to high fasting TG levels 195 mg/dL, which is above the 95th percentile of his age- and sex-matched levels (TG: 85 mg/dL).⁹ All these factors contributed to prothrombotic diathesis and eventually resulted in SSST episode.

Thrombotic events occur because of a combination of disease-, host- and treatment-related risk factors in ALL patients. Idiopathic venous thrombosis in childhood is rare. Apart from a much higher risk in neonates, it is unclear if age is a risk factor. However, high-risk disease is also associated with a higher risk of thrombosis. Age-related risk may partly reflect the effect of ALL-risk stratification and more intensive treatment.² Abbott et al.¹⁰ found a disproportionate number of

Asian children who developed a central nervous system thrombosis, although no statistically significant. They suggested race might be examined to see if it is a predisposing factor for thromboses associated with L-asparaginase with the expected divergence in inherited polymorphisms.

Chemotherapeutic agents given during induction or intensification courses may influence the hemostasis based on the observation that more than 90% ALL thrombosis occurred during the aforementioned courses, not at diagnosis. Asparaginase preparation, length of exposure, and dose may play a role in ALL thrombosis.² As to different glucocorticoids, no statistically significant difference in thrombosis incidence could be demonstrated.² Central venous line placement and inherited thrombophilia increase the thrombotic risk in ALL patients.²

Because the reported thrombosis incidence varies from 1% to 36%, various efforts were tried to prevent the thrombosis. Cohen et al.¹¹ reported neurologic complications associated with asparaginase-induced hypertriglyceridemia in two ALL children with extremely high TG levels. They suggested routine monitoring of fasting TG levels in all children before and during asparaginase treatment. Early detection of elevated levels will enable the introduction of conservative treatment, and the prevention of further increase of TG to decrease the risk of potential complication.

Prophylactic fresh frozen plasma and cryoprecipitate had been administered to prevent thrombotic and hemorrhagic complications on ALL patients undergoing chemotherapy with L-asparaginase by Abbott et al.¹⁰ They measured AT-III and fibrinogen level and transfused prophylactic fresh frozen plasma and cryoprecipitate if AT-III >50 u/mL or fibrinogen <100 mg/dL. They concluded prophylaxis is unwarranted for unselected ALL patients.¹⁰

The mainstay management for SSST is anticoagulation and supportive care. Anticoagulation treatment with heparin, warfarin, urokinase, or LMWH is widely used to treat various conditions associated with thrombosis. Usage of LMWH has its advantages of predictable pharmacokinetics, requirement of less frequent monitoring, low risk of heparin-induced thrombocytopenia and osteoporosis, allowance of out-patient treatment, and less drug-drug interaction with the ALL chemotherapy.² Payne and Vora² recommend that anticoagulation with LMWH over warfarin for SSST in the setting of ALL. Twice daily therapeutic dose (maintaining anti-Xa level at 0.5–1.0 IU/mL) for 1–3 months is required to treat SSST. Prophylactic usage with LMWH on once daily dose (maintaining anti-Xa level at 0.1–0.3 IU/mL) is started from the day before reexposure to L-asparaginase, and maintained until 1 week after completing course.²

Because his limping gait developed 3 days after completion of the second reinduction chemotherapy and discontinuation of LMWH, and improved greatly after reapplication of prophylactic LMWH, we suggest that the deranged coagulation disorder may persist for a few more days to weeks even after completion of L-asparaginase treatment. Further prophylactic usage with LMWH for a few more weeks after L-asparaginase and steroid treatment is warranted to minimize occult thromboembolic

events, which may not be well demonstrated in brain imaging studies.

In conclusion, thromboembolic complications are not uncommon during the treatment period of ALL, especially during remission induction period. The rare complication, SSST, secondary to combination use of L-asparaginase and dexamethasone should be kept in mind to facilitate timely diagnosis and treatment, and to avoid further neurological damage. Anticoagulation therapy with LMWH is effective for SSST with its advantages of predictable pharmacokinetics and less drug-drug interaction in the setting of ALL treatment. Prophylactic usage of LMWH in ALL patients, who had ever developed SSST, during reexposure to L-asparaginase and steroid should be adopted and extended to a few weeks after the completion of reinduction chemotherapy to minimize the recurrence of SSST.

References

1. Tubergen DG, Bleyer A. The leukemias. In: Kliegman RM, Behrman RE, Jenson HB, Stanton BF, editors. *Nelson textbook of pediatrics*. 18th ed. Philadelphia (PA): Saunders Elsevier; 2007. p. 2116–20.
2. Payne JH, Vora AJ. Thrombosis and acute lymphoblastic leukaemia. *Br J Haematol* 2007;**138**:430–45.
3. Feinberg WM, Swenson MR. Cerebrovascular complications of L-asparaginase therapy. *Neurology* 1988;**38**:127–33.
4. Vicarioto M, Rosolen A, Cappellato MG, Zanescio L, Girolami A. Greater decrease of fibrinogen as compared to antithrombin III in L-asparaginase treated leukemia patients. *Folia Haematol Int Mag Klin Morphol Blutforsch* 1986;**113**:663–9.
5. Mitchell LG, Sutor H, Andrew M. Hemostasis in childhood acute lymphoblastic leukemia: coagulopathy induced by disease and treatment. *Semin Thromb Hemost* 1995;**21**:390–401.
6. Parsons SK, Skapek SX, Neufeld EJ, Kuhlman C, Young ML, Donnelly M, et al. Asparaginase-associated lipid abnormalities in children with acute lymphoblastic leukaemia. *Blood* 1997;**89**:1886–95.
7. Hoogerbrugge N, Jansen H, Hoogerbrugge PM. Transient hyperlipidemia during treatment of ALL with L-asparaginase is related to decreased lipoprotein lipase activity. *Leukemia* 1997;**11**:1377–9.
8. Kuczumski RJ, Ogden CL, Guo SS, Grummer-Strawn LM, Flegal KM, Mei Z, et al. 2000 CDC growth charts for the United States: methods and development. *Vital Health Stat 11* 2002;**246**:1–190.
9. Daniels SR, Greer FR. Committee on nutrition. Lipid screening and cardiovascular health in childhood. *Pediatrics* 2008;**122**:198–208.
10. Abbott LS, Deevska M, Fernandez CV, Dix D, Price VE, Wang H, et al. The impact of prophylactic fresh-frozen plasma and cryoprecipitate on the incidence of central nervous system thrombosis and hemorrhage in children with acute lymphoblastic leukemia receiving asparaginase. *Blood* 2009;**114**:5146–51.
11. Cohen H, Bielora B, Harats D, Toren A, Pinhas-Hamiel O. Conservative treatment of L-asparaginase-associated lipid abnormalities in children with acute lymphoblastic leukemia. *Pediatr Blood Cancer* 2010;**54**:703–6.