


Seizures Triggered by July 4th Fireworks in an 8-Year-Old Girl With Perinatal Stroke

Journal of Child Neurology
26(5) 638-641
© The Author(s) 2011
Reprints and permission:
sagepub.com/journalsPermissions.nav
DOI: 10.1177/0883073810387927
http://jcn.sagepub.com


Jared R. Brosch, MD, MSc¹, and Meredith R. Golomb, MD, MSc¹

Abstract

Warnings regarding fireworks displays as a possible seizure-producing stimulus have been around for several years, but there is a lack of well-documented cases. This case describes photic- and/or pattern-induced seizures that appeared to be triggered by July 4 fireworks. This 8-year-old girl with hemiplegic cerebral palsy and known seizure disorder because of perinatal right middle cerebral artery stroke had a cluster of seizures within minutes of the onset of a professional fireworks display. The seizures stopped when the child's eyes were covered and she was taken away from the scene. The importance of photic- and pattern-induced seizures in children is discussed.

Keywords

fireworks, epilepsy, photosensitivity, seizure, absence

Received September 1, 2010. Received revised September 27, 2010. Accepted for publication September 28, 2010.

Photic- and pattern-induced seizures can occur in both generalized and focal epilepsies. They may be more common in children than adults. Photosensitivity on electroencephalogram can be demonstrated in up to 46% of patients with generalized epilepsy and 20% of children with focal epilepsy.¹ The range of stimuli that can provoke a photic- or pattern-induced seizure is wide. Previously reported stimuli include television (video games, commercials, cartoons), strobe-lights, waving fingers across the eyes, and reflections of light.^{2,3} Although there have been recent warnings that fireworks displays can be a possible cause of photic-induced seizures,⁴ actual cases have not been well documented in the literature.

Case Report

An 8-year-old girl with a history of hemiplegic cerebral palsy and epilepsy because of perinatal stroke presented in follow-up to our clinic for multiple seizure events, which occurred on July 4, 2010. The child is a probable dizygotic twin who had a large perinatal right middle cerebral artery stroke and has attention deficit hyperactivity disorder treated with lisdexamfetamine. Prior magnetic resonance imaging (MRI) of the brain showed encephalomalacia primarily in the right temporoparietal lobe (Figure 1) with surrounding gliosis from prior infarction and ex vacuo dilatation of the atria of the right lateral ventricle. She had no history of seizures until the parents reported staring spells starting in 2009. She had a normal electroencephalogram in July 2009, including normal response to intermittent photic stimulation in the range of 1 Hz to 30 Hz.

Her family reported an increasing number of staring spells in early 2010 and a video electroencephalogram in June 2010 showed frequent independent right occipital and less frequent left temporal and central vertex epileptiform discharges, placing her at risk for focal and secondarily generalized seizures (no photic stimulation was performed during the video electroencephalogram). She was started on oxcarbazepine on June 11, 2010 with the dose increased over 2 weeks to 20 mg/kg divided twice daily. After a staring spell with rapid eye blinking on June 29, 2010, oxcarbazepine level was checked and found to be slightly low (10.2 µg/mL, therapeutic = 15-36 µg/mL) so the dose was increased to 35 mg/kg divided twice daily.

On July 4, 2010 our patient was at a large professional outdoor fireworks display, which occurred after dusk. Approximately 5 minutes into the display, the patient developed rapid eye blinking, followed by rapid eye movements, and followed by a staring spell lasting approximately 10 to 15 seconds, as noted by her mother. The patient went on to have 5 total events, minutes apart, all identical to the first except the last episode where the patient's eyes rolled back and her whole

¹ Indiana University School of Medicine, Department of Neurology, Division of Pediatric Neurology, Indianapolis, Indiana, USA

Corresponding Author:

Meredith R. Golomb, MD, MSc, Indiana University School of Medicine, Building XE, Room 040, 575 West Drive, Indianapolis, IN 46202
Email: mgolomb@iupui.edu

body stiffened. Her mother grabbed her, hugging the child's face into her chest to cover her eyes. The mother noted that the child's heart rate was high and brought her to the local emergency room. The child did not continue to have seizures in the emergency room and no medications were required to stop the episodes. Her electrolytes, calcium, magnesium, and complete blood cell count were all unremarkable; oxcarbazepine level was not sent. An oxcarbazepine level at her follow-up neurology appointment on July 7, 2010 was therapeutic (30 $\mu\text{g/mL}$, therapeutic = 15-36 $\mu\text{g/mL}$). The mother reported good compliance with the child's antiepileptic medication, no sleep deprivation prior to the event, and no seizure events during home fireworks earlier in the day, including sparklers and bottle rockets. The patient's twin sister was at all of the events and did not have any reaction to the same fireworks display. The parents reported that the first 15 minutes of the professional fireworks display were very much like a "finale" with a constant barrage of multicolored fireworks illuminating a significant portion of the night sky. The child had a follow-up electroencephalogram on August 11, 2010, which showed findings similar to her last electroencephalogram and no response to photic stimulation. She had no further seizures in the month after July 4.

Discussion

The child in this case appears to have had a series of seizures precipitated by the viewing of fireworks. Previous work suggests that she is among those at the highest risk for a photic- or pattern-induced seizure because of her age (more common in children²), gender (female:male risk is approximately 2:1),⁵ and history of epilepsy. Although genetics can play a role in the development of photoconvulsive events,⁶ this child does not have a family history of such events.

Warnings regarding fireworks have been published despite the dearth of reported cases because fireworks displays combine many of the characteristics of both photic and pattern stimuli known to provoke seizures. The 2 most important characteristics of photic stimuli (flicker) are brightness (intensity, contrast, visual field) and repetition rate.² Fireworks generate intense light and close proximity to the display area increases not only the light intensity but the amount of light in the overall visual field, which further increases the risk of inducing seizures.⁷ The high-contrast stimulation of a fireworks show (bright flashes on a dark sky) would likely make the available light intensity more seizure-inducing.⁸ Fireworks displays have variable flash rates, with the most frequent flashing generally occurring during the "finale" of a show. Our patient's mother reported that the beginning of the fireworks show, which seemed to induce her child's seizures, was similar to a finale, with many rapidly launched bright fireworks. The most provocative repetition rate for generation of photosensitive individuals is between 15 and 25 cycles per second, though many individuals have seizures that are provoked by lower and higher rates.⁵ Fireworks may also have the ability to provoke photosensitive individuals by patterns. Multiple fireworks that overlap can create flashing vertical and horizontal

lines with high contrast, which could create a provocative pattern similar to those seen in documented experiments.⁹

There are many well-documented cases of seizures triggered by other photic and patterned stimuli. On December 16, 1997, 685 children and adults in Japan visited the hospital after watching an episode of *Pokemon*, which had approximately 4 seconds of alternating blue/red flashes at 12 Hz.¹⁰ Most of these patients had a seizure. A follow-up study of 95 of these children found that about one quarter of the children with seizure events had a history of epilepsy.¹¹ Furthermore, only 43% of the 81 children given an electroencephalogram with photic stimulation had a photoparoxysmal response.¹¹ This suggests that our patient's lack of photic response on electroencephalogram does not exclude a photic or patterned trigger (the fireworks) for her seizures. The World Wide Web Consortium has published guidelines on ways to minimize or prevent a potential seizure-inducing flicker.¹² However, with the advent of YouTube and other online video sharing sites, potentially epileptogenic videos live on. Children can easily view many of these videos online, including the banned *Pokemon* episode,¹³ the "Golden Wonder Pot Noodles" advertisement,¹⁴ which induced seizures in 3 people in the United Kingdom during its first showing, and many other intentionally composed seizure-inducing videos.¹⁵⁻¹⁷ (The authors suggest that readers have someone else present nearby if they decide to watch them.)

For patients, preventing future photic- and pattern-induced seizures is a major priority. The primary form of prevention is the avoidance of photic/pattern stimuli that may lead to such events. For many patients, avoiding video games, television, and fireworks displays (especially when a twin sister is allowed to attend) may not be desirable or possible. There are several other potential approaches that involve modifying the way potentially seizure-provoking stimuli are viewed. One method to avoid or possibly abort this type of seizure is to cover 1 eye with a hand, decreasing the amount of visual stimuli received.⁴ Closing 1 or both eyes without using a hand to block out all light may actually increase the risk of a seizure.¹⁸ Some patients have a visual disturbance prior to a seizure event¹⁹ and can use this opportunity to try to prevent a seizure by covering 1 eye. Changing the distance from a visual stimulus or using an optical filter may also be effective. The current recommendations for viewing television in those that are photosensitive are to be seated greater than 2 meters from the screen, watch television in a well-lit room, and only approach the television with 1 eye covered.² In recent studies, covering the eyes with optical filters has shown excellent efficacy in preventing seizures. The optical filters that are most effective are either neutral density filters (with good attenuation of red light) or filters that are completely reflective of red light.²⁰ Several authors have shown excellent attenuation of photic-induced seizures using blue glasses²¹ (which filter red light), polarized/cross-polarized glasses,²² or polarized blue glasses.²³

Anticonvulsants can also be chosen to prevent photic- or pattern-induced seizures, as some may be more effective than others in preventing seizure events. The child in this case was therapeutic on oxcarbazepine but had a seizure that appeared

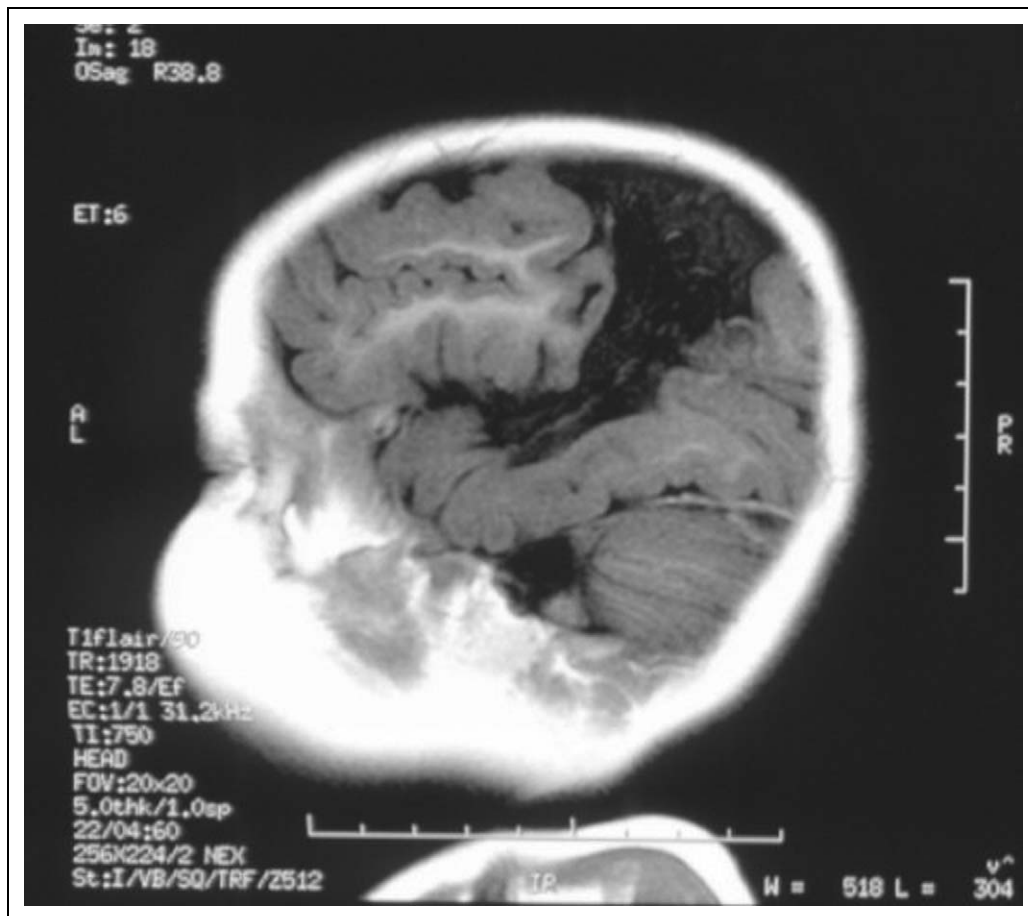


Figure 1. Image shows the T1 FLAIR sagittal magnetic resonance imaging (MRI) of the right hemisphere of our patient.

to be triggered by photic/pattern stimulation from fireworks. Valproic acid has been shown to completely abolish photo-sensitivity in approximately half of all photo-sensitive patients and attenuates the response in another 25% to 30% of those treated.²⁴ Valproic acid was not considered for the patient in this case because of the potential side effects including weight gain, hair loss, and teratogenicity. Clonazepam²⁵ may also attenuate the photosensitive response, but it was not considered for this patient because of its sedative effects.

It is possible that the occurrence of our patient's seizures during the onset of a fireworks display was coincidental and not triggered by fireworks. However, the fact that they started within minutes of the onset of the show and stopped when her eyes were covered is highly suggestive. Our failure to capture a photosensitive response during electroencephalograms does not rule out photosensitivity as a seizure trigger. Several factors may confound the capturing of a photoparoxysmal response during electroencephalogram, including testing variation, medications that alter neural response, insufficient photic or pattern stimuli, and physiologic variability.^{2,10,11} An additional consideration is that the patient's perinatal stroke appears to affect visual association areas in the parietal and temporal lobes (see Figure 1). This may increase her susceptibility to visually provoked seizures. While it is possible that her seizures were

triggered by sound²⁶ and were a form of startle seizure, her lack of epileptogenic response to the many fireworks set off in her backyard earlier that day argues against this. However, we did suggest to the mother that our patient bring earplugs to the fireworks next year.

This case supports the published warnings that professional fireworks displays may provoke seizures. Our patient wants to watch the fireworks next year, and we have discussed the many potential ways to prevent or stop photic- and pattern-induced seizures with her and her family. We hope to help her get through next year's July 4 celebrations without a trip to the emergency room.

Acknowledgments

The authors would like to thank Dr Giuseppe Erba for discussing this case with us. We would also like to thank Sharon Sears for coordinating and supervising the patient's electroencephalographies (EEGs) with photic stimulation.

Author Contributions

JRB generated the first full draft and edited subsequent drafts until the final draft was produced. MRG provided the case and mentored JRB through the process, giving feedback and editing each draft until the final draft was produced.

Declaration of Conflicting Interests

The authors declared no potential conflicts of interest with respect to the authorship and/or publication of this article.

Funding

The authors disclosed receipt of the following financial support for the research and/or authorship of this article: Dr Golomb was supported by an Indiana University Research Support Funds Grant and by the Department of Neurology at Indiana University School of Medicine.

References

- Lu Y, Waltz S, Stenzel K, et al. Photosensitivity in epileptic syndromes of childhood and adolescence. *Epileptic Disord.* 2008;10:136-143.
- Fisher RS, Harding G, Erba G, et al. Photic- and pattern-induced seizures: a review for the epilepsy foundation of america working group. *Epilepsia.* 2005;46:1426-1441.
- Brinciotti M, Matricardi M, Pelliccia A, Trasatti G. Pattern sensitivity and photosensitivity in epileptic children with visually induced seizures. *Epilepsia.* 1994;35:842-849.
- Rickey T, Erba G. Damping the odds that fireworks will spark seizures. <http://www.urmc.rochester.edu/news/story/index.cfm?id=1581>. Accessed August 2, 2010.
- Harding GFA, Harding PF. Televised material and photosensitive epilepsy. *Epilepsia.* 1999;40:65-69.
- Harding GFA, Edson A, Jeavons PM. Persistence of photosensitivity. *Epilepsia.* 1997;38:663-669.
- Leijten FSS, Dekker E, Spekreijse DGA, et al. Light diffusion in photosensitive epilepsy. *Electroencephalogr Clin Neurophysiol.* 1998;106:387-391.
- Hishikawa Y, Yamamoto J, Furuya E, et al. Photosensitive epilepsy: relationships between the visual evoked responses and the epileptiform discharges induced by intermittent photic stimulation. *Electroencephalogr Clin Neurophysiol.* 1967;23:320-334.
- Wilkins AJ, Darby CE, Binnie CD. Neurophysiological aspects of pattern-sensitive epilepsy. *Brain.* 1979;102:1-25.
- Ishida S, Yamashita Y, Matsuishi T, et al. Photosensitive seizures provoked while viewing "pocket monsters," a made-for-television animation program in japan. *Epilepsia.* 1998;39:1340-1344.
- Takada H, Aso K, Watanabe K, et al. Epileptic seizures induced by animated cartoon, "pocket monster." *Epilepsia.* 1999;40:997-1002.
- World Wide Web Consortium. Web content accessibility guidelines (WCAG) 2.0. 2008; <http://www.w3.org/TR/WCAG20/#seizure>. Accessed August 25, 2010.
- Pokemon seizure moment. <http://www.youtube.com/watch?v=qOG-HKjp5h0>. Accessed August 4, 2010.
- Banned pot noodle advert - ace of spades. <http://www.youtube.com/watch?v=Bs0WCUZqoJg>. Accessed August 4, 2010.
- Faster strobe light [extreme seizure warning]. <http://www.youtube.com/watch?v=AjbrmfjJRk0>. Accessed August 4, 2010.
- Have a "seizure." <http://www.youtube.com/watch?v=RFGE0H WoyHk>. Accessed August 4, 2010.
- Get a pokeseizure while I play inappropriate music. <http://www.youtube.com/watch?v=fj5vhFfFW0I>. Accessed August 4, 2010.
- Harding GFA, Jeavons PM. *Photosensitive Epilepsy*. 2nd ed. London: MacKeith Press; 1994.
- Hennessy MJ, Binnie CD. Photogenic partial seizures. *Epilepsia.* 2000;41:59-64.
- Takahashi Y, Sato T, Goto K, et al. Optical filters inhibiting television-induced photosensitive seizures. *Neurology.* 2001;57:1767-1773.
- Capovilla G, Beccaria F, Romeo A, et al. Effectiveness of a particular blue lens on photoparoxysmal response in photosensitive epileptic patients. *Ital J Neurol Sci.* 1999;20:161-166.
- Jain S, Woodruff G, Bissessar EA. Cross polarized spectacles in photosensitive epilepsy. *J Pediatr Ophthalmol Strabismus.* 2001;38:331-334.
- Kepecs MR, Boro A, Haut S, et al. A novel nonpharmacologic treatment for photosensitive epilepsy: a report of three patients tested with blue cross-polarized glasses. *Epilepsia.* 2004;45:1158-1162.
- Harding GFA, Herrick CE, Jeavons PM. A controlled study of the effect of sodium valproate on photosensitive epilepsy and its prognosis. *Epilepsia.* 1978;19:555-565.
- Saenz-Lope E, Herranz-Tanarro FJ, Masdeu JC, Bufil J. Familial photosensitive epilepsy: effectiveness of clonazepam. *Clin Electroencephalogr.* 1984;15:47-52.
- Engel J. A proposed diagnostic scheme for people with epileptic seizures and epilepsy: report of the ILAE task force on classification and terminology. *Epilepsia.* 2001;42:796-803.