

# Cerebral Venous Sinus Thrombosis Presenting With Auditory Hallucinations and Illusions

Victoria S.S. Wong, MD,\* Peter Adamczyk, MD,\*† Brian Dahlin, MD,‡ David P. Richman, MD,\* and Vicki Wheelock, MD\*

**Objective:** Cerebral venous sinus thrombosis may present with seizures or neuropsychiatric symptoms, but does not typically present with hallucinations. We present a case of venous thrombosis of the right sigmoid and transverse sinuses that presented with auditory hallucinations and illusions.

**Methods:** We describe a 45-year-old woman with a history of myasthenia gravis, stable on oral prednisone and monthly intravenous immunoglobulin infusions, who started on a progesterone/estrogen combination contraceptive pill for menorrhagia 3 weeks before admission and presented with symptoms of headache, fever, and auditory hallucinations and illusions.

**Results:** The patient's cerebrospinal fluid showed lymphocytic pleocytosis. Two electroencephalograms showed significant right temporal lobe slowing. Magnetic resonance venogram of the brain showed venous sinus thrombosis of the right sigmoid and transverse sinuses. Magnetic resonance imaging showed a cortical venous infarct in the right middle temporal gyrus. The patient's auditory hallucinations and illusions resolved spontaneously weeks after presentation.

**Conclusions:** This case suggests that auditory hallucinations and illusions should be added to the already broad spectrum of presenting features of cerebral venous sinus thrombosis. The nondominant right middle temporal gyrus may play a role in such auditory hallucinations.

**Key Words:** cerebral thrombosis, sinus thrombosis, hallucinations auditory, illusions auditory, venous infarction, brain

(*Cogn Behav Neurol* 2011;24:40–42)

Thrombosis of intracranial veins and venous sinuses typically occurs in young-to-middle-aged women,<sup>1</sup> affecting 5 people per million.<sup>2</sup> Patients present with

headache, seizures, focal neurological deficits, altered consciousness, or papilledema. Diffuse encephalopathy is common, particularly in patients with occlusion of the deep cerebral venous system or parenchymal lesions, and may progress to coma.<sup>2</sup> In this case report, a patient with acute thrombosis of the right sigmoid and transverse sinuses presented with fever, cerebrospinal fluid pleocytosis, headache, and auditory hallucinations and illusions mimicking acute meningoenophalitis.

## CASE REPORT

A 45-year-old right-handed woman with myasthenia gravis (in remission on oral prednisone 15 mg alternating with 20 mg every other day and monthly intravenous immunoglobulin infusions), was started on a progesterone and estrogen combination pill for menorrhagia with no previous oral contraceptive use. Two weeks later, she developed a progressive headache in the right temporal and otic region that spread to the entire right hemicranium. Days later, she observed low-grade fever of 100.4 F.

The fever and headache persisted, progressing to nausea and bilateral hyperacusis. She experienced episodes of unusual noises that were not stereotyped. She heard the “electronic sound” of her friend sending e-mail and her sister's mobile phone. She became confused, and called her husband her mother. She experienced an episode of seeing flashing horizontal orange wavy lines, even with her eyes closed, lasting hours.

After 7 days of symptoms, the patient experienced a brief episode of nonsensical speech, saying single syllables that made no sense to her husband. She was unaware of the nonsensical nature of her speech. She was then taken to the emergency room, with symptoms resolving except for headache.

After admission, she developed auditory illusions. In 1 episode, she perceived her husband to be speaking German (which neither she nor her husband speaks). She heard others speaking in unusually high and low pitches. She saw peoples' mouths moving, with no words coming out. During these episodes, she remained conscious and oriented. Neurological examination on admission was intact, including mental status, fundoscopic examination, cranial nerves, motor, sensory, coordination, and reflexes. She had no meningismus.

Initial lumbar puncture showed cerebrospinal fluid with red blood cell count of 142/mm<sup>3</sup>, white blood cell count of 39/mm<sup>3</sup> (77% lymphocytes), glucose of 127 mg/dL (serum glucose 279 mg/dL), and protein of 37 mg/dL. Cultures and polymerase chain reaction for herpes simplex virus were negative. Repeat lumbar puncture 6 days later showed opening pressure of 15 cm H<sub>2</sub>O and improved white blood cell count at 5/mm<sup>3</sup>.

Received for publication November 17, 2010; accepted February 26, 2011.

From the Departments of \*Neurology; ‡Radiology, University of California, Davis Medical Center, Sacramento; and †Department of Neurology, University of California, Los Angeles, in Los Angeles, CA.

Conflicts of interest/disclosures: none.

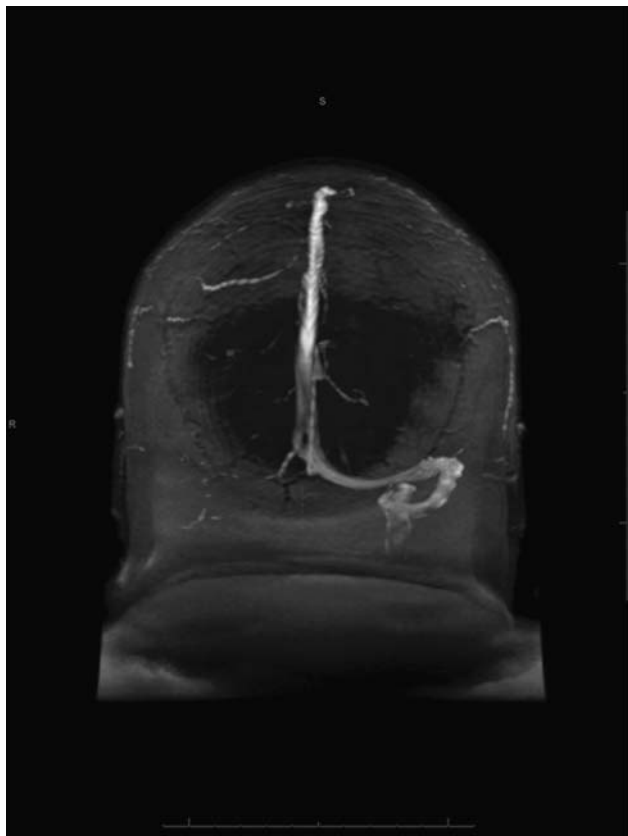
Reprints: Victoria S.S. Wong, MD, Department of Neurology, University of California, Davis Medical Center, 4860 Y St., Suite 3700 Sacramento, CA 95817 (e-mail: vwongmd@gmail.com).

Copyright © 2011 by Lippincott Williams & Wilkins

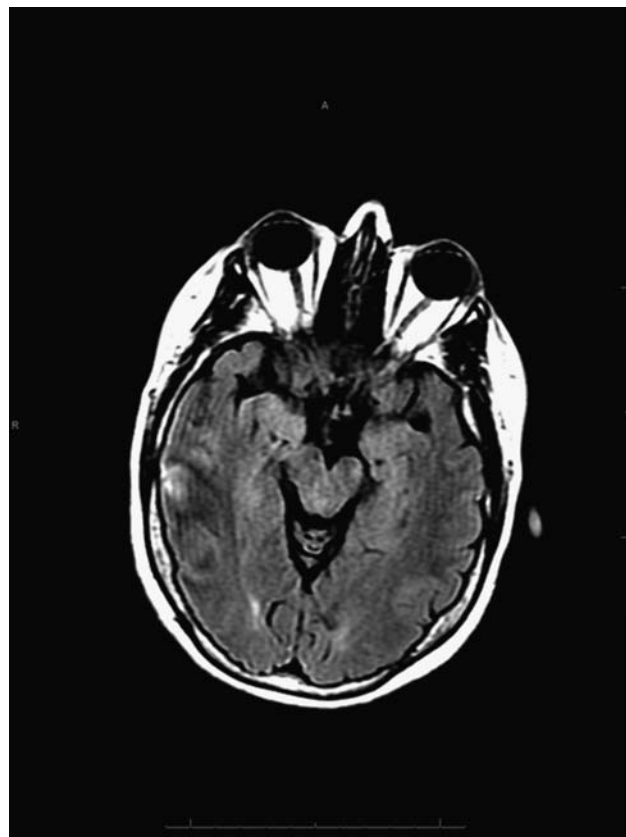
Magnetic resonance imaging (MRI) on admission showed subtle increased signal in the posterior aspect of the right temporal–occipital junction on the fluid-attenuated inversion recovery sequences with increased signal on T1 that enhanced slightly after the administration of gadolinium, initially thought to be consistent with hemorrhagic encephalitis. Two electroencephalograms (EEGs) showed widespread right temporal polymorphic delta slowing, without epileptiform activity. Acyclovir and ceftriaxone were started empirically.

Magnetic resonance venogram on day 5 of admission showed venous sinus thrombosis involving the right sigmoid and transverse sinuses. No significant flow was observed within the right internal jugular vein (Fig. 1). There was a small cortical venous infarct in the right middle temporal gyrus (Fig. 2). In retrospect, the area of infarction was not clearly seen on the diffusion weighted imaging sequence on the initial MRI because of an artifact from the interface of the temporal lobe and the adjacent temporal bone. The diffusion-weighted imaging sequence is typically abnormal in venous infarction but is often more heterogenous than in arterial infarcts. Computed tomographic venogram showed low-density thrombus within the right sigmoid sinus and jugular bulb (Fig. 3). Tests for hypercoagulable conditions were negative.

The patient was started on enoxaparin bridging to warfarin. Auditory illusions persisted, lasting seconds, a few times a day. Levetiracetam was initiated during hospitalization, but was discontinued as it did not affect the nature or frequency of episodes. Her symptoms resolved completely within weeks after discharge, with no recurrence.



**FIGURE 1.** Magnetic resonance venography shows absence of flow within right transverse sinus, sigmoid sinus, and jugular bulb.

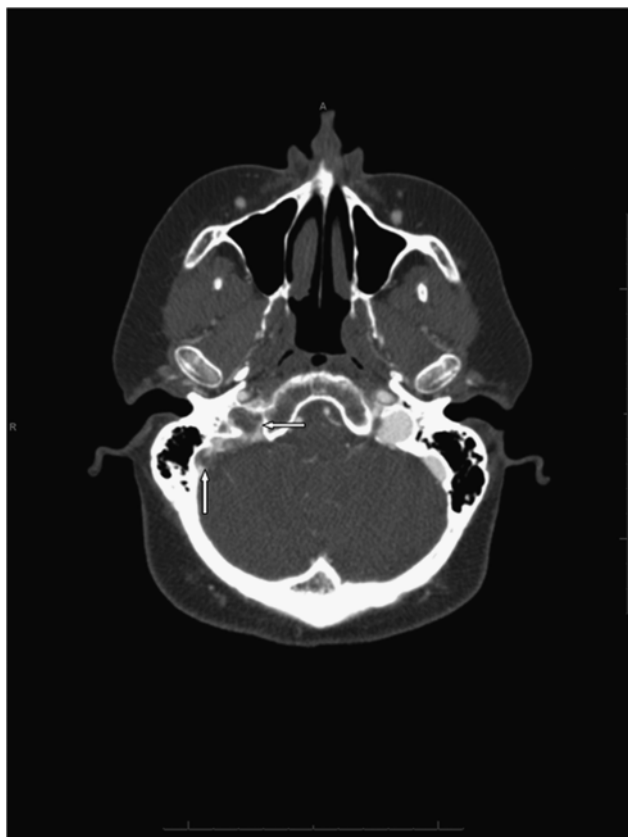

**FIGURE 2.** Axial T2 fluid-attenuated inversion recovery hyperintensity within the lateral right temporal lobe (middle temporal gyrus) corresponding to the site of venous infarction.

## DISCUSSION

We report a case of cerebral venous sinus thrombosis leading to venous infarction of a portion of the right middle temporal gyrus with an unusual presentation of auditory illusions and hallucinations with hyperacusis, in addition to headache, fever, and nausea. Oral contraceptive pills may have induced a hypercoagulable state with, perhaps, some contribution from chronic intravenous immunoglobulin infusions. It is uncertain whether the episodes of auditory illusions and hallucinations were partial seizures or neuropsychiatric symptoms of the infarction. The episodes were not stereotyped, and did not respond to antiseizure medication and 2 interictal EEGs failed to show seizure activity. However, in the absence of EEG monitoring during an episode, their occurrence as a manifestation of a seizure cannot be ruled out. A third possible mechanism would be that of auditory release phenomena resulting from damage to auditory pathways,<sup>3</sup> although our patient did not complain of hearing loss. In addition, release hallucinations are more commonly described in the literature as visual hallucinations in response to binocular vision loss of any etiology.

The incidence of mental status disorders in cerebral venous sinus thrombosis is 22%, whereas the incidence of seizure is 39%.<sup>4</sup> Von Mering et al<sup>5</sup> described 6 patients with neuropsychiatric symptoms as a result of



**FIGURE 3.** Computed tomographic venography at the skull base showing low-density thrombus within the right sigmoid sinus and jugular bulb (arrows).

cerebral venous sinus thrombosis, including somnolence, bradyphrenia, or apathia and hallucinations and memory loss. The single patient with hallucinations had associated bilateral thalamic edema. None of the 6 patients described had temporal lobe involvement, as our patient did. The transverse gyrus of Heschl in the dominant hemisphere, matching the location of primary auditory cortex, has been implicated in auditory verbal hallucinations.<sup>6</sup> There may also be a role of the right (nondominant) hemisphere in auditory hallucinations.<sup>7,8</sup> One study implicated the medial temporal gyrus in auditory hallucinations in schizophrenia. Cortical activation of the right middle temporal gyrus on functional MRI was reduced during periods of increased auditory

hallucinations, “consistent with the hypothesis that auditory hallucinations ‘compete’ with external speech for processing sites within the temporal cortex.”<sup>9</sup>

In contrast, a supratentorial parenchymal lesion in cerebral venous sinus thrombosis is a significant risk factor for early seizures.<sup>10</sup> Electrographic seizure activity in Heschl’s gyrus and the superior temporal gyrus, both dominant and nondominant, can result in auditory illusions and hallucinations.<sup>11</sup>

Whatever the underlying mechanism in this case, auditory hallucinations and illusions should be added to the already broad spectrum of presenting features of cerebral venous sinus thrombosis. The diagnosis of cerebral venous sinus thrombosis may be considered in patients presenting with new auditory hallucinations and illusions, particularly in the context of accompanying headache and conventional risk factors for venous sinus thrombosis.

## REFERENCES

1. Gosk-Bierska I, Wysokinski W, Brown RD Jr, et al. Cerebral venous sinus thrombosis: incidence of venous thrombosis recurrence and survival. *Neurology*. 2006;67:814–819.
2. Bousser MG, Ferro JM. Cerebral venous thrombosis: an update. *Lancet Neurol*. 2007;6:162–170.
3. Devinsky O, D’Esposito M. *Neurology of Cognitive and Behavioral Disorders*. New York: Oxford University Press, Inc; 2004.
4. Ferro JM, Canhão P, Stam J, et al; ISCVT Investigators. Prognosis of cerebral vein and dural sinus thrombosis: results of the International Study on Cerebral Vein and Dural Sinus Thrombosis (ISCVT). *Stroke*. 2004;35:664–670.
5. Von Mering M, Stiefel M, Brockmann K, et al. Deep cerebral venous sinus thrombosis often presents with neuropsychologic symptoms. *J Clin Neurosci*. 2003;10:310–312.
6. Dierks T, Linden DE, Jandl M, et al. Activation of Heschl’s gyrus during auditory hallucinations. *Neuron*. 1999;22:615–621.
7. Shergill SS, Brammer MJ, Williams SC, et al. Mapping auditory hallucinations in schizophrenia using functional magnetic resonance imaging. *Arch Gen Psychiatry*. 2000;57:1033–1038.
8. Stewart B, Brennan DM. Auditory hallucinations after right temporal gyri resection. *J Neuropsychiatry Clin Neurosci*. 2005;17:243–245.
9. Woodruff PW, Wright IC, Bullmore ET, et al. Auditory hallucinations and the temporal cortical response to speech in schizophrenia: a functional magnetic resonance imaging study. *Am J Psychiatry*. 1997;154:1676–1682.
10. Ferro JM, Canhão P, Bousser MG, et al; ISCVT Investigators. Early seizures in cerebral vein and dural sinus thrombosis: risk factors and role of antiepileptics. *Stroke*. 2008;39:1152–1158.
11. Elliott B, Joyce E, Shorvon S. Delusions, illusions and hallucinations in epilepsy: 1. elementary phenomena. *Epilepsy Res*. 2009;85:162–171.