

Case report

QJM

Cerebral ischaemia in the context of improving, steroid-treated pneumococcal meningitis

C.M. RICE¹, M. RAMAMOORTHY¹, S.A. RENOWDEN², P. HEYWOOD¹, A.L. WHONE¹ and N.J. SCOLDING¹

From the ¹Department of Neurology and ²Department of Neuroradiology, Frenchay Hospital, Bristol BS16 1LE, UK

Address correspondence to Dr C.M. Rice, Department of Neurology, Frenchay Hospital, Bristol BS16 1LE, UK.
email: c.m.rice@bristol.ac.uk

Case report

A 41-year-old man was admitted to hospital with a 1-week history of fever, headache and vomiting. He was known to have Evans' syndrome (immune thrombocytopenia with autoimmune haemolytic anaemia), which had been treated by splenectomy 3 years prior to presentation. He had declined the relevant vaccinations. On arrival in the Emergency Department, he complained of headache, was confused and non-compliant with examination. He had neck stiffness, but was afebrile and cardiovascularly stable. His Glasgow Coma Scale (GCS) was 13 (Eyes 3, Motor 6, Verbal 4), but there were no localizing signs. Inflammatory markers were elevated [C-reactive protein (CRP) 367 mg/l] and neutrophilia was detected [white cell count (WCC) $27 \times 10^9/l$, neutrophils $25 \times 10^9/l$]. Platelets were $51 \times 10^9/l$ consistent with Evans' syndrome. A computed tomography (CT) head scan revealed moderate hydrocephalus, but no other abnormality. The cerebrospinal fluid (CSF) was turbid and the protein concentration was grossly elevated (17 g/l). CSF glucose was undetectable (<0.1 mmol/l). CSF WCC could not be performed as the sample clotted, but *Streptococcus pneumoniae* urine antigen was positive and subsequently both blood and CSF cultures grew *S. pneumoniae*. Treatment was commenced with intravenous ceftriaxone (2 g bis die) at presentation and he received a 4-day course of dexamethasone [10 mg quater die sumendus (qds)].

Clinical improvement was noted; by the time steroids were withdrawn, there was mild confusion (mini-mental test score 9/10), resolution of headache and improved mobility. The CRP had normalised and serial CT head scans demonstrated resolving hydrocephalus. Imminent discharge home was planned.

The day following discontinuation of steroids, his headache recurred and there was a gradual drop in conscious level over 36 h to GCS 5 (E1, M3, V1) associated with fever and a rise in inflammatory markers. Phenytoin was commenced, but an electroencephalogram did not demonstrate epileptiform activity. A CT head scan (including a CT venogram) did not show any new abnormality. He was admitted to intensive care and dexamethasone was restarted (4 mg qds). He was therefore off steroid treatment for 72 h. On review by the neurology team, the pupils were unequal (left 4 mm, right 3 mm) and there was an exotropia with loss of doll's eye reflex. Corneal reflexes were intact. Stimulus-sensitive myoclonus was noted. There was a spastic catch on examination of tone in the upper limbs and the limbs flexed in response to pain. Cranial magnetic resonance imaging demonstrated high signal in the thalami and posterior limb of the internal capsule bilaterally, and in the left caudate head and lentiform nucleus. Other smaller areas of high signal were seen in the subcortical white matter of the frontal lobes, in the right temporal lobes and adjacent to the occipital horn of the

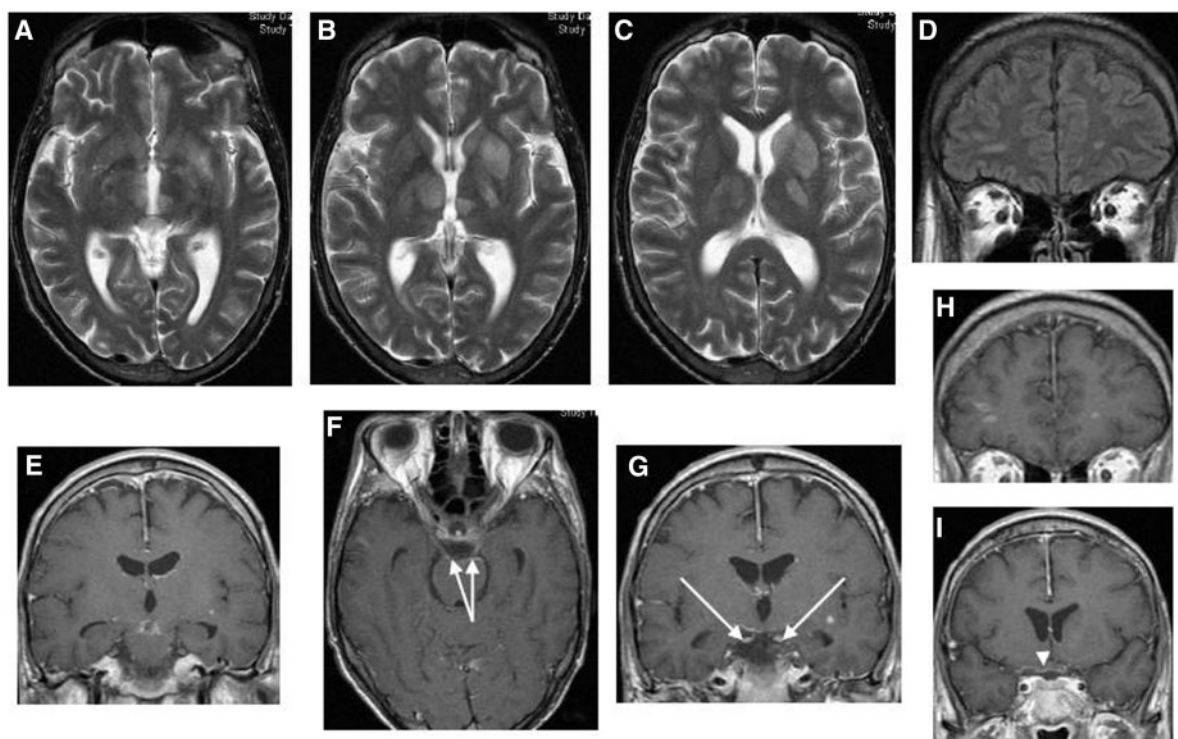


Figure 1. T2-weighted axial (A–C), fluid attenuated inversion recovery coronal (D), axial T1-weighted gadolinium enhanced coronal (E, G–I) and axial (F) magnetic resonance images demonstrate high T2 signal in the midbrain, thalami and internal capsules bilaterally and the left basal ganglia. The midbrain lesions showed some enhancement (E). There were scattered, similar but very small, foci of high T2 signal in the subcortical white matter bilaterally, some of which also enhanced (D and H). Enhancement is also seen in the meninges around the third nerves bilaterally (F, G, arrows) and optic chiasm (I, white arrowhead).

right lateral ventricle. A single area of enhancement was seen in a white matter lesion deep to the left insula (Figure 1). Flow voids were seen in the basilar artery and both posterior cerebral arteries. There was no hydrocephalus. Repeat CSF analysis was consistent with partial resolution of bacterial meningitis (WC $16/\text{mm}^3$, protein 1.38 g/l , glucose 3 mmol/l with serum glucose 5.7 mmol/l). No organisms were seen on Gram or Ziehl–Neelsen staining, and culture (including enrichment and prolonged culture for mycobacteria) was negative. Dexamethasone was increased to a total daily dose of 40 mg and was subsequently gradually weaned over several weeks. There has been some limited clinical improvement although at 4 months the patient remains significantly impaired; eyes open spontaneously, brisk localization with the left upper limb, some voluntary movement of the lower limbs and occasional sounds.

Discussion

Cerebrovascular complications are common in bacterial meningitis and, when they occur, the

causative pathogen is most likely to be *S. pneumoniae*.^{1–3} Other reported predictors are reduced level of consciousness on presentation and relatively low CSF WCC.¹ Although stroke generally occurs in the most severely affected patients,^{1,4} it can be a delayed phenomenon occurring 2 weeks or more following the commencement of antibiotics.¹ Prognosis for functional recovery is poor.^{1,2}

A recent report has emerged of acute deterioration occurring several days following discontinuation of steroid therapy despite initial marked improvement in the patient's condition.⁵ Our case echoes such a presentation and the neuroradiological findings were consistent with ischaemia due to bacterial meningitis.⁶ Although a single, retrospective analysis of a pneumococcal meningitis case series has not corroborated the existence of such a phenomenon,⁴ we postulate that this may be due to the relatively recent introduction of high-dose corticosteroid therapy in the clinical guidelines for the treatment of pneumococcal meningitis (at least in high-income countries).⁷

The mechanism underlying delayed cerebral ischaemia in the context of an improving patient with bacterial meningitis is currently unclear but it

has been postulated that it may be an infectious phenomenon, an immune-mediated thrombotic microangiopathy or occur secondary to hypercoagulability due to bacterial meningitis exacerbated by corticosteroid therapy.⁸ Our impression is that it is most likely to reflect an immune-mediated thrombotic microangiopathy which is suppressed by acute steroid therapy.

This case (i) provides further evidence for the phenomenon of delayed cerebral ischaemia in the context of an improving patient with pneumococcal meningitis; (ii) offers additional support for the suggestion that steroid withdrawal plays a role in this disorder; and (iii) serves as a reminder to physicians to be alert to the possibility of the emergence of vasculopathy as a late complication of steroid-treated meningitis. In the light of the findings of Schut *et al.*⁵ and our own, we suggest that consideration is given to gradual steroid withdrawal rather than the abruptly terminated 4-day course (10 mg dexamethasone qds) currently advocated.⁹ Further work is required to determine definitively the mechanism underlying delayed vasculopathy as a late complication of steroid-treated meningitis.

Acknowledgements

The authors are grateful to the patient and family for their permission to publish this case report.

Funding

C.M.R. and A.L.W. are grateful for financial support received from the Burden Neurological Institute. C.M.R. also gratefully acknowledges the support of the National Institute for Health Research.

These organizations had no role in the preparation, review or approval of the manuscript.

Conflict of interest: None declared.

References

1. Katchanov J, Heuschmann PU, Endres M, Weber JR. Cerebral infarction in bacterial meningitis: predictive factors and outcome. *J Neurol* 2010; **257**:716–20.
2. Pfister HW, Borasio GD, Dirnagl U, Bauer M, Einhaupl KM. Cerebrovascular complications of bacterial meningitis in adults. *Neurology* 1992; **42**:1497–504.
3. Pfister HW, Feiden W, Einhaupl KM. Spectrum of complications during bacterial meningitis in adults. Results of a prospective clinical study. *Arch Neurol* 1993; **50**:575–81.
4. Klein M, Koedel U, Kastenbauer S, Pfister HW, van de Beek D, Schut ES, *et al.* Delayed cerebral thrombosis after initial good recovery from pneumococcal meningitis: past as prologue: delayed stroke as a parainfectious process of bacterial meningitis? *Neurology* 2010; **75**:193; author reply 193, 194.
5. Schut ES, Brouwer MC, de Gans J, Florquin S, Troost D, van de Beek D. Delayed cerebral thrombosis after initial good recovery from pneumococcal meningitis. *Neurology* 2009; **73**:1988–95.
6. Katchanov J, Siebert E, Endres M, Klingebiel R. Focal parenchymal lesions in community-acquired bacterial meningitis in adults: a clinico-radiological study. *Neuroradiology* 2009; **51**:723–9.
7. Heyderman RS, Lambert HP, O'Sullivan I, Stuart JM, Taylor BL, Wall RA. Early management of suspected bacterial meningitis and meningococcal septicaemia in adults. *J Infect* 2003; **46**:75–7.
8. Steiner I. Past as prologue: delayed stroke as a parainfectious process of bacterial meningitis? *Neurology* 2009; **73**:1945–6.
9. van de Beek D, de Gans J, Tunkel AR, Wijdicks EF. Community-acquired bacterial meningitis in adults. *N Engl J Med* 2006; **354**:44–53.