

Neurol Med Chir (Tokyo) 51, 310 ~ 314, 2011

Pleomorphic Xanthoastrocytoma and Moyamoya Disease in a Patient With Neurofibromatosis Type 1

—Case Report—

Satoshi HORIGUCHI,¹ Koichi MITSUYA,¹ Reiko WATANABE,²
Saburo YAGISHITA,³ and Yoko NAKASU¹

Divisions of ¹Neurosurgery and ²Pathology, Shizuoka Cancer Center, Shizuoka;

³Division of Pathology, Kanagawa Rehabilitation Center, Atsugi, Kanagawa

Abstract

A 32-year-old man with familial neurofibromatosis type 1 presented with a rare case of coexisting pleomorphic xanthoastrocytoma (PXA) and moyamoya disease manifesting as progressive right hemiparesis. Magnetic resonance (MR) imaging with gadolinium showed an enhanced mass lesion in the left basal ganglia extending to the left parietal lobe. Preoperative angiography showed severe stenosis of the bilateral internal carotid arteries, and moyamoya vessels. The patient underwent open biopsy. Histological examination showed the characteristic findings of PXA. After radiation therapy and chemotherapy, MR imaging showed decreased size and enhancement of the tumor, but his clinical condition worsened with generalized convulsions and consciousness disturbance. He died 1 year and 6 months after the first presentation. Autopsy findings demonstrated necrosis in the main mass and tumor cell dissemination without anaplastic change. The rare combination of PXA and moyamoya disease in the basal ganglia limited treatment options. Injured moyamoya vessels and ischemic condition might have caused tumor progression and dissemination. Radiation therapy, in combination with moyamoya disease, induced decreased cerebral blood flow (CBF) in the left frontal lobe. Tumor dissemination, CBF decrease, and hydrocephalus led to the clinical deterioration of this patient.

Key words: basal ganglia, moyamoya disease, neurofibromatosis type 1, pleomorphic xanthoastrocytoma, radiation therapy

Introduction

Neurofibromatosis type 1 (NF1) is associated with increased risk of development of intracranial tumors,^{9,10)} particularly multiple peripheral neurofibromas. NF1

also predisposes to tumors of the central nervous system such as pilocytic astrocytoma in the optic pathway and brainstem.^{19,32)} Only seven cases of pleomorphic xanthoastrocytoma (PXA) associated with NF1 were reported.^{7,14,16,26,27,29,34)} NF1 is also associated with cerebrovascular abnormalities,³³⁾ occurring in 2.5% of patients with NF1, including 0.6% with moyamoya dis-

Received June 28, 2010; Accepted September 3, 2010

ease.³³⁾ In contrast, the annual rate of newly diagnosed moyamoya cases is 0.54 per 100,000 people in Japan.¹⁷⁾ The causative gene (*NF1*) has been assigned to chromosome 17q11.2. The protein product of the *NF1* gene (neurofibromin) is a guanosine triphosphatase-activating protein that regulates cellular growth through control of the Ras oncogene and is likely related to vasculopathy.³³⁾ A gene for familial moyamoya disease is also located on chromosome 17q25 based on microsatellite linkage analyses.⁴⁰⁾ However, the location of the gene does not support the direct participation of the *NF1* gene in the occurrence of moyamoya disease.

We treated a patient with NF1 associated with PXA and moyamoya disease coexisting in the basal ganglia, and describe the therapeutic strategy including radiotherapy and chemotherapy in this difficult case.

Case Report

A 32-year-old man presented with progressive right hemiparesis. Physical examination discovered multiple subcutaneous neurofibromas and café-au-lait spots, and his mother and his sister had similar manifestations of NF1, compatible with the criteria for familial NF1. He had

no previous history of epilepsy or episodes of motor dysfunction. Magnetic resonance imaging with gadolinium showed an enhanced mass lesion in the left basal ganglia

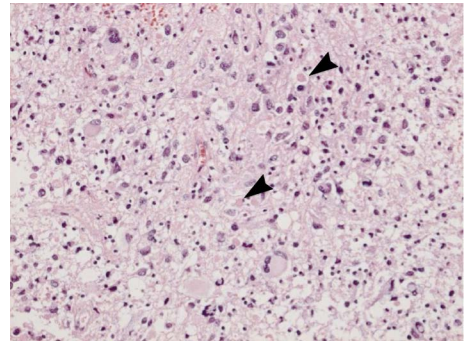


Fig. 3 Photomicrograph of the biopsy specimen showing xanthomatous tumor cells with nuclear pleomorphism, eosinophilic granular bodies (arrowheads), and lymphocyte infiltration. Hematoxylin and eosin stain, original magnification $\times 20$.

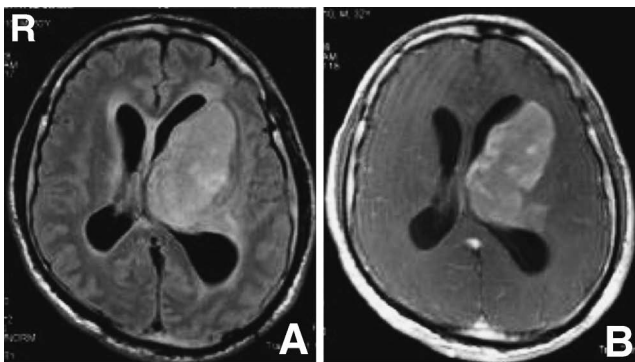


Fig. 1 Fluid-attenuated inversion recovery (A) and T₁-weighted magnetic resonance images with gadolinium (B) showing a tumor with mass effect in the left basal ganglia extending to the left parietal lobe, enlargement of the lateral ventricles, and peritumoral edema.

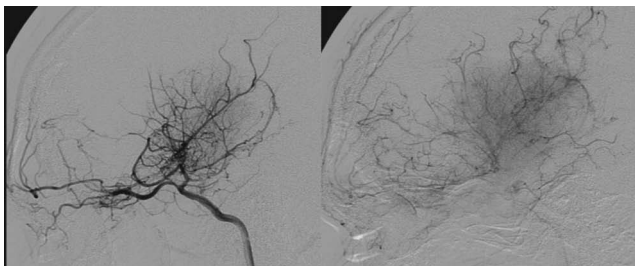


Fig. 2 Left carotid angiograms, lateral view, revealing stenocclusive changes at the terminal portions of the left internal carotid artery, with anastomotic collateral vessels in the left basal ganglia.

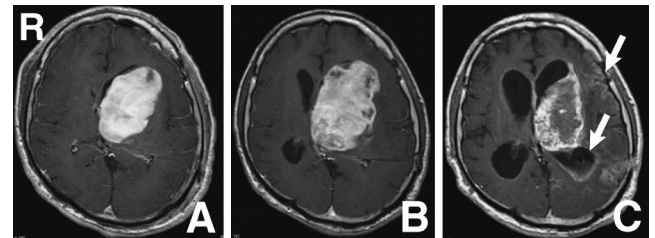


Fig. 4 Serial T₁-weighted magnetic resonance images with gadolinium after tumor biopsy and ventriculoperitoneal shunt (A) and 5 months after tumor biopsy (B) showing enlargement and heterogeneous enhancement of the tumor, and 17 months later (C) showing dissemination of the tumor to the ventricular wall and brain surface (arrows) and marked hydrocephalus.

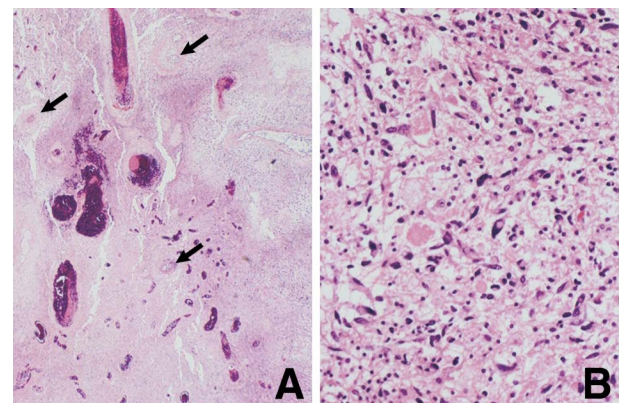


Fig. 5 Photomicrographs of the autopsy specimen showing moyamoya vessels with focal fibrinoid necrosis (arrows) traversing the necrotic pleomorphic xanthoastrocytoma lesion (A) containing viable neoplastic cells (B). Hematoxylin and eosin stain, original magnification $\times 20$ (A), $\times 200$ (B).

extending to the left parietal lobe and hydrocephalus (Fig. 1). His right hemiparesis became worse over 2 weeks. Preoperative angiography showed severe stenosis of the bilateral internal carotid arteries and moyamoya vessels (Fig. 2). This presentation is called quasi-moyamoya disease, or moyamoya disease with basic manifestations. Tumor stain fed by the moyamoya vessels was observed. The anterior part of the anterior cerebral artery territory was supplied through a transdural anastomosis.

Surgery was planned for histological diagnosis and resolution of hydrocephalus. Cerebral perfusion was supplied through the middle meningeal and superficial temporal arteries, so these vessels had to be preserved. Gross total removal of the lesion might have caused further deterioration of right hemiparesis because of the location in the left basal ganglia. Therefore, the patient underwent open biopsy through a small craniotomy. A ventriculoperitoneal (VP) shunt was inserted to relieve the hydrocephalus. Histological examination of the biopsy specimen revealed the neoplastic lesion was an astrocytic tumor consisting of xanthomatous cells with marked pleomorphism. Eosinophilic granular bodies and lymphocytic infiltration, which are typical features of PXA, were observed (Fig. 3). No microvascular proliferation or palisading necrosis was identified. The MIB1 index was 5–10%.

His symptoms worsened in a short time due to tumor progression (Fig. 4A, B), so he underwent extended local radiation therapy (54 Gy). Chemotherapy was performed with nine cycles of intravenous nimustine (80 mg/m²) injection followed by four cycles of temozolomide (150 mg/m²). Magnetic resonance imaging showed reduced size and enhancement of the lesion, but his clinical condition deteriorated with worsened hemiparesis and aphasia, and generalized convulsions. Meningitis caused by VP shunt infection was treated with antibiotic therapy following VP shunt revision. Dissemination of the tumor to the ventricular wall and brain surface was observed 17 months after the biopsy (Fig. 4C). Serial technetium-99m-L,L-ethyl cysteinate dimer (^{99m}Tc-ECD) single photon emission computed tomography (SPECT) showed gradual decrease in cerebral blood flow (CBF) in the left frontal lobe. He died 1 year and 6 months after the first presentation.

Autopsy specimen revealed that the tumor was 5 cm in diameter, and dissemination of tumor cells was found on the cerebral surface. Moyamoya vessels were observed traversing the PXA with massive necrosis in the left basal ganglia. Fibrinoid vascular necrosis, compatible with radionecrosis, was observed in multiple foci. No anaplastic change was identified (Fig. 5). The MIB1 index of the autopsy specimen was 2–7%. Examination of hypoxic markers was not performed.

Discussion

Coexistence of brain tumor and moyamoya disease is rare, with only 11 previous cases reported.^{1,2,8,11,13,18,24,35–37} The tumors were three astrocytomas, three meningiomas, three pituitary adenomas, one craniopharyngioma, and

one germinoma. The histological diagnoses for the astrocytomas were two pilocytic astrocytomas and one astrocytoma. The patients were aged from 4 to 11 years. No case of PXA and moyamoya disease has been reported. An 8-year-old patient with moyamoya disease and pilocytic astrocytoma in the brain stem was treated by partial resection for tumor decompression, and local radiation therapy sparing the supratentorial region, followed by direct bypass surgery.¹³ Four mechanisms have been proposed for the combination of brain tumor and moyamoya disease²⁵: Direct compression of arteries by the tumor, secondary effects of radiation on the tumor, presence of neurocutaneous syndrome, and incidental association. Our patient was predisposed to the combination of brain tumor and moyamoya disease by the presence of NF1.

PXA is usually described as an uncommon astrocytic tumor with a relatively favorable prognosis, typically encountered in children and young adults, with cerebral cortical location.²⁰ Only a few cases of PXA have been reported in the basal ganglia.¹⁵ The histological characteristics of PXA are the presence of nuclear and cytoplasmic pleomorphism and xanthomatous change. Eosinophilic granular bodies and lymphocytic infiltration are also observed.²⁰ PXA is classified as one of the grade II astrocytic tumors by World Health Organization.²⁰ In our case, the histological findings were consistent with PXA at both biopsy and autopsy. Seven cases of PXA have been reported in patients with NF1, but none in the basal ganglia.^{7,14,16,26,27,29,34}

Treatment of PXA is mainly by maximal surgical resection. The extent of resection of the original mass is the most significant predictive factor.⁶ Overall survival has been estimated as 81% at 5 years and 70% at 10 years. Adjuvant radiotherapy or chemotherapy have not been shown to prolong survival,³⁹ but may reduce recurrence of this rare tumor.^{22,30} Postoperative radiation is reserved mainly for recurrence with anaplastic change,^{6,38} because of the risk of radiation-induced malignancy.⁵ Chemotherapy has been used to facilitate surgical resection of PXA.³ Four cases of PXA with dissemination at diagnosis have been reported and were treated by chemotherapy and/or radiotherapy.^{21,23,28,31} One patient died of tumor progression 5 years after diagnosis, and the other three are alive without tumor progression 2 years after treatment.

Radiation can cause endothelial cell injury and death. Endothelial cell damage coupled with cytokine-mediated functional changes in the vasculature can cause hemodynamic alterations that lead to slowed blood flow and perivascular edema, and may predispose to stasis and thrombus formation.⁴ In our case, the moyamoya disease might have caused the clinical progression after radiation therapy. Serial ^{99m}Tc-ECD SPECT revealed decreased CBF in the left frontal lobe after radiation therapy, which may explain the decrease of CBF in the moyamoya vessels or surrounding vessels following radiation therapy. Furthermore, serum levels of matrix metalloproteinase-2, monocyte chemoattractant protein-1, interleukin-1 β , vascular endothelial growth factor, and platelet-derived growth factor-BB are increased in patients with moyamoya disease.¹² These cytokines are thought to be important in the mobili-

zation of endothelial progenitor cells in patients with moyamoya disease.¹²⁾ We speculate that the changes in cytokine levels associated with injured moyamoya vessels and ischemic disease may have contributed to the aggressive behavior of the tumor in our patient.

In our patient, surgical resection was neither rational nor indicated because of the location of the tumor and the association of moyamoya disease. Chemotherapy and radiation therapy were performed because the symptoms progressed. However, the presence of moyamoya disease and radiation therapy might cause hemodynamic alteration and thrombus formation in the basal ganglia, leading to clinical worsening.

This very rare case of PXA in the basal ganglia and moyamoya disease in a patient with NF1 demonstrates the restricted treatment choices for this rare combination in the dominant-side central structure. Maximal surgical resection was impossible, so additional therapeutic options such as radiation and chemotherapy should be combined. Concurrent moyamoya disease was important in the tumor progression and clinical deterioration. A better understanding of the biological basis leading to progression and dissemination of PXA is essential and may provide key insights into the treatment strategy for such difficult cases.

References

- 1) Aihara N, Nagai H, Mase M, Kanai H, Wakabayashi S, Mabe H: Atypical moyamoya disease associated with brain tumor. *Surg Neurol* 37: 46-50, 1992
- 2) Arita K, Uozumi T, Oki S, Kuwabara S, Ohba S, Nakahara T, Muttaqin Z, Kohno H, Yamada K: Moyamoya disease associated with pituitary adenoma—report of two cases. *Neurol Med Chir (Tokyo)* 32: 753-757, 1992
- 3) Cartmill M, Hewitt M, Walker D, Lowe J, Jaspan T, Punt J: The use of chemotherapy to facilitate surgical resection in pleomorphic xanthoastrocytoma: experience in a single case. *Childs Nerv Syst* 17: 563-566, 2001
- 4) Fajardo LF, Stewart JR: Pathogenesis of radiation-induced myocardial fibrosis. *Lab Invest* 29: 244-257, 1973
- 5) Fuller GN, Kaba SE, Ginsberg LE, McCutcheon IE, Langford LA: Late sequelae of treated pleomorphic xanthoastrocytoma: malignant brain stem astrocytoma occurring 15 years after radiation therapy. *J Neurooncol* 32: 57-61, 1997
- 6) Giannini C, Scheithauer BW, Burger PC, Brat DJ, Wollan PC, Lach B, O'Neill BP: Pleomorphic xanthoastrocytoma: what do we really know about it? *Cancer* 85: 2033-2045, 1999
- 7) Hariharan S, Donahue JE, Garre C, Origone P, Grewal RP: Clinicopathologic and genetic analysis of siblings with NF1 and adult-onset gliomas. *J Neurol Sci* 247: 105-108, 2006
- 8) Hattori M, Tokunaga J, Toya S, Shizawa H: [An occlusion of the circle of Willis after the removal of cerebellar astrocytoma]. *No To Hattatsu* 5: 314-319, 1973 (Japanese)
- 9) Ilgren EB, Kinnier-Wilson LM, Stiller CA: Gliomas in neurofibromatosis: a series of 89 cases with evidence for enhanced malignancy in associated cerebellar astrocytomas. *Pathol Annu* 20: 331-358, 1985
- 10) Inoue Y, Nemoto Y, Tashiro T, Nakayama K, Nakayama T, Daikokuya H: Neurofibromatosis type 1 and type 2: review of the central nervous system and related structures. *Brain Dev* 19: 1-12, 1997
- 11) Kaku M, Nakayama T, Matsukado Y: [Surgical case of meningioma associated with basal abnormal vascular network]. *Shujutsu* 27: 1159-1162, 1973 (Japanese)
- 12) Kang HS, Kim JH, Phi JH, Kim YY, Kim JE, Wang KC, Cho BK, Kim SK: Plasma matrix metalloproteinases, cytokines and angiogenic factors in moyamoya disease. *J Neurol Neurosurg Psychiatry* 81: 673-678, 2010
- 13) Kitano S, Sakamoto H, Fujitani K, Kobayashi Y: Moyamoya disease associated with a brain stem glioma. *Childs Nerv Syst* 16: 251-255, 2000
- 14) Koeller KK, Henry JM: From the archives of the AFIP: superficial gliomas: radiologic-pathologic correlation. Armed Forces Institute of Pathology. *Radiographics* 21: 1533-1556, 2001
- 15) Kros JM, Vecht CJ, Stefanko SZ: The pleomorphic xanthoastrocytoma and its differential diagnosis: a study of five cases. *Hum Pathol* 22: 1128-1135, 1991
- 16) Kubo O, Sasahara A, Tajika Y, Kawamura H, Kawabatake H, Takakura K: Pleomorphic xanthoastrocytoma with neurofibromatosis type 1: case report. *Noshuyo Byori* 13: 79-83, 1996
- 17) Kuriyama S, Kusaka Y, Fujimura M, Wakai K, Tamakoshi A, Hashimoto S, Tsuji I, Inaba Y, Yoshimoto T: Prevalence and clinicoepidemiological features of moyamoya disease in Japan: findings from a nationwide epidemiological survey. *Stroke* 39: 42-47, 2008
- 18) Lau YL, Milligan DW: Atypical presentation of cranio-pharyngioma associated with moyamoya disease. *J R Soc Med* 79: 236-237, 1986
- 19) Listernick R, Charrow J, Gutmann DH: Intracranial gliomas in neurofibromatosis type 1. *Am J Med Genet* 89: 38-44, 1999
- 20) Louis DN, Ohgaki H, Wiestler OD, Cavenee WK (eds): *WHO Classification of Tumours of the Central Nervous System*. Lyon, IARC, 2007, pp 22-24
- 21) Lubansu A, Rorive S, David P, Sariban E, Seligmann R, Brotchi J, Pirotte B: Cerebral anaplastic pleomorphic xanthoastrocytoma with meningeal dissemination at first presentation. *Childs Nerv Syst* 20: 119-122, 2004
- 22) Macaulay RJ, Jay V, Hoffman HJ, Becker LE: Increased mitotic activity as a negative prognostic indicator in pleomorphic xanthoastrocytoma. Case report. *J Neurosurg* 79: 761-768, 1993
- 23) McNatt SA, Gonzalez-Gomez I, Nelson MD, McComb JG: Synchronous multicentric pleomorphic xanthoastrocytoma: case report. *Neurosurgery* 57: E191, 2005
- 24) Mizukawa N, Iwatsuki K: [Case of cerebral basal rete mirabile associated with brain tumor]. *Rinsho Shinkeigaku* 13: 650-657, 1973 (Japanese)
- 25) Mori K, Takeuchi J, Ishikawa M, Handa H, Toyama M, Yamaki T: Occlusive arteriopathy and brain tumor. *J Neurosurg* 49: 22-35, 1978
- 26) Naidich MJ, Walker MT, Gottardi-Littell NR, Han G, Chandler JP: Cerebellar pleomorphic xanthoastrocytoma in a patient with neurofibromatosis type 1. *Neuroradiology* 46: 825-829, 2004
- 27) Ohta S, Ryu H, Miura K: Eighteen-year survival of a patient with malignant pleomorphic xanthoastrocytoma associated with von Recklinghausen neurofibromatosis. *Br J Neurosurg* 13: 420-422, 1999
- 28) Okazaki T, Kageji T, Matsuzaki K, Horiguchi H, Hirose T, Watanabe H, Ohnishi T, Nagahiro S: Primary anaplastic pleomorphic xanthoastrocytoma with widespread neuroaxis dissemination at diagnosis—a pediatric case report and review of the literature. *J Neurooncol* 94: 431-437, 2009
- 29) Ozek MM, Sav A, Pamir MN, Ozer AF, Ozek E, Erzen C: Pleomorphic xanthoastrocytoma associated with von Reck-

- linghausen neurofibromatosis. *Childs Nerv Syst* 9: 39–42, 1993
- 30) Pahapill PA, Ransay DA, Del Maestro RF: Pleomorphic xanthoastrocytoma: case report and analysis of the literature concerning the efficacy of resection and the significance of necrosis. *Neurosurgery* 38: 822–829, 1996
 - 31) Passone E, Pizzolitto S, D'Agostini S, Skrap M, Gardiman MP, Nocerino A, Scarzello G, Perilongo G: Non-anaplastic pleomorphic xanthoastrocytoma with neuroradiological evidences of leptomeningeal dissemination. *Childs Nerv Syst* 22: 614–618, 2006
 - 32) Rosser T, Packer RJ: Intracranial neoplasm in children with neurofibromatosis 1. *J Child Neurol* 17: 630–637, 2002
 - 33) Rosser TL, Vezina G, Packer RJ: Cerebrovascular abnormalities in a population of children with neurofibromatosis type 1. *Neurology* 64: 553–555, 2005
 - 34) Saikali S, Le Strat S, Heckly A, Stock N, Scarabin JM, Hamlat A: Multicentric pleomorphic xanthoastrocytoma in a patient with neurofibromatosis type 1. Case report and review of the literature. *J Neurosurg* 102: 376–381, 2005
 - 35) Shibata Y, Matsuda M, Suzuki K, Matsumura A: Cystic neurohypophysial germinoma associated with moyamoya disease. *Neurol Sci* 31: 189–192, 2010
 - 36) Tada T, Ishii K, Oshima S, Hara H, Kobayashi S: Secretory meningioma associated with numerous meningotheelial rosettes. *Acta Neuropathol* 84: 342–345, 1992
 - 37) Uchida K, Arakawa Y, Ohya K, Sirakawa M, Tsuji R, Yokoyama M, Imataka K, Sato M, Shimizu Y: Growth hormone-secreting pituitary adenoma associated with primary moyamoya disease—case report. *Neurol Med Chir (Tokyo)* 43: 356–359, 2003
 - 38) Van Roost D, Kristof R, Zentner J, Wolf HK, Schramm J: Clinical, radiological and therapeutic features of pleomorphic xanthoastrocytoma: report of three patients and review of the literature. *J Neurol Neurosurg Psychiatry* 60: 690–692, 1996
 - 39) Whittle IR, Gordon A, Misra BK, Show JF, Steers AJ: Pleomorphic xanthoastrocytoma. Report of four cases. *J Neurosurg* 70: 463–468, 1989
 - 40) Yamauchi T, Tada M, Houkin K, Tanaka T, Nakamura Y, Kuroda S, Abe H, Inoue T, Ikezaki K, Matsushima T, Fukui M: Linkage of familial moyamoya disease (spontaneous occlusion of the circle of Willis) to chromosome 17q25. *Stroke* 31: 930–935, 2000

Address reprint requests to: Satoshi Horiguchi, MD, Division of Neurosurgery, Ako City Hospital, 1090 Nakahiro, Ako, Hyogo 678-0232, Japan.
e-mail: horiguchi-nsu@umin.ac.jp