

## Multiple intracranial capillary hemangiomas and transient cerebrovascular insufficiency

Fahad Younas · Quratulain Durrani ·  
Muhammad A. Shahzad · Asim Mushtaq ·  
Sherwin Imlay

Received: 14 July 2010 / Accepted: 24 March 2011 / Published online: 30 April 2011  
© Springer-Verlag 2011

**Abstract** Hemangiomas constitute a heterogeneous group of benign vascular proliferations of skin and mucous membranes and very rarely known to develop in the brain or spinal cord. We report here a case of multiple intracranial capillary hemangiomas presenting with transient neurological deficit. The patient underwent stealth MRI brain utilizing 15 ml of Magnevist for stereotactic localization and biopsy was done to establish the diagnosis. It is pivotal to differentiate benign hemangiomas from primary cerebral vascular tumors including hemangioblastoma, hemangioendothelioma and hemangiopericytoma, as later are known for more aggressive biologic behavior.

**Keywords** Intracranial hemangioma ·  
Capillary hemangioma

Cerebral hemangiomas are rarely reported in adults and generally considered as malformations or hamartomas. We report here a case of multiple intracranial capillary hemangiomas presenting with transient neurologic deficit. A 69-year-old male with no significant past medical history

was admitted to a hospital after having found unconscious in his house with a bruise on forehead suggestive of fall for unknown duration. The patient regains consciousness in emergency room, but had a left-sided weakness. Physical examination revealed power and tone were well intact in upper extremities; however, a considerable weakness (i.e., 3/5) in left lower extremity. Cranial nerves and sensations were intact and Babinski's sign was equivocal bilaterally. Laboratory findings including complete blood counts, electrolytes and renal functions were negative for any derangements.

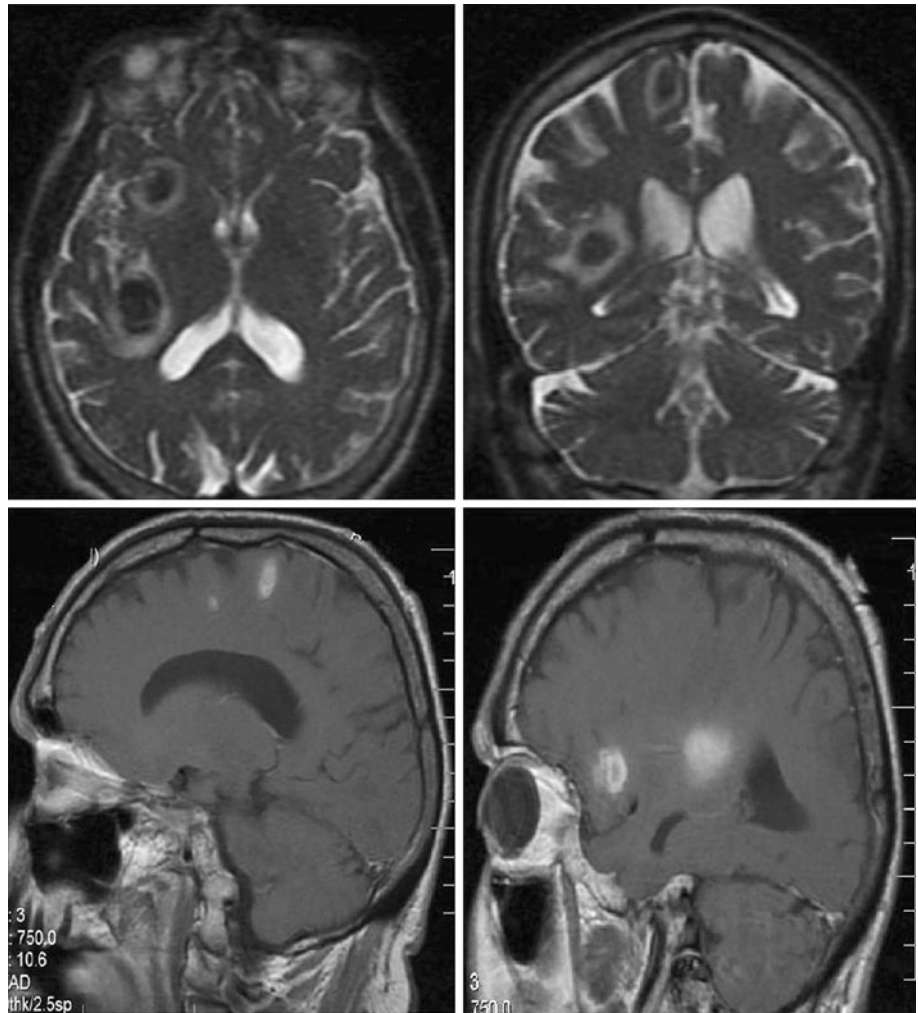
Computed tomography (CT) scan of head showed multiple hyper dense lesions mostly in sub-cortical regions in bilateral hemispheres (Fig. 1). MRI confirmed five non-enhancing intraparenchymal hemorrhagic lesions (three right frontal lobe lesions 1.9 × 1.4 cm, 1.0 × 1.0 cm, 0.5 × 0.6 cm, right temporal/parietal lobe lesion 2.0 × 2.5 cm, and left frontal lobe lesion 0.5 × 0.5 cm) (Fig. 2). Due to lack of enhancement of these lesions on post contrast images, underlying hemorrhagic metastases were considered less likely. Differential diagnostic considerations were given to cerebral amyloid angiopathy, vasculitis or a vascular anomaly such as multiple angiomas.

CT scan of lungs and abdomen/pelvis with intravenous and oral contrast was unable to identify any primary lesions. The patient underwent stealth MRI brain utilizing 15 ml of Magnevist for stereotactic localization. Biopsy was obtained from the right frontal lesion. First, biopsy was taken and it showed old blood clot and necrotic tissue. Three additional samples were taken at 90, 180 and 270 degrees; the frozen section was inconclusive and no firm diagnosis was made. Additional biopsies were obtained for both above and below this level approximately 5 mm each in 360 degrees. These

F. Younas (✉) · Q. Durrani · M. A. Shahzad · A. Mushtaq  
Department of Internal Medicine, St. Joseph Mercy Oakland,  
44405 Woodward Avenue, Pontiac, MI 48341, USA  
e-mail: younasf@trinity-health.org

S. Imlay  
Department of Pathology, St. Joseph Mercy Oakland,  
Pontiac, MI, USA

**Fig. 1** CT of head showed multiple hyper dense lesions mostly in sub-cortical regions in bilateral hemispheres



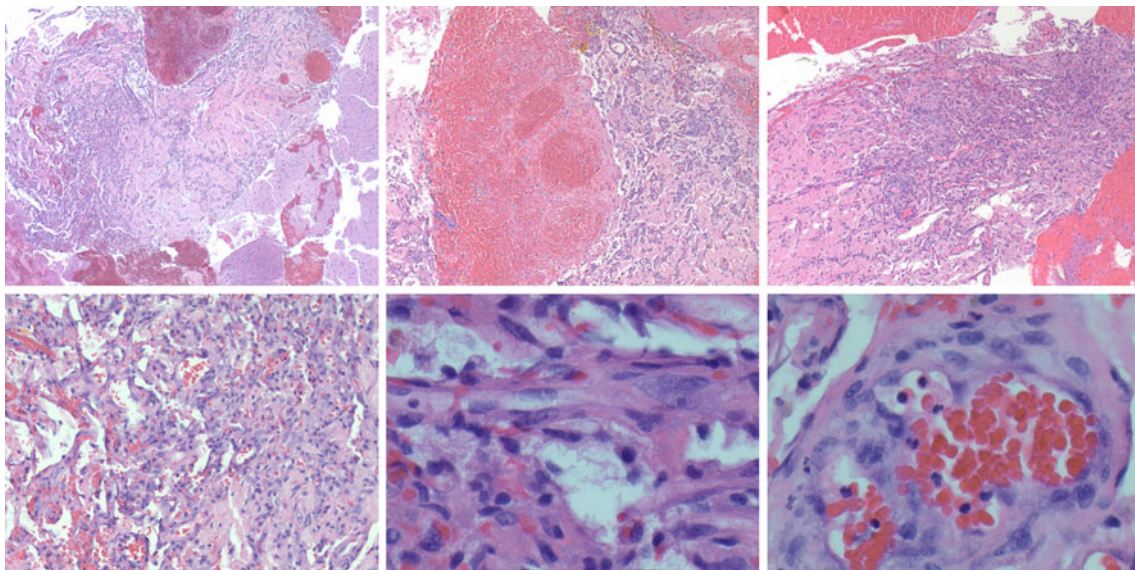
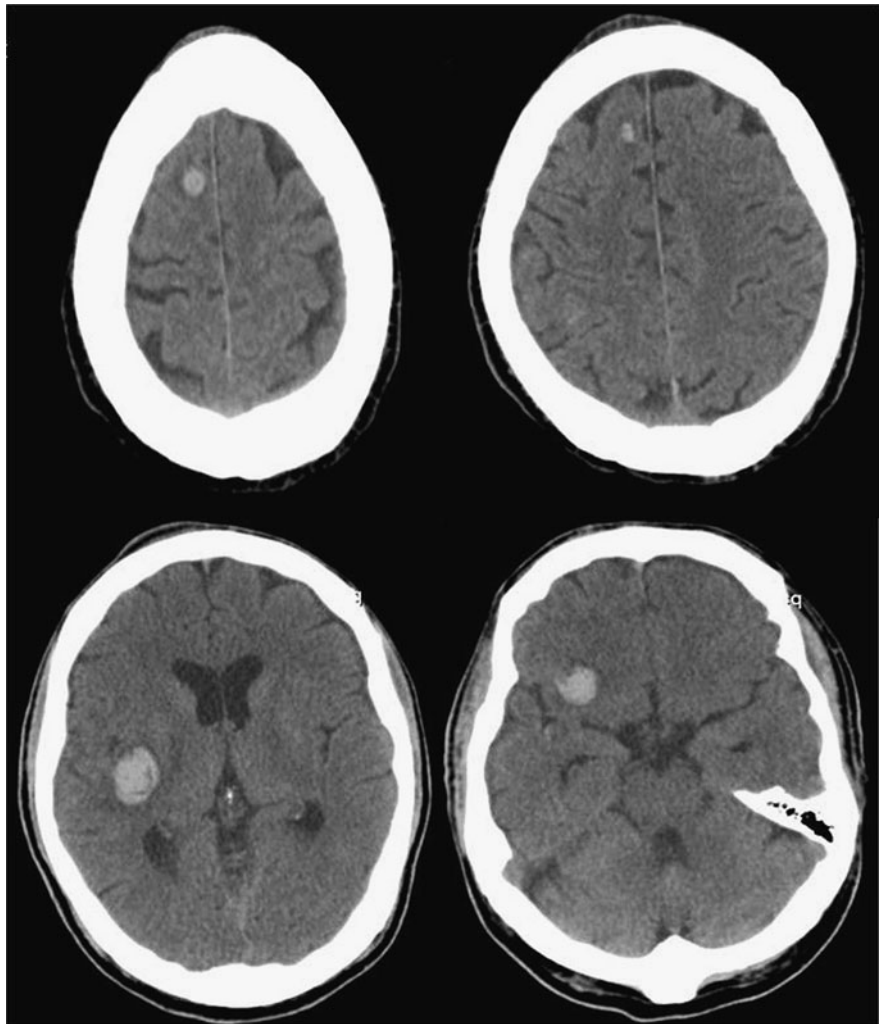
cores were sent for permanent section. Final anatomic pathology showed closely packed capillary blood vessels with round and/or slit-like lumina containing mostly red blood cells. There was no metastatic carcinoma or atypical glial proliferation but focal areas of hemorrhage, fibrin and hemosiderin. There was no evidence suggestive of vasculitis or any granulomatous inflammation. The Congo red stain did not show amyloid deposition. A proliferation of small capillaries was therefore considered central nervous system capillary hemangioma (CNSCH) (Fig. 3).

No further surgical intervention was done provided the multiplicity of the lesions and having complete resolution of symptoms within 24 h of hospitalization with no recurrence. The patient was sent home on seizure prophylaxis and he remained asymptomatic on 3 months follow-up visit. He was advised for repeat imaging in 6–9 months to monitor any change in lesion size over time.

Histologically, CNSCH differ from both cavernous hemangiomas and capillary telangiectasias. Cavernous hemangiomas consist of dilated hyaline vessels and often show thrombosis, perivascular hemosiderin deposition, and calcification. Capillary telangiectasias of the CNS have neural parenchyma between vessels and lack lobularity and demarcation [1]. Final histopathologic findings in our patient revealed numerous, tightly packed, capillary-sized vessels that were lined by a single layer of cytologically benign endothelial cells, and similar findings were shared by the CNSCH studied by Abe M et al. [1].

It is important to differentiate CNSCH from primary cerebral vascular tumors including hemangioblastoma, hemangioendothelioma and hemangiopericytoma, as later are known for more aggressive biologic behavior [1]. Distinguishing capillary hemangioma from these malignant entities helps to prevent unnecessary morbidity due to unnecessary interventions [2].

**Fig. 2** MRI confirmed hemorrhagic lesions (three right frontal lobe lesions 1.9 × 1.4 cm, 1.0 × 1.0 cm, 0.5 × 0.6 cm, right temporal/parietal lobe lesion 2.0 × 2.5 cm, and left frontal lobe lesion 0.5 × 0.5 cm)



**Fig. 3** Histologic images showed closely packed capillary blood vessels with round and/or slit-like lumina containing mostly red blood cells. There was no metastatic carcinoma or atypical glial

proliferation but focal areas of hemorrhage, fibrin and hemosiderin. There was no evidence suggestive of vasculitis or any granulomatous inflammation

**Conflict of interest** None of the authors have any financial or other potential conflicts of interest relative to the data in this manuscript.

- comparative study with lobular capillary hemangioma of the skin. *Acta Neuropathol* 109(2):151–8. [Epub 2004 Sep 7]
2. Simon SL, Moonis G, Judkins AR, Scobie J, Burnett MG, Riina HA, Judy KD (2005) Intracranial capillary hemangioma: case report and review of the literature. *Surg Neurol* 64((2):154–159

## References

1. Abe M, Misago N, Tanaka S, Masuoka J, Tabuchi K (2005) Capillary hemangioma of the central nervous system: a