

University of Groningen

Brain abscess associated with *Aggregatibacter actinomycetemcomitans*

Rahamat-Langendoen, Janette C.; van Vonderen, Marit G. A.; Engstrom, Lex J.; Manson, Willem L.; van Winkelhoff, Arie Jan; Mooi-Kokenberg, Esther A. N. M.

Published in:
Journal of Clinical Periodontology

DOI:
[10.1111/j.1600-051X.2011.01737.x](https://doi.org/10.1111/j.1600-051X.2011.01737.x)

IMPORTANT NOTE: You are advised to consult the publisher's version (publisher's PDF) if you wish to cite from it. Please check the document version below.

Document Version
Publisher's PDF, also known as Version of record

Publication date:
2011

[Link to publication in University of Groningen/UMCG research database](#)

Citation for published version (APA):

Rahamat-Langendoen, J. C., van Vonderen, M. G. A., Engstrom, L. J., Manson, W. L., van Winkelhoff, A. J., & Mooi-Kokenberg, E. A. N. M. (2011). Brain abscess associated with *Aggregatibacter actinomycetemcomitans*: case report and review of literature. *Journal of Clinical Periodontology*, 38(8), 702-706. <https://doi.org/10.1111/j.1600-051X.2011.01737.x>

Copyright

Other than for strictly personal use, it is not permitted to download or to forward/distribute the text or part of it without the consent of the author(s) and/or copyright holder(s), unless the work is under an open content license (like Creative Commons).

The publication may also be distributed here under the terms of Article 25fa of the Dutch Copyright Act, indicated by the "Taverne" license. More information can be found on the University of Groningen website: <https://www.rug.nl/library/open-access/self-archiving-pure/taverne-amendment>.

Take-down policy

If you believe that this document breaches copyright please contact us providing details, and we will remove access to the work immediately and investigate your claim.

Downloaded from the University of Groningen/UMCG research database (Pure): <http://www.rug.nl/research/portal>. For technical reasons the number of authors shown on this cover page is limited to 10 maximum.

Case Report

Brain abscess associated with *Aggregatibacter actinomycetemcomitans*: case report and review of literature

Janette C. Rahamat-Langendoen^{1,2},
Marit G. A. van Vonderen³,
Lex J. Engström⁴, Willem L. Manson²,
Arie Jan van Winkelhoff^{2,5} and Esther
A. N. M. Mooi-Kokenberg¹

¹Department of Microbiology, Izore Centre for Infectious Diseases Friesland, Leeuwarden, The Netherlands; ²Department of Medical Microbiology, University Medical Centre Groningen, Groningen University, Groningen, The Netherlands; ³Department of Internal Medicine, Medical Centre Leeuwarden, Leeuwarden, The Netherlands; ⁴Department of Neurology, Medical Centre Leeuwarden, Leeuwarden, The Netherlands; ⁵Centre for Dentistry and Oral Hygiene, University Medical Centre Groningen, Groningen University, Groningen, The Netherlands

Rahamat-Langendoen JC, van Vonderen MGA, Engström LJ, Manson WL, van Winkelhoff AJ, Mooi-Kokenberg EANM. Brain abscess associated with *Aggregatibacter actinomycetemcomitans*: case report and review of literature. J Clin Periodontol 2011; 38: 702–706. doi: 10.1111/j.1600-051X.2011.01737.x.

Abstract

Introduction: *Aggregatibacter actinomycetemcomitans* is considered a major pathogen in localized and generalized aggressive periodontitis. *A. actinomycetemcomitans* has been found in various extra oral infections and most frequently in endocarditis. We report a patient with multiple brain abscesses due to infection with *A. actinomycetemcomitans* and review the English language literature related to this subject.

Case report: A 42-year-old patient with no underlying medical conditions presented with multiple brain lesions initially thought to be metastatic lesions of a tumour of unknown origin. Findings during drainage and subsequent histopathological conclusions made infection more likely. Culture of drained material remained negative; however, 16S rDNA polymerase chain reaction and sequence analysis on direct material revealed *A. actinomycetemcomitans* as the causative agent of the infection. The most likely source of infection was the poor dentition of the patient. After repeated drainage of the lesions and antibiotic treatment the patient gradually improved, although cognitive impairment remained.

Conclusions: Our report illustrates that a poor dental condition, notably destructive periodontal disease, can be a risk for life-threatening extra oral disease, and thus contributes to the total inflammatory burden of the body.

Key words: *Aggregatibacter actinomycetemcomitans*; brain abscess; extra oral infection; periodontal disease; sequence analysis

Accepted for publication 6 April 2011

Dental condition has been linked to several non-oral diseases such as infectious bowel diseases, atherosclerosis, coronary heart diseases, stroke, diabetes and rheumatoid arthritis. The link between destructive periodontal disease and these chronic disorders can be explained by common risk factors such

as smoking, stress and possibly genetic traits.

Periodontitis is a bacterial infection of the tooth-supporting tissues characterized by a large inflamed and necrotic area associated with a high bacterial load and destruction of the alveolar bone (Nesse et al. 2008). The infected periodontium can act as a focus for extra oral infections by dissemination of periodontal bacteria to non-oral body sites. Periodontitis may thus contribute to the total inflammatory burden of the body.

Aggregatibacter actinomycetemcomitans is considered a major pathogen in

localized and generalized aggressive periodontitis (Zambon 1985). *A. actinomycetemcomitans* has been found in various extra oral infections, most frequently in endocarditis (van Winkelhoff & Slots 1999). We report a patient with multiple brain abscesses due to infection with *A. actinomycetemcomitans* and review the English language literature related to this subject.

Case Report

A 42-year-old man was admitted to the Medical Centre Leeuwarden with a 3

Conflict of interest and source of funding statement

The authors declare that they have no conflict of interests.
No financial support was received.

days history of confusion and reduced consciousness. Besides heavy smoking and alcohol abuse there was no relevant medical history. Physical examination revealed a slowly reacting man, who did not respond adequately. Oral examination showed severe candidiasis and the orthopantomogram revealed caries profunda in multiple teeth and severe periodontal break down (Fig. 1).

There was no heart murmur and petechiae were not seen. No focal signs were detected at neurological examination. Laboratory data revealed an elevated white blood count ($17.1 \times 10^9/l$) and a moderately elevated C-reactive protein (34 mg/l). Liver enzymes and renal function tests showed normal values. Computed tomography (CT) of the brain showed multiple intracerebral lesions with, after injection of intravenous contrast, ring enhancement surrounded by oedema (Fig. 2). The lesions were primarily thought to be brain metastases of an unidentified tumour. Magnetic resonance imaging confirmed the findings with no signs of lesions elsewhere in the body. A chest X-ray provided no indications for malignancy in the lungs. Serological tests for infection with human immunodeficiency virus and Toxoplasma were negative. Blood cultures taken at admission were negative. The patient was treated with dexamethasone. A follow-up CT after 4 days showed no improvement regarding the cerebral lesions and the surrounding oedema. The patient was transferred to the University Medical Centre Groningen for stereotactic biopsy and further treatment. Upon biopsying the lesions appeared to be abscesses and pus was collected from a lesion in the right frontal region. Histopathological examination revealed reactive inflammatory changes with necrosis and no signs of malignancy. At gram staining no microorganisms and few leucocytes were seen. Blood, chocolate, and MacConkey's 3 agar and Fastidious broth were inoculated and incubated in air with 5% CO₂ at 35°C. Anaerobic cultures were performed on selective media and incubated in 80% N₂, 10% H₂, and 10% CO₂. The plates were examined for the presence of colonies over the course of 10 days. Post-operative empiric intravenous antibiotic treatment was initiated with ceftriaxone 2 g bid, metronidazole 500 mg bid and penicillin six times a day 2 million units. Aerobic and anaerobic culture remained negative and 16S rDNA polymerase chain reaction (PCR) and sequence ana-

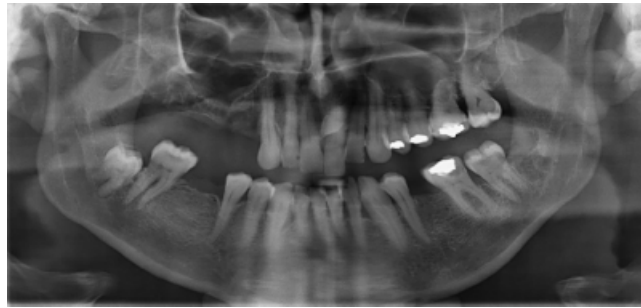

Fig. 1. Orthopantomogram revealing caries profunda in multiple teeth and severe periodontal break down.

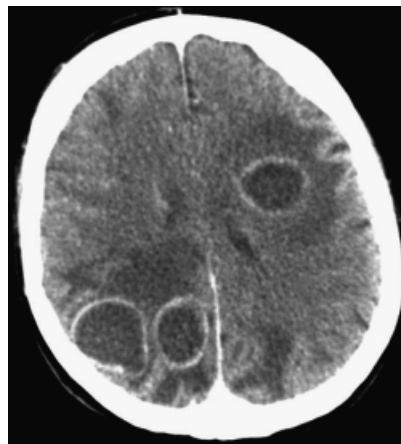


Fig. 2. Computed tomogram brain. Abscesses visible in right and left cerebrum.

lysis on direct material was performed 4 days after drainage. Sequence data were compared with known sequences of 16S rDNA in the National Centre for Biotechnology Information Genbank. The highest similarity (99.8%) was found with *A. actinomycetemcomitans*. No other microorganisms were detected. The patient continued to receive ceftriaxone and metronidazole intravenously, because a mixed anaerobic infection could not be excluded definitively. During his stay at the hospital the patient did not develop signs of endocarditis. A trans-thoracic echocardiogram made 1 week after operation showed no valvular vegetations. Besides his poor oral health no other focus of infection could be found. Nine days after the operation the patient deteriorated with reduced consciousness. CT of the brain showed no signs of expansion of the lesions, but because of the deterioration it was decided to drain four lesions. During this operation the oral surgeon extracted five teeth because of advanced perio-

dontal break down. Although the patient gradually improved, supported by diminishment of the lesions on CT scan, cognitive impairment remained. In the convalescent period the patient developed focal epilepsy with secondary generalization. Treatment with sodium valproate was started. Parenteral antibiotic treatment was continued for 6 weeks, after which the patient was transferred to a rehabilitation centre for intensive rehabilitation. His condition improved rapidly and after 4 weeks he was able to return to his home. Besides epileptic seizures which made four short-term admissions to the hospital necessary during a 1 year follow-up, he showed no other sequelae of his disease.

Discussion

A. actinomycetemcomitans is a non-motile, facultative anaerobic small Gram-negative coccobacillus (von Graevenitz & Zbinden 2007). Its fastidious slow-growing nature makes it difficult to isolate through culture, especially because it is often part of mixed infection with other bacteria. Incubation on blood and chocolate agar for at least 48 h is needed in enhanced atmosphere with CO₂. *A. actinomycetemcomitans* was first described as a human pathogen in 1912 by Klinger (1912). It was initially isolated in conjunction with *Actinomyces israelii*, leading to the speculation that *A. actinomycetemcomitans* itself was not capable of causing disease. After the introduction of penicillin, which eradicated *Actinomyces*, pure cultures of *A. actinomycetemcomitans* were increasingly reported from various body sites and organs (Page & King 1966). It is recognized as one of the major pathogens in periodontitis. Besides, it is reported as cause of soft tissue infection (usually

Table 1. Reported cases of cerebral abscesses due to infection with *Aggregatibacter actinomycetemcomitans*

Sex/age (year)	Underlying illness	Source	Presenting symptoms	Localization	Infection	Mixed with	Antibiotic treatment	Duration	Outcome	Author/year
M/62	Carcinoma left ear	Orogenous	Drainage left ear, confusion	Posterior inferior temporal region	Single		Pen+Chlo+Co	3 weeks (until death)	Died	Martin et al. (1967)
M/31	None	?	Right haemianopsia	Left parietal-occipital	Single		Amp+strep	2 weeks	Recovered	Burgher et al. (1973)
?	?	?			Single		?	?	?	Brewer et al. (1975)
?	?	?				?	?	?	?	Brewer et al. (1975)
M/34	None	Dental	Headache, vomiting	Left frontal region		Anaerobic streptococci, <i>Fusobacterium polymorphum</i> , <i>Bacteroides melaninogenicus</i> , <i>Streptococcus milleri</i>	Amp+Ge+Me	?	Recovered	Ingham et al. (1978)
F/7	Cyanotic congenital heart disease	?	Headache, irritability	Left frontal region	Single		Clo	At least 4 weeks	Recovered	Gamer (1979)
M/36	None	Dental	Headache, convulsion	Right frontal lobe		<i>Fusobacterium nucleatum</i>	Me+Chlo	?	Recovered	Churton & Greer (1980)
F/15	Neurosurgery for meningioma	Nasopharynx	Headache, fever	Right frontal region		<i>Eikenella corrodens</i> , <i>Haemophilus aphrophilus</i>	Chlo+Me	1 month	Recovered	Kaplan et al. (1989)
M/44	Alcohol abuse, emphysema	Dental	Right-sided weakness, speaking disorder	Left fronto-parietal region, right occipital		<i>Actinomyces meyeri</i>	Amox	12 months	Recovered	Kuijper et al. (1992)
M/41	None	Dental	Convulsion	Left frontoparietal region		Actinomyces	Chlo	6 weeks	Recovered	Zijlstra et al. (1992)
M/19	None	Dental	Headache, vomiting, right-sided weakness	Left parietal region	Single		Chlo+Cefo	10 weeks	Recovered	Renton et al. (1996)
M/47	Alcohol abuse	Dental	Headache, vomiting, left-sided weakness	Right occipital lobe	Single		Ceftriaxon	4 weeks	Recovered	Stepanovic et al. (2005)

Pen, penicillin; Chlo, chloramphenicol; Co, collistin; Amp, ampicillin; Strep, streptomycin; Ge, gentamycin; Me, metronidazole; Amox, amoxicillin; Cefo, cefotaxime; M, male; F, female.

in association with *A. israelii* or *Actinomyces meyeri*) and endocarditis. Rarely, *A. actinomycetemcomitans* has been isolated from patients with endophthalmitis, septic arthritis, osteomyelitis, pneumonia, empyema, infected pacemaker wire, and spinal epidural abscess (Kaplan et al. 1989, Yuan et al. 1992, van Winkelhoff et al. 1993, Binder et al. 2003). Extra oral infections are thought to occur due to haematogenous dissemination from the infected periodontium (van Winkelhoff & Slots 1999). Indeed, the poor dentition of our patient is thought to be the most likely source of infection, although we have no information regarding the presence or absence of *A. actinomycetemcomitans* in material of the extracted teeth. Also, the oral candidiasis may have been a factor that has facilitated invasion of *A. actinomycetemcomitans*. Endocarditis was considered unlikely because of the absence of clinical signs of endocarditis and the absence of vegetations at echocardiography.

A review of the English language literature reveals 12 reports of brain abscesses due to infection with *A. actinomycetemcomitans* (Martin et al. 1967, Burgher et al. 1973, Brewer et al. 1975, Ingham et al. 1978, Garner 1979, Churton & Greer 1980, Kaplan et al. 1989, Kuijper et al. 1992, Zijlstra et al. 1992, Renton et al. 1996, Stepanovic et al. 2005) (Table 1). All but two reports are of male patients in the age of 19–62 years. In six patients the most probable source of infection was poor dentition or recent dental therapy, emphasizing the importance of considering the dental region as the origin of brain abscesses due to *A. actinomycetemcomitans*. Also, in six patients the insidious onset of symptoms was more characteristic of a neoplastic rather than an infectious process, as was the initial suspicion in our patient. Culture of the brain lesions revealed mixed infection with associated aerobic and anaerobic microorganisms in six patients; not surprisingly, considering the source of infection, the identified microorganisms were mainly common pathogens of the oro-pharyngeal region.

The optimal treatment of brain abscesses consists of surgical drainage combined with antibiotic therapy. *A. actinomycetemcomitans* is usually susceptible to cephalosporins (especially third generation cephalosporins), ampicillin, rifampin, fluoroquinolones, trimethoprim-sulfamethoxazole, aminoglycosides, and

chloramphenicol. In vitro, there is variable susceptibility to penicillin. Clindamycin and metronidazole have poor activity against *A. actinomycetemcomitans*, but metronidazole in combination with amoxicillin has shown strong synergistic effect (Steinberg & Burd 2009).

The multiplicity of antibiotic regimes that has been used and the small number of patients do not permit identification of the ideal therapeutic regimen. Because of the potential of β -lactamase production and the difficulties with susceptibility testing because of fastidious growth, third generation cephalosporins are now considered the drugs of choice. The empirical treatment of our patient consisted of ceftriaxone, metronidazole, and penicillin, accounting for the microorganisms to be suspected in a brain abscess (streptococci, Gram-negative aerobes, and strict anaerobes). Based on the outcome of 16S rDNA PCR and sequence analysis, in combination with the most likely periodontal source of infection, it was decided to continue therapy for 6 weeks with ceftriaxone and metronidazole intravenously. To achieve definite improvement, however, a second surgical drainage was necessary, which emphasizes the importance of surgical treatment of brain abscesses.

Our report also illustrates the diagnostic value of gene amplification and sequencing from direct specimens for patients with culture negative infections who have a high likelihood of a bacterial infection. Microbiological detection of organisms in brain abscesses primarily relies on microscopic examination and culturing of abscess pus specimen collected during neurosurgical drainage. However, the incidence of negative cultures can be high, especially in patients in whom antibiotic therapy started before collection of the specimen (Tseng & Tseng 2006). Indeed, despite meticulous handling of the specimen and prolonged incubation in aerobic as well as anaerobic conditions, the cultures from our patient remained negative. Molecular detection of microorganisms in direct material can be used to overcome the limitations of culture-based bacteria detection (Tsai et al. 2004, Al Masalma et al. 2009). Although susceptibility testing is not feasible for culture negative, PCR positive specimens, molecular identification can guide the choice of antimicrobial treatment, thereby shortening the period of empirical treatment with multiple broad spectrum antibiotics.

Conclusion

We describe a patient with multiple culture negative brain abscesses initially thought to be brain metastases of an unidentified tumour. Detection and identification of the oral pathogen *A. actinomycetemcomitans* was established by 16S rDNA sequencing on direct material, giving guidance to diagnosis and therapy. The patient's well-documented destructive periodontal disease is considered the most likely focus of infection. Also, the oral cavity has been identified as the primary ecological niche of *A. actinomycetemcomitans*. This report illustrates that severe periodontal infection can be a risk for serious and life-threatening extra oral disease.

References

- Al Masalma, M., Armougom, F., Scheld, W. M., Dufour, H., Roche, P. H., Drancourt, M. & Raoult, D. (2009) The expansion of the microbiological spectrum of brain abscesses with use of multiple 16S ribosomal DNA sequencing. *Clinical Infectious Diseases* **48**, 1169–1178.
- Binder, M. I., Chua, J., Kaiser, P. K., Mehta, N. & Isada, C. M. (2003) *Actinobacillus actinomycetemcomitans* endogenous endophthalmitis: report of two cases and review of the literature. *Scandinavian Journal of Infectious Diseases* **35**, 133–136.
- Brewer, N. S., MacCarty, C. S. & Wellman, W. E. (1975) Brain abscess: a review of recent experience. *Annals of Internal Medicine* **82**, 571–576.
- Burgher, L. W., Loomis, G. W. & Ware, F. (1973) Systemic infection due to *Actinobacillus actinomycetemcomitans*. *American Journal of Clinical Pathology* **60**, 412–415.
- Churton, M. C. & Greer, N. D. (1980) Intracranial abscess secondary to dental infection. *The New Zealand Dental Journal* **76**, 58–60.
- Garner, J. G. (1979) Isolation of *Actinobacillus actinomycetemcomitans* and *Haemophilus aphrophilus* at Auckland hospital. *New Zealand Dental Journal* **89**, 384–386.
- Ingham, H. R., Kalbag, R. M., Tharagotnet, D., High, A. S., Sengupta, R. P. & Selkon, J. B. (1978) Abscesses of the frontal lobe of the brain secondary to covert dental sepsis. *The Lancet* **2**, 497–499.
- Kaplan, A. H., Weber, D. J., Oddone, E. Z. & Perfect, J. R. (1989) Infection due to *Actinobacillus actinomycetemcomitans*: 15 cases and review. *Review of Infectious Diseases* **11**, 46–63.
- Klinger, R. (1912) Untersuchungen ueber menschliche Aktinomykose. *Zentralblatt Bakteriologie* **62**, 191–200.
- Kuijper, E. J., Wiggerts, H. O., Jonker, G. J., Schaal, K. P. & de Gans, J. (1992) Disseminated actinomycosis due to *Actinomyces meyeri* and *Actinobacillus actinomycetemcomitans*. *Scandinavian Journal of Infectious Diseases* **24**, 667–672.
- Martin, B. F., Derby, B. M., Budzilovich, G. N. & Ransohoff, J. (1967) Brain abscess due to *Actinobacillus actinomycetemcomitans*. *Neurology* **17**, 833–837.
- Nesse, W., Abbas, F., van der Ploeg, I., Spijkervet, F. K., Dijkstra, P. U. & Vissink, A. (2008) Periodontal inflamed surface area: quantifying inflammatory burden. *Journal of Clinical Periodontology* **35**, 668–673.

- Page, M. I. & King, E. O. (1966) Infection due to *Actinobacillus actinomycetemcomitans* and *Haemophilus aphrophilus*. *New England Journal of Medicine* **275**, 181–188.
- Renton, T. F., Danks, J. & Rosenfeld, J. V. (1996) Cerebral abscess complicating dental treatment. Case report and review of the literature. *Australian Dental Journal* **41**, 12–15.
- Steinberg, J. P. & Burd, E. M. (2009) Other gram-negative and gram-variable bacilli. In: Mandell, G. L., Bennet, J. E. & Dolin, R. (eds). *Principles and Practice of Infectious Diseases*, pp. 3015–3017. Philadelphia: Churchill Livingstone Elsevier.
- Stepanovic, S., Tomic, T., Savic, B., Jovanovic, M., K'ouas, G. & Carlier, J. P. (2005) Brain abscess due to *Actinobacillus actinomycetemcomitans*. *APMIS* **113**, 225–228.
- Tsai, J. C., Teng, L. J. & Hsueh, P. R. (2004) Direct detection of bacterial pathogens in brain abscesses by polymerase chain reaction amplification and sequencing of partial 16S ribosomal deoxyribonucleic acid fragments. *Neurosurgery* **55**, 1154–1162.
- Tseng, J. H. & Tseng, M. Y. (2006) Brain abscess in 142 patients: factors influencing outcome and mortality. *Surgical Neurology* **65**, 557–562.
- van Winkelhoff, A. J., Overbeek, B. P., Pavicic, M. J. A. M. P., van den Bergh, J. P., Ernst, J. P. & de Graaff, J. (1993) Long-standing bacteremia caused by oral *Actinobacillus actinomycetemcomitans* in a patient with a pacemaker. *Clinical Infectious Diseases* **16**, 216–218.
- van Winkelhoff, A. J. & Slots, J. (1999) *Actinobacillus actinomycetemcomitans* and *Porphyromonas gingivalis* in nonoral infections. *Periodontology* **20**, 122–135.
- von Graevenitz, A. & Zbinden, R. (2007) *Actinobacillus*, *Capnocytophaga*, *Eikenella*, *Kingella*, *Pasteurella*, and other fastidious or rarely encountered gram-negative rods. In: Murray, P. R. & Baron, E. J. (eds). *Manual of Clinical Microbiology*, pp. 621–636. Washington, DC: ASM Press.
- Yuan, A., Yang, P. C., Lee, L. N., Chang, D. B., Kuo, S. H. & Luh, K. T. (1992) *Actinobacillus actinomycetemcomitans* pneumonia with chest wall involvement and rib destruction. *Chest* **101**, 1450–1452.
- Zambon, J. J. (1985) *Actinobacillus actinomycetemcomitans* in human periodontal disease. *Journal of Clinical Periodontology* **12**, 1–20.
- Zijlstra, E. E., Swart, G. R., Godfroy, F. J. & Degener, J. E. (1992) Pericarditis, pneumonia and brain abscess due to a combined *Actinomyces* – *Actinobacillus actinomycetemcomitans* infection. *Journal of Infection* **25**, 83–87.

Address:

Janette C. Rahamat-Langendoen
 Department of Medical Microbiology
 University Medical Centre Groningen
 Groningen University
 PO Box 30 001
 3700 RB Groningen
 The Netherlands
 E-mail: j.c.rahamat@mmb.umcg.nl

Clinical relevance

Scientific rationale for study: *A. actinomycetemcomitans* is a major pathogen in periodontitis. In this case report we show the relevancy of oral health in relation to life-threatening extra oral infection.

Principal findings: A 42-year-old patient with poor dentition was found to have multiple brain abscesses caused by *A. actinomycetemcomitans*, detected by 16S rDNA PCR and sequence analysis on direct material.

Practical implications: Poor oral health is an important contributing factor to severe extra oral infection. We illustrate the diagnostic value of gene amplification and sequencing from direct specimens for patients with culture negative infections.