

Internal Carotid Artery Pseudoaneurysm With Life-Threatening Epistaxis as a Complication of Deep Neck Space Infection

Paulo Sérgio Lucas da Silva, MD and Daniel Reis Waisberg, MD

Abstract: Pseudoaneurysm of the cervical internal carotid artery is a very rare, potentially fatal complication of a neck space infection in children associated with high mortality and morbidity. A 3-year-old boy presented with spontaneous massive epistaxis 45 days after a deep neck space infection caused by a peritonsillar abscess. During nasopharyngeal packing, he evolved with cardiac arrest. Intra-arterial angiography was then performed that revealed a large pseudoaneurysm. Endovascular treatment using detachable balloons achieved complete exclusion of the pseudoaneurysm. The child made an uneventful recovery and was discharged with mild left hemiparesis and no deficit of sensory or cognitive functions. Pseudoaneurysms of the internal carotid artery after a deep neck space infection can be associated with delayed and potentially fatal massive epistaxis. Furthermore, a regional (ie, extranasal) blood vessel should be promptly investigated when there are signs of hypovolemic shock. A high level of suspicion and definitive treatment are essential for successful management of these patients.

Key Words: endovascular treatment, epistaxis, internal carotid artery, pseudoaneurysm

(*Pediatr Emer Care* 2011;27: 422–424)

Pseudoaneurysm of the internal carotid artery (ICA) is a rare, potentially fatal complication of a neck space infection associated with high mortality and morbidity.¹ Pseudoaneurysm of the ICA may result from penetrating or blunt trauma, surgery, endovascular procedures, inflammation, or radiation.² The incidence of ICA pseudoaneurysm complicating deep neck space infection has declined significantly after the advent of antibiotics.¹ The natural history of untreated cases carries a poor prognosis as highlighted in the landmark article by Salinger and Pearlman.³ In their series, the mortality rate among patients not undergoing surgery was 77% compared with 36% in those undergoing ligation of the affected artery.³

Massive epistaxis is a rare manifestation of ICA pseudoaneurysm.⁴ However, there are a few pediatric reports describing ICA pseudoaneurysm presenting with nontraumatic massive epistaxis.^{4–7} In such cases, severe, delayed, life-threatening epistaxis often occurs after a latent period, and sometimes it is very difficult to ascertain the correlation between previous underlying cause and delayed massive epistaxis.⁸ Therefore, the rarity of these lesions in contemporary practice mandates a high level of suspicion so as to enable early detection and timely treatment.

CASE

A 3-year-old boy weighing 13 kg presented to our emergency department with a 1-hour history of spontaneous massive nasopharyngeal hemorrhage. The child had no family history of clotting disorders, although medical records showed a visit to an outside emergency department 45 days prior with fever, difficulty swallowing, sore throat, torticollis, and a 4-day swelling on the right side of the face. The patient was evaluated with a peritonsillar abscess that was drained via a transoral approach. After an uneventful hospital stay, he was discharged on postoperative day 16 and received a 4-week course of antibiotics. On admission, the patient was bleeding with an estimated loss of 30% of the total blood volume. Vital signs were body temperature of 36°C, heart rate of 164 beats/min, respiratory rate of 32 breaths/min, blood pressure of 100/62 mm Hg, and oxygen saturation of 92% in ambient air. On physical examination, the patient was pale, hypotonic, and intermittently lethargic but presented no respiratory distress. Axillary and femoral pulses were weak, and other pulses were not palpable. Distal extremities were cool with a 4-second capillary refill time. There were no bruises, cutaneous hemangioma, or visceral organomegaly. The decision was taken to obtain venous access and perform bilateral anterior and posterior nasopharyngeal packing to control bleeding. During the procedure, the child developed respiratory insufficiency and cardiovascular collapse. Cardiopulmonary resuscitation was started by 2 health care providers. Control of the airway was achieved through orotracheal intubation. The child's pulse returned after 30 minutes of chest compressions. Three hours later, the patient was transferred to the pediatric intensive care unit after receiving red blood cell transfusion and appropriate fluid replacement. Laboratory data showed hemoglobin level of 8.7 g/dL, platelets of 144,000/ μ L, partial thromboplastin time (38.5 seconds), international normalized ratio of 1.25, and fibrinogen of 2.3 g/L. Other blood tests were unremarkable. An initial computed tomography (CT) of the head revealed a densely enhanced right parapharyngeal mass situated at the anatomical position of the ICA (Fig. 1). Computed tomography angiography of the neck demonstrated an irregular saccular pseudoaneurysm originating from the cervical carotid artery. The child was referred for an endovascular intervention. The intra-arterial angiograph revealed a large saccular aneurysm with an irregular outline, arising from the right ICA and measuring 30 \times 20 mm (Fig. 2). The right cerebral hemisphere was shown to be supplied via anterior and posterior communicating arteries on left carotid and vertebral artery injections. A left carotid injection with compression of the right common carotid artery revealed almost simultaneous arterial and venous filling of both sides. A 6F guiding catheter was maneuvered to the right common carotid artery. A detachable balloon was deployed distal to the neck of the aneurysm, and 2 balloons were then maneuvered to the proximal segment of the ICA. A postembolization arteriogram showed complete occlusion of the right ICA, no visualization of the pseudoaneurysm, and

From the Pediatric Intensive Care Unit, Hospital Brigadeiro, São Paulo, Brazil.

Reprints: Paulo Sérgio Lucas da Silva, MD, Av. Brigadeiro Luiz Antonio 2651, Jd Paulista, São Paulo, Brazil 01402-000 (e-mail: psls.nat@terra.com.br).

Copyright © 2011 by Lippincott Williams & Wilkins
ISSN: 0749-5161

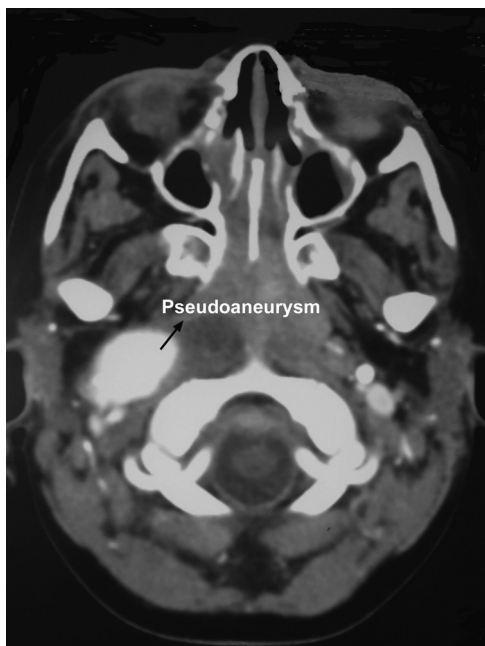

FIGURE 1. Contrast-enhanced CT scan axial section at the level of the oropharynx demonstrates an ovoid enhancing right parapharyngeal mass. This is situated at the anatomical position of the ICA and was consistent with an ICA pseudoaneurysm.

intact cerebral circulation via the circle of Willis. After the procedure, the patient was administered enoxaparin for 72 hours, followed by a long-term acetylsalicylic acid.

For the next 48-hour period, serial neurological examinations documented a mild left hemiparesis. Subsequent imaging studies showed no cerebrovascular compromise. The child made an uneventful recovery and was discharged on day 15. At 6-month follow-up, no neurological sequelae were evident.

DISCUSSION

Pseudoaneurysm of the ICA is rare, representing 5.6% of all carotid aneurysms and 23% to 48% of all extracranial aneurysms. Nearly half (48%) are large (1–2.5 cm), 34% are small (1 cm), and 16% are giant (2.5 cm).⁹ The pathogenesis of ICA pseudoaneurysms after deep neck space infection is not completely understood. However, the spread of infection into the parapharyngeal space seems to be an important factor.¹⁰ The parapharyngeal space contains the carotid arteries and lymph nodes draining the nose, nasopharynx, and tonsils and is frequently involved in pediatric head and neck infections.¹⁰ Although it is unclear how parapharyngeal space infection results in pseudoaneurysm formation, it is presumed that contiguous infections result in arteritis, which in turn, leads to vessel wall erosion.¹⁰

In our patient, the pseudoaneurysm was most likely a complication of a posttonsillitis parapharyngeal abscess reaching the adventitia of the ICA. Deep neck space infections most commonly result from otolaryngologic or upper respiratory tract infections in children and from odontogenic infections in adults.¹⁰ Less common causes include bacterial endocarditis, iatrogenic arterial or venous puncture, carotid endarterectomy, penetrating trauma, and pharyngeal foreign body.¹⁰ Arterial pseudoaneurysm formation complicating a deep neck space infection develops more commonly in children than in adults.¹⁰ Some authors have suggested this higher pediatric prevalence

may simply reflect the higher incidence of neck infections in children.^{10–12}

With regard to complications of ICA pseudoaneurysm rupture, epistaxis is rarely observed in children, a fact that may hamper its diagnosis.¹³ Moreover, the clinical presentation of severe or recurrent epistaxis and hematemesis in the absence of history of trauma or surgery may delay a definitive diagnosis because physicians direct the diagnostic workup at more common gastrointestinal, infectious, or systemic causes.¹³ The suspicion of a regional (ie, extranasal) blood vessel in our case was based on clinical manifestation of hemorrhagic shock. By the same token, this suspicion should be considered in cases of severe or recurrent epistaxis that do not respond to conservative nasal management.

Our child had an interval of 45 days between the initial infection and the diagnosis of a pseudoaneurysm. The interval between the initial infection and the diagnosis of a pseudoaneurysm varies from days to as long as 2 months, averaging approximately 14 days.¹⁰ Delayed epistaxis may be explained by the time necessary for the traumatic event to weaken the vessel wall and for pulsatile pressure to erode through any intact bone along the sphenoid sinus. Less commonly, pseudoaneurysms of the cervical ICA may rupture into the eustachian tube or the posterior nasopharynx. Mortality from hemorrhage of such lesions can reach as high as 50%.¹⁴

Some authors have reported additional clinical findings accompanying vascular complications of deep neck space infections. These have included recurrent small hemorrhages that may be from ear, nose, or throat; a protracted clinical course (usually greater than 7 to 14 days); and presentation with shock.¹⁵ Stevens¹⁶ included cranial neuropathies and Horner syndrome, as well as trismus, as potential indicators of vascular complication infections.

Although we found no reports in the literature associating the drainage procedure of peritonsillar abscess via transoral as a causal factor of carotid pseudoaneurysm, we believe this association is plausible in our patient. This observation is based on

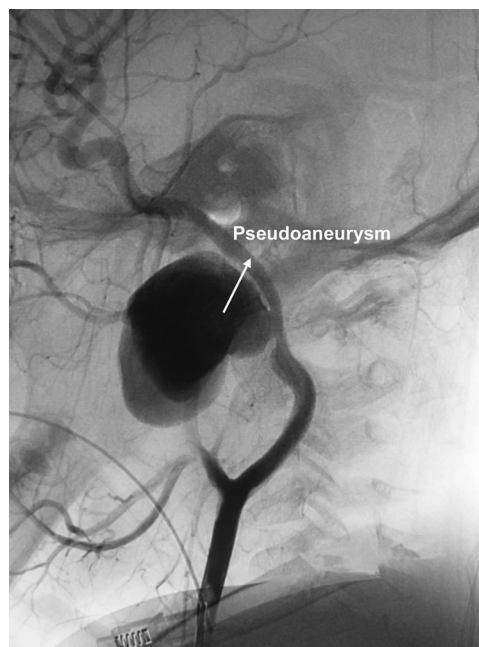


FIGURE 2. Right common carotid angiogram demonstrating pseudoaneurysm formation at the cervical segment of the ICA.

reports of carotid pseudoaneurysms as a posttonsillectomy complication.¹⁷⁻¹⁹ When considering transoral drainage of parapharyngeal abscesses, it is possible that complications may occur because of the close proximity of the ICA to the tonsillar fossa in children. In fact, this distance increases with age and weight of a child, attaining a maximum of approximately 2.8 cm posterolateral to the fossa by approximately 12 years of age or 56 kg.^{20,21} In addition, anatomical variation in the course of the ICA results in medialization of the cervicopharyngeal segment in approximately 1% of patients.²¹

It should be emphasized that, although rare, the first hemorrhage may be fatal.²² Immediate control of massive epistaxis is essential in reducing the mortality risk for these patients. Applying manual carotid pressure may be helpful while nasal packing is performed.²³

It should be emphasized that securing the airway can be problematic in the management of acute hemorrhage secondary to cervical pseudoaneurysm. Hence, tracheal intubation in patients with massive epistaxis is challenging and requires a team skilled in managing a difficult airway. Sound clinical judgment is critical for timing and selecting the optimal method for airway intervention.²⁴ Another important factor is the possibility of rupture during intubation or of aggravating the bleeding with risk of aspiration of blood or exsanguination that may deter physicians from proceeding directly with intubation before both securing endovascular access and controlling bleeding with nasal packing.

The diagnosis of a clinically suspected pseudoaneurysm should be confirmed using ultrasonography of the neck with colored Doppler flow, CT imaging, CT angiography, or magnetic resonance images. Angiography provides the most reliable and definitive diagnostic information and offers the opportunity of performing endovascular occlusion of the pseudoaneurysm. Computed tomographic and magnetic resonance imaging scans are helpful in providing information regarding structures surrounding the aneurysm and in clarifying the surgical approach to be taken.⁵

The pseudoaneurysm should be treated as early as possible to avoid thrombosis, embolization, or rupture. The ideal management would be to eliminate blood flow through the aneurysm and restore the blood flow through the artery. This prevents the complication associated with the aneurysm without compromising the distal flow that is crucial in the case of ICA.^{13,25}

In conclusion, although uncommon, vascular complications after deep neck space infections can have devastating consequences. We advocate that any patient presenting with massive epistaxis and a history of prior deep neck space infection, regardless of how remote, should be suspected as possible ICA pseudoaneurysm cases. Furthermore, a regional (ie, extranasal) blood vessel as the source of bleeding in hypovolemic shock should prompt rapid evaluation with a carotid angiogram.

REFERENCES

- Mordekar SR, Bradley PJ, Whitehouse WP, et al. Occult carotid pseudoaneurysm following streptococcal throat infection. *J Paediatr Child Health*. 2005;41:682-684.
- Ruiz-Juretschke F, Castro E, Mateo Sierra O, et al. Massive epistaxis resulting from an intracavernous internal carotid artery traumatic pseudoaneurysm: complete resolution with overlapping uncovered stents [published online ahead of print]. *Acta Neurochir (Wien)*. 2009;151(12):1681-1684.
- Salinger S, Pearlman S. Hemorrhage from pharyngeal and peritonsillar abscesses. Report of cases, resume of literature and discussion of the ligation of the carotid artery. *Arch Otolaryngol*. 1933;18:464-509.
- Gralla J, Brekenfeld C, Schmidli J, et al. Internal carotid artery aneurysm with life-threatening hemorrhages in a pediatric patient: endovascular treatment options. *J Endovasc Ther*. 2004;11:734-738.
- Meher R, Garg A, Malhotra V, et al. Pseudoaneurysm of the internal carotid artery in an infant aged 8 months. *N Z Med J*. 2006;119:U1815.
- Roebuck JC, Pereira KD. Idiopathic internal carotid artery aneurysm rupture in an infant: a case report. *Ear Nose Throat J*. 2009;88:835-837.
- Dai A, Jorges E. The problem with nose bleeds. *Emerg Med J*. 2005;22:596-597.
- Bavinzski G, Killer M, Knosp E, et al. False aneurysms of the intracavernous carotid artery—report of 7 cases. *Acta Neurochir (Wien)*. 1997;139:37-43.
- Sood S, Timothy J, Anthony R, et al. Extracranial internal carotid artery pseudoaneurysm. *Am J Otolaryngol*. 2000;21:259-262.
- Reisner A, Marshall GS, Bryant K, et al. Endovascular occlusion of a carotid pseudoaneurysm complicating deep neck space infection in a child. Case report. *J Neurosurg*. 1999;91:510-514.
- Watson MG, Robertson AS, Colquhoun IR. Pseudoaneurysm of the internal carotid artery: a forgotten complication of tonsillitis? *J Laryngol Otol*. 1991;105:588-590.
- Tannuri U, Mendes De Almeida N, Piske R, et al. Giant pseudoaneurysm of the internal carotid artery causing upper airway obstruction in a 10-month-old infant treated by endovascular occlusion and surgical drainage. *J Pediatr Surg*. 2003;38:1393-1395.
- Williams PM, Traquina DN, Wallace RC, et al. Coil embolization of a ruptured carotid pseudoaneurysm presenting as epistaxis—pediatric otolaryngology: principles and practice. *Am J Otolaryngol*. 2000;21:38-42.
- Chen D, Concus AP, Halbach VV, et al. Epistaxis originating from traumatic pseudoaneurysm of the internal carotid artery: diagnosis and endovascular therapy. *Laryngoscope*. 1998;108:326-331.
- Alexander DW, Leonard JR, Trail ML. Vascular complications of deep neck abscesses. A report of four cases. *Laryngoscope*. 1968;78:361-370.
- Stevens HE. Vascular complication of neck space infection: case report and literature review. *J Otolaryngol*. 1990;19:206-210.
- DeFatta RJ, Verret DJ, Bauer P. Extracranial internal carotid artery pseudoaneurysm. *Int J Pediatr Otorhinolaryngol*. 2005;69:1135-1139.
- Pourhassan S, Grottemeyer D, Fokou M, et al. Extracranial carotid arteries aneurysms in children: single-center experiences in 4 patients and review of the literature. *J Pediatr Surg*. 2007;42:1961-1968.
- Karas DE, Sawin RS, Sie KC. Pseudoaneurysm of the external carotid artery after tonsillectomy. A rare complication. *Arch Otolaryngol Head Neck Surg*. 1997;123:345-347.
- Hendrix RA, Bacon CK, Hoffer ME. Localization of the carotid artery within the tonsillar fossa by Doppler flow mapping. *Laryngoscope*. 1990;100:853-856.
- Deutsch MD, Kriss VM, Willging JP. Distance between the tonsillar fossa and internal carotid artery in children. *Arch Otolaryngol Head Neck Surg*. 1995;121:1410-1412.
- Shirai S, Tomono Y, Owada T, et al. Traumatic aneurysm of the internal carotid artery. Report of a case with late severe epistaxis. *Eur Neurol*. 1977;15:212-216.
- Fontela PS, Tampieri D, Atkinson JD, et al. Posttraumatic pseudoaneurysm of the intracavernous internal carotid artery presenting with massive epistaxis. *Pediatr Crit Care Med*. 2006;7:260-262.
- Ovassapian A, Tuncbilek M, Weitzel EK, et al. Airway management in adult patients with deep neck infections: a case series and review of the literature. *Anesth Analg*. 2005;100:585-589.
- Koroglu M, Arat A, Cekirge S, et al. Giant cervical internal carotid artery pseudoaneurysm in a child: endovascular treatment. *Neuroradiology*. 2002;44:864-867.