

A Case of Thalamic Pain Successfully Treated with Kampo Medicine

Keigo Ueda, MD, PhD,¹ Takao Namiki, MD, PhD,² Yuji Kasahara, MD, PhD,³ Atsushi Chino, MD, PhD,³ Hideki Okamoto, MD, PhD,³ Keiko Ogawa, MD, PhD,¹ and Katsutoshi Terasawa, MD, PhD⁴

Abstract

Objective: Thalamic pain, one of the central painful poststroke symptoms, is a severe pain that is often intractable. A case of thalamic pain successfully treated with Kampo medicine is presented.

Subject: A 65-year-old woman complained of moderate continuous and paroxysmal severe pain in the right upper and lower limbs after she had suffered from stroke. She also complained of sensory disturbance and intermittent involuntary movement. A magnetic resonance imaging scan of the brain showed an old infarction in the left thalamus.

Interventions and outcome: Paroxetine was administered, but it was stopped because of nausea. Etizolam was effective in reducing the pain for only about 30 minutes. *Sokeikakketsuto* decoction, one of the Kampo medicines, was administered orally on the basis of Kampo diagnostic criteria. Ten (10) days later, the pain had almost disappeared, and the other symptoms had also improved.

Conclusions: This result suggested that *Sokeikakketsuto* could be an option for the treatment of thalamic pain under certain conditions.

Introduction

THALAMIC PAIN, one of the symptoms of Déjerine-Roussy syndrome^{1,2} and included in the concept of central poststroke pain, is an unrelenting and often intolerable pain. Generally, it occurs from several weeks to several months after cerebrovascular disease. It is excruciatingly painful and is not treatable with ordinary analgesics. Antidepressants such as amitriptyline and selective serotonin reuptake inhibitors have been used to treat this symptom and they are effective to some degree. Antiepileptic drugs such as carbamazepine and gabapentin also have been used with some success. Neurosurgical approaches such as motor cortex stimulation and deep brain stimulation are also used for patients who cannot be treated with these drugs, although some patients cannot undergo such procedures.³ In summary, it is often difficult to improve the pain with these treatments, but alleviation of the pain is highly desirable, as it impairs not only the quality of life but also the daily activities of patients. In Japan, many Kampo (one of the Japanese traditional medicines) prescriptions have been used to treat painful symptoms,⁴ and in such cases as this they are often useful.

Case Report

The patient was a 65-year-old woman. Dysesthesia in the right upper and lower limbs and body, and slight weakness in the right upper limb suddenly occurred at the age of 61. She was diagnosed with brain infarction at another hospital, and was treated with medication and rehabilitation. When she was discharged, dysesthesia did not improve and slight gait disturbance remained. Furthermore, pain on the right side, especially upper limb pain, appeared several weeks later, gradually becoming severe. Moreover, she sometimes experienced intermittent involuntary movement in the right upper limb. Paroxetine was administered to treat this pain, but it was stopped because of nausea. Etizolam was effective in reducing the pain for only about 30 minutes, and her activities of daily life were extremely impaired.

The patient visited Chiba University Hospital in the third year after suffering the stroke. Some Kampo medicines were tried, but they were ineffective. Two (2) years later, pain and dysesthesia became acute, so she was admitted to our hospital.

¹Department of Japanese-Oriental (Kampo) Medicine, Chiba University Hospital, Chiba City, Japan.

²Department of Japanese-Oriental (Kampo) Medicine, Graduate School of Medicine, Chiba University, Chiba City, Japan.

³Department of Frontier Japanese-Oriental (Kampo) Medicine, Graduate School of Medicine, Chiba University, Chiba City, Japan.

⁴Department of Japanese-Oriental (Kampo) Medicine, Chiba Central Medical Center, Chiba City, Japan.

TABLE 1. CHANGES IN SYMPTOMS BY *SOKEIKAKKETSUTO*

	Before treatment	After treatment
	NRS	NRS
Dull pain	3-6	0-1
Stabbing pain	8-10	0
Dysesthesia	7-10	4
Choreoathetosis	Intermittent	Disappeared

NRS, numerical rating scale.

She complained of dysesthesia in the right side of her face, upper and lower limbs, and trunk. She also complained of moderate continuous dull pain and paroxysmal severe stabbing pain in the right upper and lower limbs. The dysesthesia and pain were especially severe on days of low atmospheric pressure, but there was no other specific factor that could be linked to aggravation of these symptoms. The intensity of pain was described by the numerical rating scale (NRS) based on the patient's subjective rating of her pain using any whole number from 0 (no pain) to 10 (worst possible pain). The intensity of dysesthesia was similarly rated by NRS using any whole number from 0 (no dysesthesia) to 10 (worst possible dysesthesia) (Table 1).

Neurologic examination performed by an experienced neurologist showed disturbance of superficial and deep sensation, ataxia in the right upper and lower limbs, dysesthesia in the right side of her face, upper and lower limbs, and trunk, gait disturbance, and intermittent choreoathetosis in the right upper limb. Allodynia and hyperalgesia were not observed. Magnetic resonance imaging of the brain demon-

strated an old infarction in the left thalamus and some ischemic lesions in the left putamen (Fig. 1). Her painful symptom was considered to be thalamic pain. In addition, these symptoms were diagnosed as Déjerine-Roussy syndrome.^{1,2}

A Kampo medical examination of the abdomen, which is regularly performed on patients in the supine position with their legs extended, showed moderate tenderness in the right side of the lower abdomen. A dark red tongue was also observed. Based on these signs, the patient was diagnosed as having *oketsu* (Blood Stasis) by Kampo diagnostic criteria.⁴ The sensory disturbance and her worsening condition on days of low atmospheric pressure were considered to be signs of Blood Deficiency and Stasis of body fluids, respectively.

Sokeikakketsuto, one of the Kampo medicines, was chosen for the treatment of this patient. *Sokeikakketsuto* is a decoction consisting of 17 herbs (Table 2), all of which have been approved for clinical use by the Japanese Ministry of Health, Labor and Welfare, and all of which are covered by national health insurance. The herbs were mixed in 600 mL of water and boiled for 40 minutes, and the mixture was passed through a sieve. The resulting extract, called the decoction, amounted to about 300 mL and was divided into three equal doses that were orally administered 2 hours after every meal. The decoction was prepared every day by experienced pharmacists in our hospital.

A few days after initiating Kampo treatment, her pain began to lessen, gradually decreasing day by day. Ten (10) days later, the pain in her limbs had almost disappeared, and the dysesthesia had also decreased. Etizolam was no longer required. In addition, her choreoathetosis had disappeared as well (Table 1). Although dysesthesia remained, her activities improved considerably and she was discharged from our hospital.

Discussion

Kampo medicines are often successful in ameliorating pain. *Sokeikakketsuto* is one of these, and it has been successfully used to treat joint pain, neuralgia, lumbago, muscle pain, and similar types of pain. To our knowledge, however, there is only one published report of its efficacious application for thalamic pain.⁵ Likewise in the present case, this prescription clearly succeeded in reducing pain. *Sokeikakketsuto* has also been used for poststroke sensory disturbance, and it was effective for improving dysesthesia to some extent in the present case.

Choreoathetosis, consisting of involuntary movements and a symptom of Déjerine-Roussy syndrome, was also observed in this case. Dopamine-receptor blocking drugs have been the main drugs to treat this kind of hyperkinetic disorder, but there are problems of side-effects such as Parkinsonism and dyskinesia.⁶ Although the choreoathetosis in our case was not severe, our patient was confused by this symptom. After *Sokeikakketsuto* had been administered, her choreoathetosis disappeared. To our knowledge, there is no previous report that *Sokeikakketsuto* was effective against choreoathetosis or other involuntary movements.

Sokeikakketsuto inhibits aldose reductase, and therefore this prescription has been used to treat peripheral neuropathy

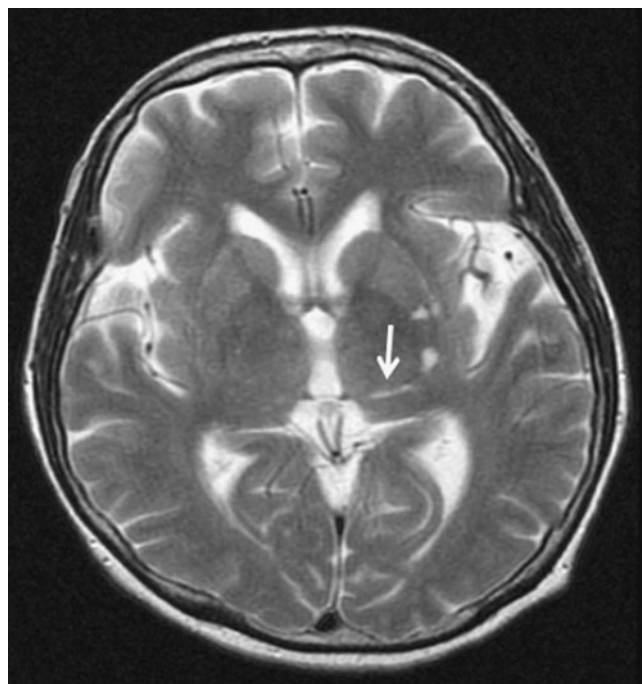


FIG. 1. T2-weighted brain magnetic resonance image of the patient shows an old infarction in the left thalamus (arrow) and some ischemic lesions in the left putamen.

TABLE 2. COMPOSITION OF *SOKEIKAKKETSUTO*

Herb	Botanical authority	Family name	Common name	Dose (g/day)
<i>Paeoniae radix</i>	<i>Paeonia lactiflora</i> Pallas	<i>Paeoniaceae</i>	Peony	2.5
<i>Angelicae radix</i>	<i>Angelica acutiloba</i> Kitagawa or <i>Angelica acutiloba</i> Kitagawa var. <i>sugiyamae</i> Hikino	<i>Umbelliferae</i>	Japanese angelica	2.0
<i>Rehmaniae radix</i>	<i>Rehmannia glutinosa</i> Liboschitz var. <i>purpurea</i> Makino or <i>Rehmannia glutinosa</i> Liboschitz	<i>Scrophulariaceae</i>	Chinese foxglove	2.0
<i>Atractylodis lanceae rhizoma</i>	<i>Atractylodes lancea</i> De Candolle or <i>Atractylodes chinensis</i> Koidzum	<i>Compositae</i>	<i>Atractylodes</i>	2.0
<i>Cnidii rhizoma</i>	<i>Cnidium officinale</i> Makino	<i>Umbelliferae</i>	Cnidium	2.0
<i>Persicae semen</i>	<i>Prunus persica</i> Batsch or <i>Prunus persica</i> Batsch var. <i>daurica</i> Maximowicz	<i>Rosaceae</i>	Peach	2.0
<i>Poria</i>	<i>Poria cocos</i> Wolf	<i>Polyporaceae</i>	Tuckahoe mushroom	2.0
<i>Achyranthis radix</i>	<i>Achyranthes fauriei</i> Leveillé et Vaniot or <i>Achyranthes bidentata</i> Blume	<i>Amaranthaceae</i>	<i>Achyranthis</i>	1.5
<i>Clematidis radix</i>	<i>Clematis chinensis</i> Osbeck, <i>Clematis mandshurica</i> Ruprecht or <i>Clematis hexapetala</i> Pallas	<i>Ranunculaceae</i>	Clematis	1.5
<i>Sinomeni caulis et rhizoma</i>	<i>Sinomenium acutum</i> Rehder et Wilson	<i>Menispermaceae</i>	Orient vine	1.5
<i>Notopterygii rhizoma</i>	<i>Notopterygium incisum</i> Ting ex H.T. Chang or <i>Notopterygium forbesii</i> Boissieu	<i>Umbelliferae</i>	Notopterygium	1.5
<i>Saposhnikoviae radix</i>	<i>Saposhnikovia divaricata</i> Schischkin	<i>Umbelliferae</i>	Saposhnikovia	1.5
<i>Gentianae scabrae radix</i>	<i>Gentiana scabra</i> Bunge, <i>Gentianamanshurica</i> Kitagawa or <i>Gentiana triflora</i> Pallas	<i>Gentianaceae</i>	Chinese gentian	1.5
<i>Aurantii nobilis pericarpium</i>	<i>Citrus unshiu</i> Markovich or <i>Citrus reticulata</i> Blanco	<i>Rutaceae</i>	Mikan orange	1.5
<i>Angelicae dahuricae radix</i>	<i>Angelica dahurica</i> Benthham et Hooker	<i>Umbelliferae</i>	Angelica	1.0
<i>Glycyrrhizae radix</i>	<i>Glycyrrhiza uralensis</i> Fischer or <i>Glycyrrhizaglabra</i> Linné	<i>Leguminosae</i>	Chinese licorice	1.0
<i>Zingiberis rhizoma</i>	<i>Zingiber officinale</i> Roscoe	<i>Zingiberaceae</i>	Ginger	1.0

Paeoniae radix, *Rehmaniae radix*, *Atractylodis lanceae rhizoma*, *Poria*, *Achyranthis radix*, *Sinomeni caulis et rhizoma*, and *Notopterygii rhizoma* were purchased from Tochimoto Tenkaido Co. Ltd, Osaka, Japan. *Cnidii rhizoma* and *Persicae semen* were purchased from Tsumura & Co., Tokyo, Japan. The other herbs were purchased from Uchida Wakanyaku Ltd, Tokyo, Japan.

due to diabetes.⁷ In the present case, however, it is difficult to explain why the pain disappeared following administration of this medicine, because the painful symptom was thought to occur because of a disorder of the central nervous system. It is also unclear why the patient's choreoathetosis disappeared.

In Kampo medicine, the usual practice is that one prescription is used to target a certain condition and a complex of symptoms, and it can have effects on various symptoms.² *Sokeikakketsuto* has been used to target the condition of *oketsu* (Blood Stasis), Blood Deficiency, exogenous Cold and moisture, and Stasis of body fluids. Our patient was thought to be in the condition of *oketsu* (blood stasis), Blood Deficiency, and Stasis of body fluids, compatible with a condition that *Sokeikakketsuto* would target. Therefore, it is believed that this prescription successfully treated the patient's poststroke pain. Although involuntary movement is not generally a symptom for which *Sokeikakketsuto* would be administered, the apparent effect of *Sokeikakketsuto* on choreoathetosis in this case might indicate the pleiotropic effects of Kampo medicines. Although further studies are needed to add efficacious treatments for thalamic pain, the present and previous cases⁵ suggest that *Sokeikakketsuto* could be a choice of treatment for thalamic pain under certain conditions.

Conclusions

This report presented a case of thalamic pain successfully treated with Kampo medicine. There are patients whose poststroke painful symptoms are not reduced with drugs such as antidepressants and antiepileptic drugs. In such cases, *Sokeikakketsuto* may be useful under certain conditions.

Disclosure Statement

No competing financial interests exist.

References

1. Déjerine J, Roussy G. The thalamic syndrome [in French]. *Rev Neurol (Paris)* 1906;14:521–532.
2. Wilkins RH, Brody IA. The thalamic syndrome. *Arch Neurol* 1969;20:559–562.
3. Klit H, Finnerup NB, Jensen TS. Central post-stroke pain: Clinical characteristics, pathophysiology, and management. *Lancet Neurol* 2009;8:857–868.
4. Terasawa K. *Kampo Japanese-Oriental Medicines: Insights from Clinical Cases*. 1st ed. Tokyo: K.K. Standard McIntyre, 1993;5, 37–61, 178–182.

5. Goto H, Fujimoto M, Watanabe T, et al. Trial of the treatment of Kampo medicines for thalamic pain. *Kampo Med* 2010;61: 189–197.
6. Jankovic J. Treatment of hyperkinetic movement disorders. *Lancet Neurol* 2009;8:844–856.
7. Aida K, Shindo H, Tawara M, et al. Inhibition of aldose reductase activities by Kampo medicines. *Planta Med* 1990;53: 131–135.

Address correspondence to:

Keigo Ueda, MD, PhD

Department of Japanese-Oriental (Kampo) Medicine

Chiba University Hospital

1-8-1 Inohana, Chuo-ku

Chiba City, Chiba, 260-8670

Japan

E-mail: kueda@hospital.chiba-u.jp