

Selective Propofol Injection into the M1 Segment of the Middle Cerebral Artery (MCA Wada Test) Reduces Adverse Effects and Enhances the Reliability of the Wada Test for Determining Speech Dominance

Masazumi Fujii, Shigeru Miyachi, Noriaki Matsubara, Takeshi Kinkori, Shigenori Takebayashi, Takashi Izumi, Tomotaka Ohshima, Arihito Tsurumi, Osamu Hososhima, Toshihiko Wakabayashi, Jun Yoshida

Key words

- Internal carotid artery
- MCA Wada test
- Middle cerebral artery
- Propofol
- Speech dominance
- Wada test

Abbreviations and Acronyms

- ACA:** Anterior cerebral artery
fMRI: Functional magnetic resonance imaging
ICA: Internal carotid artery
MCA: Middle cerebral artery
MEG: Magnetoencephalography
MRI: Magnetic resonance imaging
PCA: Posterior cerebral artery
PcomA: Posterior communicating artery



From the Department of Neurosurgery, Nagoya University Graduate School of Medicine, Nagoya, Japan

To whom correspondence should be addressed: Shigeru Miyachi, M.D. [E-mail: smiyachi@med.nagoya-u.ac.jp]

Citation: *World Neurosurg.* (2011) 75, 3/4:503-508.

DOI: 10.1016/j.wneu.2010.10.048

Journal homepage: www.WORLDNEUROSURGERY.org

Available online: www.sciencedirect.com

1878-8750/\$ - see front matter Published by Elsevier Inc.

INTRODUCTION

Although several noninvasive modalities are available for the evaluation of speech function, such as functional magnetic resonance imaging (fMRI), magnetoencephalography, and near-infrared spectroscopic topography, the Wada test is used for determining speech dominance before surgery for brain tumors because it is the most reliable method (1, 3, 8, 10). Before the surgical resection of tumors or other lesions that are located near the speech center, it is crucial to identify the dominant hemisphere definitely and choose an appropriate surgical strategy, such as awake craniotomy or usual craniotomy under general anesthesia. Information of language examinations when a certain area of the cortex is suppressed is more reliable than those when activated. Of the aforementioned preoperative examinations, only the Wada test involves temporary suppression of brain function and

■ **OBJECT:** The Wada test is had been the most reliable for determining speech dominance. Drugs injected into the internal carotid artery, however, may be heterogeneously distributed as the result of asymmetry of the anterior cerebral arteries and the presence of a fetal-type posterior cerebral artery. Variations in drug distribution could occasionally alter consciousness and complicate the evaluation of the test results. We examined selective propofol injection into the M1 segment of the middle cerebral artery (MCA Wada test).

■ **METHODS:** For the MCA Wada test (17 patients), 7 or 8 mg of propofol was injected via a microcatheter navigated into the M1 segment, and language function was evaluated by patient performing several tasks. The conventional Wada test (internal carotid artery [ICA] Wada test) was performed in four patients (both the ICA and MCA Wada tests were performed in one patient). The efficacy and adverse effects of both procedures were evaluated; all tests were performed by well-trained interventional neuroradiologists.

■ **RESULTS:** Immediately after propofol injection during the MCA Wada test, patients developed transient contralateral hemiplegia and transient aphasia (in the case of injection on the dominant side). Confusion and other severe adverse effects did not occur during the MCA Wada test, but two of four patients who underwent the ICA Wada test showed altered consciousness that affected the performance of the test.

■ **CONCLUSIONS:** The MCA Wada test is a feasible and reliable preoperative evaluation, if performed by a trained team of interventional neuroradiologists.

the injection of anesthetics into the carotid artery for the evaluation of speech dominance (1, 3).

Propofol is frequently used to perform the Wada test because, nowadays, amobarbital is not available in many countries (5, 7). However, the injection of propofol into the internal carotid artery (ICA) has been reported to induce disturbance of consciousness, which obscures the results of the Wada test. Takayama et al. (7) and Mikuni et al. (5) reported that adverse effects occurred during the performance of the Wada test in approximately one-third of patients. Drug distribution after injection into the ICA probably varies from patient to patient, depending on the topography of the cerebral arteries, which in turn mainly depends on the structure of the circle of Willis. The drug may be delivered to the brainstem via the branches of a fetal-type pos-

terior cerebral artery (PCA) or to both medial frontal lobes via the anterior communicating artery. To minimize such variations in drug distributions, reduce the frequency and severity of adverse effects, and improve the reliability of the test, we propose that super-selective injection of propofol into the M1 portion of middle cerebral artery (MCA) be used to determine speech dominance in patients with brain tumors.

METHODS

Subjects

During the course of 3 years (from March 2006), 20 brain tumor patients underwent Wada tests for the preoperative evaluation of language dominance. All the patients had intrinsic tumors within or around one of the

Table 1. Clinical Characteristics of 20 Patients Who Underwent ICA and MCA Wada Tests and Adverse Effects During the Procedure

Patient Number	Age, Years	Handedness	Pathological Diagnosis	Tumor Location	Type of Wada Test	Right Side					Left Side					Dominant Hemisphere
						Injection Amount of Propofol	Disturbance of Consciousness	Other Adverse Effect	Topography: PCA and PcomA	Topography: ACA	Injection Amount of Propofol	Disturbance of Consciousness	Other Adverse Effect	Topography: PCA and PcomA	Topography: ACA	
1	62	R	Astrocytoma	Left insular cortex and basal ganglia	ICA	4	Mild	Eye diversion to right, left-sided hemianopsia, spatial agnosia	Fetal type PCA	Uni. ACA	5	Mild	Involuntary movement of right upper limb and left face	No PcomA	Uni. ACA	L
2	31	R	Anaplastic oligoastrocytoma	Left temporal lobe	ICA	10	None	None	Fetal type PCA	N/A	10	None	Continuation of oral counting	N/A	N/A	R
3	26	R	Cavernous hemangioma	Left frontal lobe	ICA	10	Coma for 5 min	None	No PcomA	Uni. ACA	10	Coma for 5 min	None	No PcomA	Bil. ACA, transient	L
4	57	R	Anaplastic oligodendroglioma	Left temporal lobe	ICA	10	Coma	N/A	Fetal type PCA	Uni. ACA	N/A	N/A	N/A	Fetal type PCA	Uni. ACA	L
					MCA	8	None	Involuntary movement of left hand, continuation of oral counting	No PcomA	Bil. ACA, transient	5	None	None	Transient visualization	Bil. ACA, transient	L
5	59	R	Anaplastic oligoastrocytoma	Left frontal lobe	MCA	8	Apathy	None	No PcomA	Uni. ACA	8	None	None	No PcomA	Uni. ACA	R
6	73	R	Astrocytoma (gemistocytic)	Left frontal lobe	MCA	7	None	None	No PcomA	Bil. ACA, dominant	7	None	Involuntary movement of right upper limb (flexion)	No PcomA	Absent ACA	L
7	40	R	Oligodendroglioma	Left frontal lobe	MCA	7	None	None	No PcomA	Bil. ACA, transient	7	None	None	No PcomA	Uni. ACA	L
8	40	R	Astrocytoma	Left frontal lobe	MCA	7	None	None	Fetal type PCA	Uni. ACA	7	None	Involuntary movement of left hand (perseveration)	No PcomA	Bil. ACA, transient	L
9	56	R	Anaplastic oligodendroglioma	Left frontal lobe	MCA	8	None	None	Fetal type PCA	Uni. ACA	8	None	None	Transient visualization	Bil. ACA, transient	L
10	36	R	Glioblastoma	Left frontal lobe	MCA	8	Mild	Involuntary movement of left upper limb	Fetal type PCA	Bil. ACA, transient	8	None	Involuntary movement of right upper limb (flexion)	Transient visualization	Bil. ACA, transient	L
11	50	L	Oligodendroglioma	Right temporal lobe	MCA	10	None	None	Transient visualization	Bil. ACA, transient	8	None	None	Transient visualization	Bil. ACA, transient	R
12	35	R	Anaplastic astrocytoma	Left frontal lobe	MCA	8	None	None	Fetal type PCA	Uni. ACA	8	None	None	Fetal type PCA	Bil. ACA, transient	L
13	75	R	Glioblastoma	Left frontal lobe	MCA	7	None	None	Fetal type PCA	Absent ACA	7	None	None	Fetal type PCA	Bil. ACA, dominant	L
14	37	R	Glioblastoma	Left temporal lobe	MCA	9	Mild	Involuntary movement of left hand, continuation of oral counting	Transient visualization	Bil. ACA, transient	7	None	Involuntary movement of left lower limb (flexion)	Fetal type PCA	Bil. ACA, transient	L

Continues

Table 1. Continued

Patient Number	Age, Years	Handedness	Pathological Diagnosis	Tumor Location	Type of Wada Test	Right Side						Left Side					
						Injection Amount of Propofol	Disturbance of Consciousness	Other Adverse Effect	Topography: PCA and PcomA	Topography: ACA	Injection Amount of Propofol	Disturbance of Consciousness	Other Adverse Effect	Topography: PCA and PcomA	Topography: ACA	Dominant Hemisphere	
15	42	R	Astrocytoma Grade2	Left frontal lobe	MCA	7	None	None	Fetal type PCA	Bil. ACA, transient	7	None	None	No PcomA	Bil. ACA, transient	L	
16	55	L	Anaplastic oligodendroglioma	Right temporal lobe and insular cortex	MCA	8	None	None	Fetal type PCA	Bil. ACA, transient	8	Mild	None	Transient visualization	Uni. ACA	L	
17	61	R	Glioblastoma	Left temporal lobe	MCA	8	Mild	Continuation of oral counting	No PcomA	Bil. ACA, transient	7	None	Involuntary movement of left lower limb (flexion)	No PcomA	Uni. ACA	L	
18	45	L	Low-grade glioma	Right frontal lobe	MCA	7	None	None	No PcomA	Bil. ACA, transient	7	None	None	Transient visualization	Bil. ACA, transient	L	
19	56	L	Anaplastic oligodendroglioma	Left frontal lobe	MCA	8	Mild	Involuntary movement of left arm (flexion)	No PcomA	Bil. ACA, transient	8	Mild	None	Transient visualization	Bil. ACA, transient	R	
20	36	R	Anaplastic astrocytoma	Left frontal lobe	MCA	8	None	Involuntary movement of left hand, flexion of arm	Transient visualization	Uni. ACA	8	None	None	Transient visualization	Bil. ACA, dominant	L	

In patient 4, the ICA Wada test was performed on the right hemisphere and the MCA Wada test on both hemispheres.

PCA, posterior cerebral artery; ACA, anterior cerebral artery; R, right; ICA, internal carotid artery; N/A, not available; L, left; unil., unilateral; bil., bilateral; MCA, middle cerebral artery; PcomA, posterior communicating artery.

speech centers on anatomical images and still maintained good speech function. Informed consent was obtained before the test from all patients according to the clinical research protocol approved by the institutional review board of Nagoya University Hospital. The Wada test with propofol injection into the ICA (ICA Wada test) was performed in four patients (seven procedures), and the Wada test with super-selective injection of propofol into the MCA (MCA Wada test) was performed in 17 patients (34 procedures). The effectiveness of the test (determination of speech dominance), adverse effects during the procedure, and complications after the procedure were evaluated. One patient underwent both ICA and MCA Wada tests because the injection of propofol into the right ICA induced disturbance of consciousness and no language tasks could be performed.

Angiographic Findings of the Circle of Willis

Cerebral angiography was performed in all patients at the same time, and 6 mL of contrast medium (Iopamiron 300; Bayer Schering Pharma, Osaka, Japan) was injected into the ICA at the rate of 4 mL/s. The posterior communicating artery (PcomA) and PCA were visualized and grouped on the cerebral angiogram as follows: both PcomA and PCA not visualized, group P1; PcomA and PCA transiently visualized, group P2; and fetal-type PCA, group P3. Findings of anterior cerebral artery (ACA) were also grouped as follows: ACA not visualized, group A1, ACA visualized unilaterally: group A2, both ACAs visualized transiently: group A3, and both ACAs clearly visualized; group A4.

ICA Wada Test Procedure

The Wada test was performed on both hemispheres for each patient, first on the suspected nondominant side and then on the suspected dominant side. The ICA Wada test was performed as described by Takayama et al. (7). In brief, a 4-Fr. catheter (Selecon PA; Cinical Supply Co. Ltd., Gifu, Japan) was inserted into the ICA via the transfemoral route. To test for retrograde amnesia, patients were instructed to memorize a word and a card. They started counting aloud from the number one while opening and closing the hand on the side contralateral to the injected artery. When they had counted to seven, 10 mg of

propofol in 10 mL of saline solution was manually injected at the rate of 1 mL/s. If 10 mg of propofol did not produce paresis of the contralateral extremities, up to 3 mg of propofol was administered as a bolus. The patients performed language tasks, including picture naming, reading, repetition, comprehension of spoken commands, calculation, and orientation. Language function was evaluated at 3 minutes after the initiation of propofol injection. Memory-retention tests were initiated after language function returned to normal, usually 5–10 min after the injection of propofol. After the completion of all tasks, another angiogram was obtained to assess catheter position and adverse vascular events such as occlusion and spasm of the cerebral arteries.

MCA Wada Test Procedure

In the MCA Wada test, a 4- or 5-Fr. guiding catheter was introduced into the ICA via the femoral approach, and then a 0.021-inch internal diameter microcatheter (eg, Rapid Transit; Cordis Neurovascular Inc., Miami Lakes, FL) was navigated into the M1 segment of the MCA with a microwire guiding. After the injection of the contrast medium through the microcatheter, both the frontal and temporal branches of the MCA were clearly visualized on the angiogram with minimal influence of laminar blood flow. The microcatheter was carefully placed so that it was not wedged into a perforator. These microcatheterization was performed by well-trained interventional neuroradiologists. Women were administered 7 mg of propofol and men 8 mg of propofol. Additional propofol (up to 3 mg) was administered when contralateral hemiplegia was not observed at these doses. The rest of the procedure of the MCA Wada test was identical to that of the ICA Wada test. Assessment of catheter position and adverse vascular events were also performed before the withdrawal of the microcatheter.

RESULTS

Table 1 displayed the summary of clinical characteristics of 20 patients who underwent ICA and MCA Wada tests and adverse effects during the procedure. Both ICA and MCA Wada tests were performed in one patient.

ICA Wada Test

All four patients demonstrated contralateral hemiplegia after the injection of up to 10 mg

of propofol (total dose). Three patients showed moderately or severely altered consciousness; those symptoms were all transient and there was no remaining adverse effect. The right hemisphere could not be evaluated at all in one patient (who is presented in the section “Illustrative Case”). Another patient fell into a coma, and several minutes elapsed between the injection of propofol and the initiation of the tasks, shortening the time window for the tasks and complicating the interpretation of the results obtained. One patient demonstrated mild tendency to sleep, as well as head and eye version, which occurred together. This patient had to be kept awake by some stimulation during the task; nevertheless, the test results were sufficiently clear to identify the dominant hemisphere.

MCA Wada Test

All 17 patients developed contralateral hemiplegia immediately after the injection of propofol into the M1 segment. Additional propofol was administered during 2 of the 34 procedures (2 mg of propofol in each) to produce complete hemiplegia. All patients also showed aphasia or dysphasia affecting at least one side. Apathy or mild alteration of consciousness was observed in six patients (seven procedures). These symptoms, however, were very mild and did not hinder the determination of speech dominance. No patients experienced severe adverse effects such as increased muscle tone with twitching and rhythmic movements or tonic posture. Mild and transient involuntary movements of the contralateral extremities, however, were frequently observed. Further, seven patients (nine procedures) showed flexion of the contralateral extremities, preservation of the opening and closing movements of the hands, etc., for a few minutes after injection of propofol. Hemiparesis fully recovered within 4 minutes and speech function within 10 minutes. No permanent complications were observed after the Wada test in this series.

Angiographical Findings of the Circle of Willis

The summary of angiographic findings of the circle of Willis with injection of the contrast medium into the ICA also is displayed in **Table 1**. Of 40 hemispheres, transient visualization of the PCA (group P2) was noted in

11 (27.5%), and fetal-type PCA (group P3) in 14 (35%). Both ACAs were transiently visualized (group A3) and continuously visualized (group A4) in 21 (52.5%) and 3 (7.5%) hemispheres, respectively.

ILLUSTRATIVE CASE

A 57-year-old right-handed man presented with generalized convulsive seizures. An MRI study revealed a left temporal tumor extending into the left parietal lobe with intratumoral hemorrhage (**Figure 1A, 1B**). Clinical signs and symptoms and an fMRI study indicated that the dominant hemisphere for language function was the left hemisphere. To confirm this, the Wada test was performed preoperatively. First, the ICA Wada test was performed on the right hemisphere as described previously. Immediately after injection of 10 mg of propofol, the patient became unconscious and did not respond to any verbal questions and orders, and therefore, none of the tasks could be undertaken. Cerebral angiography revealed that both PCAs were of the fetal type: group P3 (**Figure 1C**). Both ACAs were independent: group A2 (**Figure 1D**). Therefore, super-selective injection of propofol into the right MCA was performed to avoid distribution of the anesthetic to the ACAs and the right PCA, which usually supplies the brainstem. Injection of anesthetic into these arteries may be partially responsible for the subsequent alteration of consciousness. The injection of 8 mg of propofol into the M1 segment of the right MCA did not induce disturbance of consciousness. The patient was able to correctly reply to questions and obey verbal commands. The same dose of propofol was injected into the M1 segment of the left MCA, and clear symptoms of aphasia without alteration of consciousness were observed. These findings strongly suggested the left hemisphere was the dominant hemisphere for language function.

DISCUSSION

The accuracy and quality of the surgical resection of brain tumors, especially gliomas, has remarkably improved since the introduction of image-guided surgery and awake craniotomy. With the use of sophisticated image-guided surgery, total resection or near total resection of gliomas is being increasingly reported along with im-

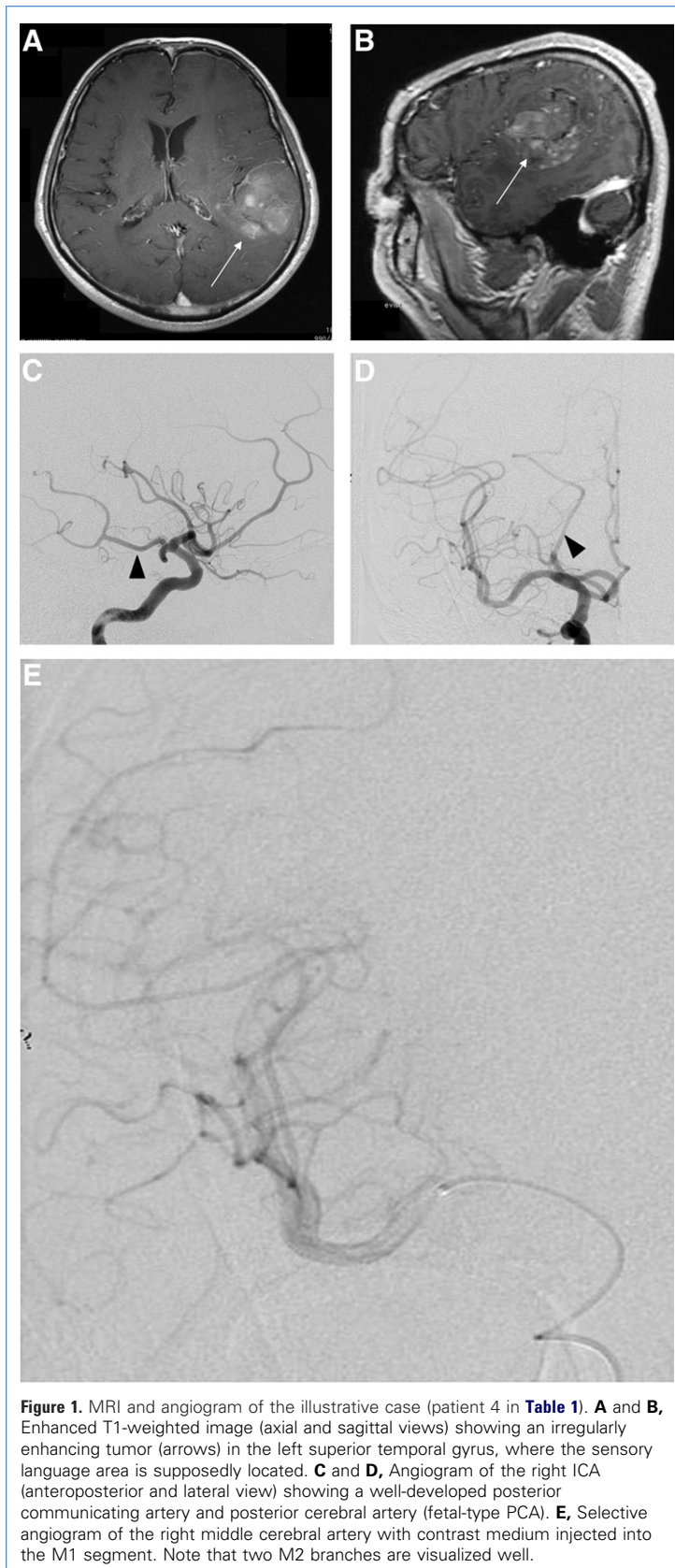


Figure 1. MRI and angiogram of the illustrative case (patient 4 in [Table 1](#)). **A** and **B**, Enhanced T1-weighted image (axial and sagittal views) showing an irregularly enhancing tumor (arrows) in the left superior temporal gyrus, where the sensory language area is supposedly located. **C** and **D**, Angiogram of the right ICA (anteroposterior and lateral view) showing a well-developed posterior communicating artery and posterior cerebral artery (fetal-type PCA). **E**, Selective angiogram of the right middle cerebral artery with contrast medium injected into the M1 segment. Note that two M2 branches are visualized well.

provement in patient survival (2). However, the more extensive the resection, the greater is the risk of postoperative neurological deficit, especially in the case of tumors located near eloquent areas such as the speech centers. Awake craniotomy is one of the accepted strategies for resecting tumors located near the speech centers while avoiding postoperative aphasia (6). During awake craniotomy, language mapping is performed by the use of direct electrical stimulation of the cortex to localize important speech areas. The success of awake craniotomy depends on the preoperative determination of speech dominance and the acquisition of information about language function when the area in and around the lesion is suppressed. The resection of an activated cortical area identified on fMRI and magnetoencephalography with language tasks does not necessarily translate into postoperative neurological deficit. Conversely, the resection of inactive cortical areas does not guarantee freedom from neurological complications. The Wada test evaluates language function when the cortex is suppressed, and therefore, this test is still the most reliable and important examination for the preoperative evaluation of speech dominance in patients with lesions that are located around the speech centers (1, 3).

Because amobarbital is not available in many countries, propofol frequently is used during the Wada test. However, the Wada test with propofol injection is associated with relatively frequent adverse effects, including altered consciousness (5, 7). These adverse effects have an apparently negative influence on the reliability of the Wada test. In our small series of patients who underwent ICA Wada tests, disturbance of consciousness was observed in three of four patients, and the disturbance was severe in two patients. Mikuni et al. (5) reported the adverse effects of propofol injection into the ICA during the Wada test. They found moderate and severe side effects in 13 of 58 (25%) patients (5). The side effects included altered consciousness or confusion (six patients) and increased muscle tone with twitching and rhythmic movements or tonic posture (seven patients). The frequency and severity of intraprocedural disturbance of consciousness were apparently lower during the MCA Wada tests than during the ICA Wada tests in our study and in the Wada tests in the abovementioned study. In our study, no severe adverse effects

occurred during the 34 procedures, including 17 MCA Wada tests. In six (37%) patients, apathy or mild disturbance of consciousness occurred. These side effects corresponded to the grade 1 symptoms reported by Mikuni et al. (5) and were not severe enough to hinder the performance of the tasks. The MCA Wada test was not associated with symptoms caused by peripheral vessel anastomosis, such as lacrimation, eye pain, and face contortion.

Drug distribution after injection into the ICA varies from patient to patient, depending on the topography of the cerebral arteries, which mainly depends on the structure of the circle of Willis. The drug may be delivered to the brainstem via the branches of a fetal-type PCA or to the medial frontal lobes via the ACA. In our study, transient visualization of the PCA or fetal-type PCA was noted in 25 hemispheres (group P2 and P3: 62.5%). In these patients with visualization of PCAs, it is possible that anesthetics injected into the ICA will be delivered to the brainstem. Bilateral visualization of the ACA was noted in 24 hemispheres (group A3 and A4: 60%) and may influence consciousness and mood. Distribution of the anesthetics into the contralateral frontal lobe must be avoided while determining the dominant language hemisphere. The MCA Wada test is highly advantageous because it minimizes the variations in drug distributions, is associated with few intraoperative adverse effects, and is accurate for determining speech dominance. Hajek et al. (4) performed selective amobarbital tests for the determination of language function in five epileptic patients. They found that selective injection of the anesthetic into the cerebral arteries was efficacious for determining language function of the corresponding brain area. Urbach et al. (9) also reported the role of the MCA Wada test with amobarbital injection for the preoperative evaluation of epilepsy patients. They concluded that the MCA Wada test can be used to preoperatively assess the risk of motor deficit after functional hemispherectomy. However, they also reported that the spatial resolution of the MCA Wada test was inadequate even when the microcatheter was inserted into the peripheral branches of the MCA. Therefore, they recommended that subdural grid electrodes be used to evaluate the distribution of the cortical language area.

Regarding the technical aspects of superselective MCA injection, maneuvering of the microcatheter is mandatory. The catheter tip must be located in the proximal M1 segment, and all M2 branches should be visualized on the angiogram. We used 7 mg of propofol in female patients and 8 mg in male patients. Additional injection of anesthetics for the complete paralysis of the contralateral extremities was required in 2 of 34 procedures (additional dose, 2 mg each; one male and one female patient). The MCA Wada test requires lower doses of propofol than the ICA Wada test, in which 10–15 mg is used for brain tumor patients. Thus, the effect of the drug on whole brain is lower in the former test than in the latter. All patients demonstrated aphasia on injection of the anesthetic into at least one MCA. Paralysis of the extremities and aphasia were both transient, and the patients usually recovered within 4 and 10 minutes, respectively. Some patients started recovering from aphasia at 5 minutes. Therefore, we recommend that patients should be given language tasks within 5 minutes after the injection of the anesthetic.

The advantages of the MCA Wada test are as follows: decreased severity of side effects that influence the test results, more consistent determination of speech dominance, and requirement of low doses of anesthetics. Its disadvantage is that medial temporal lobe structures cannot be evaluated. Thus, this test cannot be used to evaluate memory dominance since the memory centers are usually in the territory of the PcomA and/or the PCA. A certain amount of skill is required to perform the MCA Wada test because it involves microcatheterization, and if the microcatheter manipulation is performed by surgeons who are not familiar with it, catheterization-related complications may occur. In our study, all procedures were performed by a team trained in intravascular treatment, and we have never encountered such complications. With dramatic technical and instrumental improvements, interventional neuroradiology has become the main therapy for many cerebral diseases. The MCA Wada test is a feasible and reliable preoperative evaluation, if performed by a trained team of interventional neuroradiologists.

ACKNOWLEDGMENTS

The authors thank Takehiro Naito, Kenichi Haraguchi, and Tsuyoshi Ichikawa, members

of “The Neuroendovascular Team” of Nagoya University Graduate School of Medicine, for their generous assistance in this study.

REFERENCES

1. Abou-Khalil B: An update on determination of language dominance in screening for epilepsy surgery: the Wada test and newer noninvasive alternatives. *Epilepsia* 48:442-455, 2007.
2. Claus EB, Hurlacher A, Hsu L, Schwartz RB, Dello-Iacono D, Talos F, Jolesz FA, Black PM: Survival rates in patients with low-grade glioma after intraoperative magnetic resonance image guidance. *Cancer* 103:1227-1233, 2005.
3. Grote CL, Meador K: Has amobarbital expired? Considering the future of the Wada. *Neurology* 65:1692-1693, 2005.
4. Hajek M, Valavanis A, Yonekawa Y, Schiess R, Buck A, Wieser HG: Selective amobarbital test for the determination of language function in patients with epilepsy with frontal and posterior temporal brain lesions. *Epilepsia* 39:389-398, 1998.
5. Mikuni N, Takayama M, Satow T, Yamada S, Hayashi N, Nishida N, Taki J, Enatsu R, Ikeda A, Miyamoto S, Hashimoto N: Evaluation of adverse effects in intracarotid propofol injection for Wada test. *Neurology* 65:1813-1816, 2005.
6. Picht T, Kombos T, Gramm HJ, Brock M, Suess O: Multimodal protocol for awake craniotomy in language cortex tumour surgery. *Acta Neurochir (Wien)* 148:127-137, 2006.
7. Takayama M, Miyamoto S, Ikeda A, Mikuni N, Takahashi JB, Usui K, Satow T, Yamamoto J, Matsuhashi M, Matsumoto R, Nagamine T, Shibasaki H, Hashimoto N: Intracarotid propofol test for speech and memory dominance in man. *Neurology* 63:510-515, 2004.
8. Trenerry MR, Loring DW: Intracarotid amobarbital procedure. The Wada test. *Neuroimaging Clin N Am* 5:721-728, 1995.
9. Urbach H, Von Oertzen J, Klemm E, Koenig R, Linke DB, Kurthen M, Schramm J, Elger CE: Selective middle cerebral artery Wada tests as a part of presurgical evaluation in patients with drug-resistant epilepsies. *Epilepsia* 43:1217-1223, 2002.
10. Wada J, Rasmussen T: Intracarotid injection of sodium amyltal for the lateralization of cerebral speech dominance. 1960. *J Neurosurg* 106:1117-1133, 2007.

Conflict of interest statement: The authors declare that the article content was composed in the absence of any commercial or financial relationships that could be construed as a potential conflict of interest.

received 22 February 2010; accepted 21 October 2010

Citation: *World Neurosurg.* (2011) 75, 3/4:503-508.

DOI: 10.1016/j.wneu.2010.10.048

Journal homepage: www.WORLDNEUROSURGERY.org

Available online: www.sciencedirect.com

1878-8750/\$ - see front matter Published by Elsevier Inc.