

Unusual Cisternal Coil Migration in the Follow-up Period After Aneurysm Perforation During Endovascular Coiling

—Case Report—

Toshinari MEGURO,¹ Tatsuya SASAKI,¹ Jun HARUMA,¹
Tomoyuki TANABE,¹ Kenichiro MURAOKA,¹ Kinya TERADA,¹
Nobuyuki HIROTSUNE,¹ and Shigeki NISHINO¹

¹Department of Neurological Surgery, Hiroshima City Hospital, Hiroshima

Abstract

A 61-year-old woman suffered cisternal coil migration in the follow-up period after endovascular coil embolization for a ruptured cerebral aneurysm. She presented with sudden onset of headache. Computed tomography demonstrated diffuse subarachnoid hemorrhage, and cerebral angiography disclosed a left anterior choroidal artery aneurysm. The aneurysm was treated by endovascular embolization with Guglielmi detachable coils. During the embolization procedure, the microcatheter perforated the aneurysm. For direct closure of the perforation site with coils, the microcatheter was withdrawn and coils were deployed partially in the subarachnoid space and partially in the aneurysm sac. The coil mass was spread in the subarachnoid space around the aneurysm immediately after embolization. The patient was discharged with no neurological deficit. Three months later, follow-up radiography demonstrated obvious reduction in the size and compaction of the coil mass. Magnetic resonance angiography and digital subtraction angiography demonstrated stable occlusion of the aneurysm. The coil mass probably spread in the cistern around the aneurysm and was compacted by the shape memory of the coils and pulsation of the brain and vessels, as the subarachnoid clots around the aneurysm had disappeared. This case suggests that cisternal coil migration should be considered in the follow up of intracranial aneurysm treated with detachable coils.

Key words: coil embolization, ruptured aneurysm, perforation, cisternal coil migration, detachable coil

Introduction

Endovascular occlusion with detachable coils has been proposed as an alternative to neurosurgical clipping for patients with both ruptured and unruptured intracranial aneurysms.^{7,8)} Generally, up to one-third of patients who undergo coil embolization have experienced aneurysm recanalization.^{1,8,9)} Coil compaction is one of the causes of recanalization of the aneurysm after coil embolization.^{4,6)} We report a case of coil compaction demonstrated by radiography after endovascular embolization with coils for ruptured cerebral aneurysm, associated with apparent cisternal coil migration but no recanalization of the aneurysm.

Case Report

A 61-year-old woman suffered sudden onset of severe headache. She was immediately admitted to our hospital with subarachnoid hemorrhage (SAH) in Hunt and Hess

grade I. Initial computed tomography (CT) showed Fisher group 2 SAH. On the same day as the bleeding, cerebral angiography demonstrated a $5.1 \times 4.3 \times 3.6$ mm aneurysm at the left internal carotid-anterior choroidal artery (Fig. 1). Following diagnostic digital subtracted angiography (DSA), endovascular treatment was administered under local anesthesia. After full heparinization, the aneurysm was selectively catheterized using an Excel-14 microcatheter with a two-tip marker and a Synchro guidewire (Boston Scientific, Fremont, California, USA). The first coil (GDC-10 360 soft, 4 mm \times 8 cm; Boston Scientific) was positioned and detached in the aneurysm. The patient complained of worsened headache and immediately showed elevated blood pressure after detachment of the first coil. Microcatheter perforation was confirmed based on extravasation of contrast medium in the DSA. The heparinization was immediately reversed. Parts of four filling coils (GDC10 US 3 mm \times 6 cm, 3 mm \times 6 cm, 2 mm \times 6 cm, 2 mm \times 2 cm) were positioned outside the aneurysm and the remainder delivered inside the aneurysm sac after withdrawing the microcatheter tip within the aneurysm. Angiography after embolization

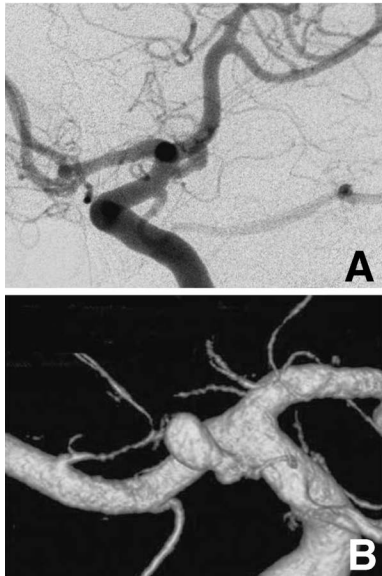


Fig. 1 Left carotid angiograms, anterior oblique view (A) and three-dimensional reconstruction (B), showing an aneurysm at the left internal carotid-anterior choroidal artery.

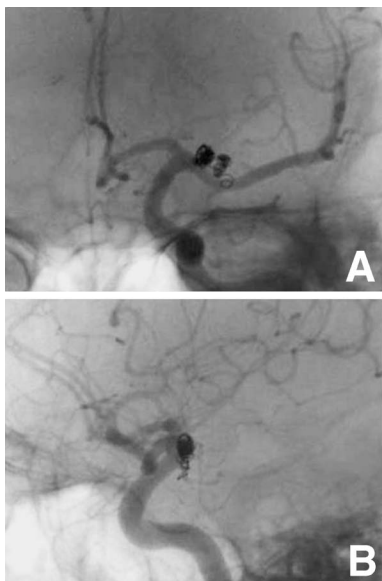


Fig. 2 Left carotid angiograms, frontal view (A) and lateral view (B), immediately after endovascular treatment showing complete obliteration of the aneurysm and no extravasation of the contrast medium, despite the irregular shape of the coil mass in the subarachnoid space.

showed complete obliteration of the aneurysm and no extravasation of contrast medium, despite the irregular shape of the coil mass in the subarachnoid space (Fig. 2). CT performed immediately after the procedure revealed extravasation of contrast material into the subarachnoid space and the patient's headache had worsened, but the patient was discharged from the hospital 3 weeks later

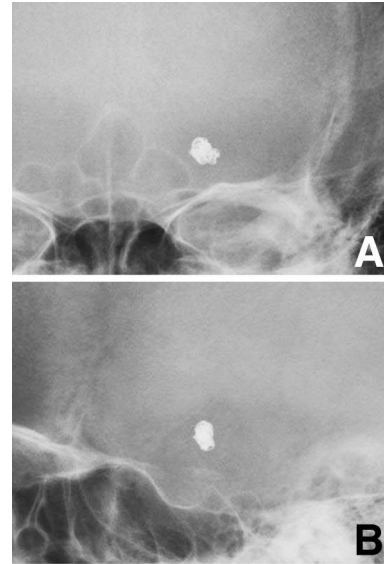


Fig. 3 Follow-up radiographs, frontal view (A) and lateral view (B), 3 months after endovascular treatment revealing obvious reduction in size and compaction of the coil mass.

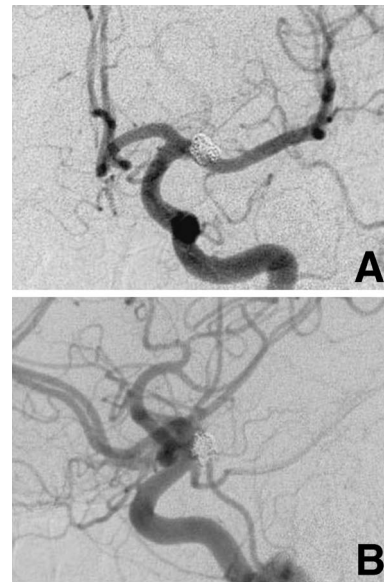


Fig. 4 Follow-up left carotid angiograms, frontal view (A) and lateral view (B), 10 months after endovascular treatment demonstrating stable occlusion and no recurrence of the aneurysm.

with no neurological deficit (the modified Rankin scale grade 0).

Three months later, follow-up radiography revealed obvious reduction in the size and compaction of the coil mass (Fig. 3), but magnetic resonance (MR) angiography did not show recanalization of the aneurysm. Ten months later, DSA demonstrated stable occlusion and no recurrence of the aneurysm (Fig. 4).

Discussion

Endovascular treatment with detachable coils is effective in preventing rebleeding after SAH caused by aneurysm rupture.^{7,8)} However, aneurysm remnants and recurrences are more likely after coil occlusion than after surgical clipping.^{1,8-10)} Therefore, long-term follow up of patients after coil occlusion is necessary. The standard follow-up imaging technique after coil embolization is DSA. However, this diagnostic procedure is invasive, so MR angiography has been used as an alternative noninvasive imaging technique to assess the effectiveness of coil embolization of intracranial aneurysms.³⁾ As a simple technique, radiography of the coil mass helps to predict the stability of angiographic occlusion^{2,3)} because recurrence of the coiled aneurysm usually occurs due to coil compaction. Changes in the shape of the coil mass might suggest aneurysm recanalization. In our hospital, radiography is performed every 3 months after treatment, and MR angiography is performed every 6 months. If radiography and MR angiography do not suggest recanalization of the aneurysm, DSA is performed after the 10th month.

Coil compaction usually occurs by arterial pressure through the neck of the aneurysm.^{5,6)} In the present case, the shape of the coil mass dramatically changed during the follow-up period, but no recanalization of the aneurysm occurred. During the endovascular treatment procedure, the microcatheter perforated the aneurysm, so coils were placed from outside the aneurysm into the aneurysm sac through the perforation site of the aneurysm to stop the bleeding. Thus, the coil mass had spread in the subarachnoid space around the aneurysm, and the outer part of the coil mass had subarachnoid clots between each of the coil loops just after endovascular treatment. We suggest that the coils around the aneurysm had been compacted by the shape memory of the coils and the pulsation of the brain and vessels, as the subarachnoid clots around the aneurysm had disappeared.

In conclusion, follow-up radiography of intracranial aneurysm treated with detachable coils should be performed, but cisternal coil migration might affect the shape of the coils in the subarachnoid space.

References

- 1) Cognard C, Weill A, Castaings L, Rey A, Moret J: Intracranial berry aneurysms: angiographic and clinical results after

- endovascular treatment. *Radiology* 206: 499-510, 1998
- 2) Connor SE, West RJ, Yates DA: The ability of plain radiography to predict intracranial aneurysm occlusion instability during follow-up of endosaccular treatment with Guglielmi detachable coils. *Neuroradiology* 43: 680-686, 2001
- 3) Cottier JP, Bleuzen-Couthon A, Gallas S, Vinikoff-Sonier CB, Bertrand P, Domengie F, Barantin L, Herbreteau D: Follow-up of intracranial aneurysms treated with detachable coils: comparison of plain radiographs, 3D time-of-flight MRA and digital subtraction angiography. *Neuroradiology* 45: 818-824, 2003
- 4) Hope JK, Byrne JV, Molyneux AJ: Factors influencing successful angiographic occlusion of aneurysms treated by coil embolization. *AJNR Am J Neuroradiol* 20: 391-399, 1999
- 5) Kai Y, Hamada J, Morioka M, Yano S, Kuratsu J: Evaluation of the stability of small ruptured aneurysms with a small neck after embolization with Guglielmi detachable coils: correlation between coil packing ratio and coil compaction. *Neurosurgery* 56: 785-792, 2005
- 6) Kawanabe Y, Sadato A, Taki W, Hashimoto N: Endovascular occlusion of intracranial aneurysms with Guglielmi detachable coils: correlation between coil packing density and coil compaction. *Acta Neurochir (Wien)* 143: 451-455, 2001
- 7) Molyneux AJ, Kerr RS, Yu LM, Clarke M, Sneade M, Yarnold JA, Sandercock P: International subarachnoid aneurysm trial (ISAT) of neurosurgical clipping versus endovascular coiling in 2143 patients with ruptured intracranial aneurysms: a randomised comparison of effects on survival, dependency, seizures, rebleeding, subgroups, and aneurysm occlusion. *Lancet* 366: 809-817, 2005
- 8) Murayama Y, Nien YL, Duckwiler G, Gobin YP, Jahan R, Frazee J, Martin N, Vinuela F: Guglielmi detachable coil embolization of cerebral aneurysms: 11 years' experience. *J Neurosurg* 98: 959-966, 2003
- 9) Raymond J, Guilbert F, Weill A, Georganos SA, Juravsky L, Lambert A, Lamoureux J, Chagnon M, Roy D: Long-term angiographic recurrences after selective endovascular treatment of aneurysms with detachable coils. *Stroke* 34: 1398-1403, 2003
- 10) Sluzewski M, Menovsky T, van Rooij WJ, Wijndal D: Coiling of very large or giant cerebral aneurysms: long-term clinical and serial angiographic results. *AJNR Am J Neuroradiol* 24: 257-262, 2003

Address reprint requests to: Toshinari Meguro, MD, Department of Neurological Surgery, Hiroshima City Hospital, 7-33 Moto-machi, Naka-ku, Hiroshima 730-8518, Japan.
e-mail: tmeguron@hotmail.com