

Balloon-assisted Onyx embolization of cerebral single-channel pial arteriovenous fistulas

Technical note

C. BENJAMIN NEWMAN, M.D.,¹ YIN C. HU, M.D.,² CAMERON G. MCDUGALL, M.D.,³
AND FELIPE C. ALBUQUERQUE, M.D.³

¹Division of Neurosurgery, University of California, San Diego, California; ²Department of Neurosurgery, Case Western Reserve University Medical Center, Cleveland, Ohio; and ³Division of Neurological Surgery, Barrow Neurological Institute, St. Joseph's Hospital and Medical Center, Phoenix, Arizona

Object. Pial arteriovenous fistulas (AVFs) of the brain are rare vascular malformations associated with significant risks of hemorrhage and neurological deficit. Depending on their location and high-flow dynamics, these lesions can present treatment challenges for both endovascular and open cerebrovascular surgeons. The authors describe a novel endovascular treatment strategy that was used successfully to treat 2 pediatric patients with a pial AVF, and they discuss the technical nuances specific to their treatment strategy.

Methods. A single-channel high-flow pial AVF was diagnosed in 2 male patients (6 and 17 years of age). Both patients were treated with endovascular flow arrest using a highly conformable balloon followed by Onyx infusion for definitive closure of the fistula.

Results. Neither patient suffered a complication as a result of the procedure. At the 6-month follow-up in both cases, the simple discontinuation of blood flow had resulted in durable obliteration of the fistula and stable or improved neurological function.

Conclusions. Onyx can be delivered successfully into high-flow lesions after flow arrest to allow a minimally invasive and durable treatment for pial AVFs. (DOI: 10.3171/2011.4.PEDS10577)

KEY WORDS • fistula • balloon-assisted embolization •
pial arteriovenous fistula • arteriovenous malformation • vascular disorder

ANGIOGRAPHICALLY, single-channel pial AVFs of the brain are characterized by an immediate and often indistinct transition from artery to vein without an intervening nidus or capillary bed, as occurs in arteriovenous malformations. Pial AVFs can be congenital or acquired, and they are distinct from dural AVFs in that their blood supply is derived from cortical or pial arteries. Moreover, the lesion does not lie within the dural leaflets. They typically display high-flow dynamics and are frequently associated with large venous varices. Symptoms attributable to pial AVFs are usually the consequence of high-flow arteriovenous shunting or mass effect from the venous varices. Pial AVFs account for 1%–5% of all brain vascular malformations.^{3,10,11}

The natural history of pial AVFs is unfavorable; the mortality rate associated with conservative treatment can be as high as 63%.⁹ Several investigators have re-

ported that resection of these lesions is unnecessary and that simple flow discontinuation via surgical clipping or endovascular embolization is a safe and effective treatment.^{4,12–14} Endovascular embolization is usually preferred for lesions in areas difficult to access surgically; however, the individual characteristics of a given fistula can make embolization difficult. We report the novel application of Onyx embolic agent with balloon-assisted flow arrest in the successful embolization of 2 large intracranial pial AVFs.

Illustrative Cases

Case 1

History and Examination. This 6-year-old boy presented with progressive headaches, lethargy, and the subacute onset of left hemiparesis. Computed tomography studies of the head showed several large calcified masses in the posterior fossa and pineal region. The largest mass

Abbreviations used in this paper: AVF = arteriovenous fistula; VA = vertebral artery.

in the posterior fossa obliterated the aqueduct of Sylvius, and the patient demonstrated early triventricular hydrocephalus and lateral displacement of the brainstem (Fig. 1). Contrast-enhanced MR images characterized the lesion as vascular and prompted consultation with our neurovascular team. The patient underwent cerebral angiography, which demonstrated a single-channel, high-flow pial AVF with 3 venous varices.

Surgical Technique. Embolization was performed with neurophysiological monitoring (somatosensory evoked potentials and electroencephalography) while the patient was under general anesthesia. After bifemoral access was established, the remainder of the procedure was performed with full anticoagulation. Angiograms were obtained first via simultaneous injections of the VAs in standard projections so that the relationship of the fistulous point and feeding artery to the vertebrobasilar junction, posterior inferior cerebellar artery, and anterior inferior cerebellar artery could be visualized. Downstream of the first giant varix, venous drainage occurred primarily through the vein of Galen, which also demonstrated aneurysm dilation (Fig. 2).

After the angioarchitecture of the lesion was delineated, the diagnostic catheter was exchanged for a 6 Fr guide catheter into the right VA. A 2.4 Fr Echelon microcatheter (ev3, Inc.) was positioned through the guide cath-

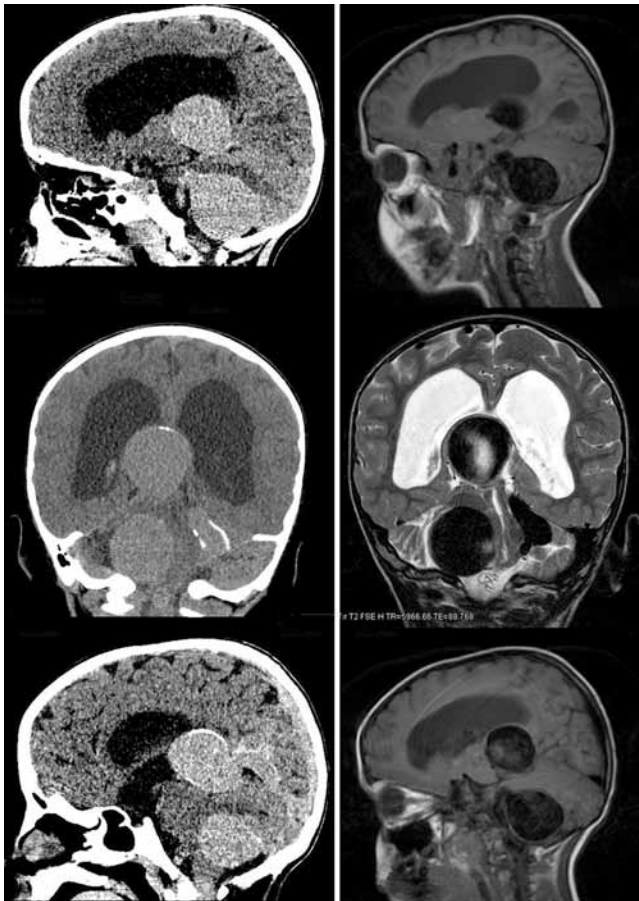


FIG. 1. Case 1. Preoperative CT scans (**left**) and MR images (**right**) showing the large venous varices displacing the brainstem and compressing the aqueduct, resulting in obstructive hydrocephalus.

eter into the feeding artery, just proximal to the fistulous point. A 7 × 7-mm HyperForm balloon (ev3, Inc.) was advanced along the microcatheter and positioned just distal to the exit of the feeding artery from the VA but proximal

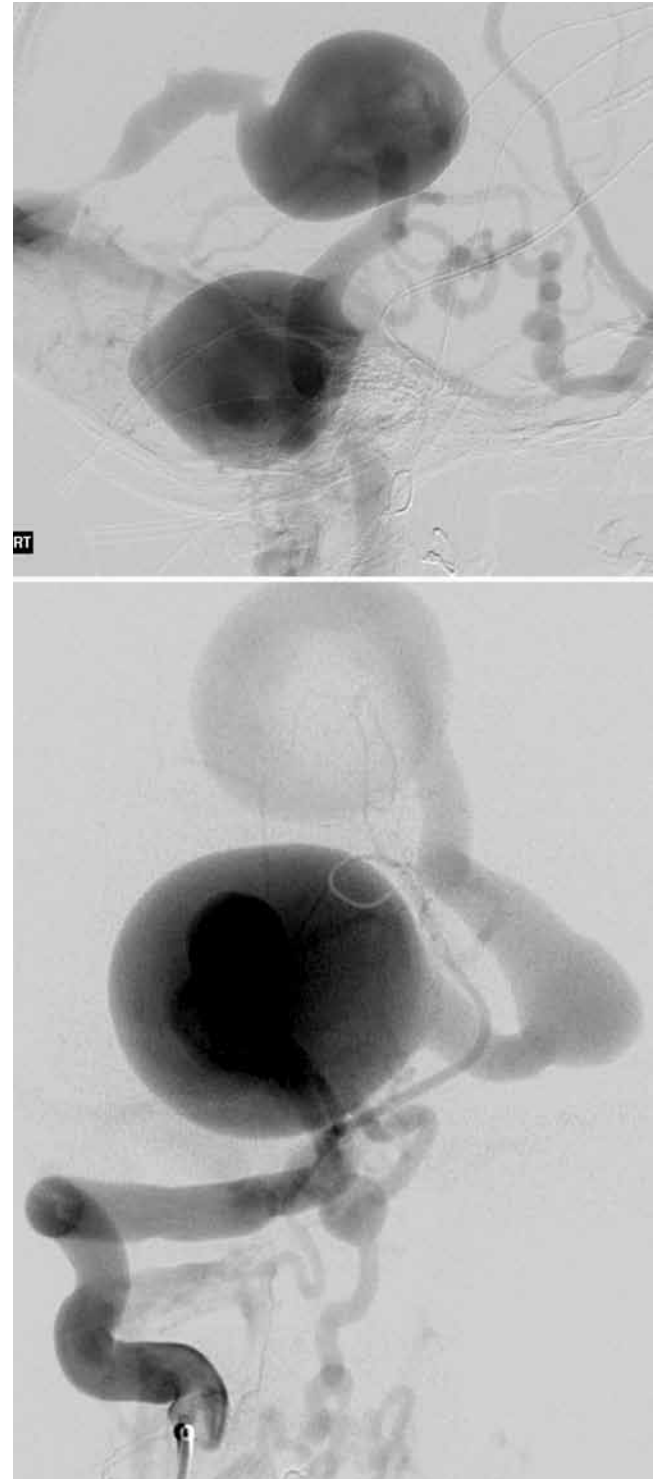


FIG. 2. Case 1. Preembolization lateral (**upper**) and posteroanterior (**lower**) projections of the right VA injection showing the large aneurysmal dilations of the draining veins, including the vein of Galen. The presence of a stricture in the straight sinus may explain the development of the alternate drainage pathways through the deep cervical system.

Balloon-assisted embolization of high-flow fistulas

to the microcatheter. The balloon was then carefully inflated, and flow arrest through the fistula was confirmed with an injection through the right VA guide catheter.

When the balloon was inflated, the working microcatheter was primed with saline and dimethyl sulfoxide in the standard fashion. Altogether, about 1.4 ml of Onyx 34 (8% ethylene vinyl alcohol; ev3, Inc.) was infused under continuous fluoroscopic visualization. During embolization the balloon was partially deflated, and repeat angiography through the guide catheter demonstrated some persistent opacification of the varix. The balloon was reinflated, and the remainder of the Onyx was infused into the cast. Again, the balloon was slowly deflated, and the Onyx plug was carefully observed for stability. Angiography studies repeated through the guide catheter confirmed obliteration of the fistula. The balloon was reinflated, and the working microcatheter was slowly withdrawn under aspiration. Note that the microcatheter was withdrawn while the balloon was inflated to minimize the chance of dislodging the Onyx plug. When the working catheter was removed, the balloon was deflated and removed. A final angiogram reconfirmed obliteration of the fistula (Fig. 3). After the procedure the patient's anticoagulation was reversed with intravenous protamine, and manual pressure was applied to the arteriotomy sites.

Postoperative Course. Follow-up angiography at 8 months (Fig. 4) confirmed a durable result. Magnetic resonance imaging at 6 months (Fig. 5) showed no appreciable change in the mass effect due to the thrombosed varix with improvement in his ventriculomegaly. The patient remains asymptomatic.

Case 2

History and Examination. This 17-year-old boy underwent attempted embolization of a large posterior fossa pial AVF at another institution 2 years before consultation with our neurovascular team. Initially, the lesion was discovered after he had suffered a spontaneous hemorrhage that caused substantial neurological deficits, including coma, hemiplegia, and lower cranial neuropathies. In the ensuing months, the patient made an almost complete recovery and was left with only deafness in his right ear at the time of our evaluation. The referring institution had attempted coil embolization, which failed when the coil migrated out of the fistulous point and into the venous pouch (Fig. 6).

Surgical Technique. As in the patient in Case 1, the procedure was performed with neurophysiological monitoring while the patient was under general anesthesia. After bifemoral arterial access was established, anticoagulation with intravenous heparin was begun. Each VA was selectively catheterized with a 5 Fr UCSF II diagnostic catheter. An angiogram of the simultaneous injection of the VAs was obtained (Fig. 6). We identified the feeding arterial pedicle to the fistula arising from the right VA. The arterial segment leading to the fistulous point was slightly shorter than in the patient in Case 1 and required a modification of the approach. The diagnostic catheter in the right VA was then exchanged for a 6 Fr guide catheter. A 7 × 7-mm HyperForm balloon was advanced over an

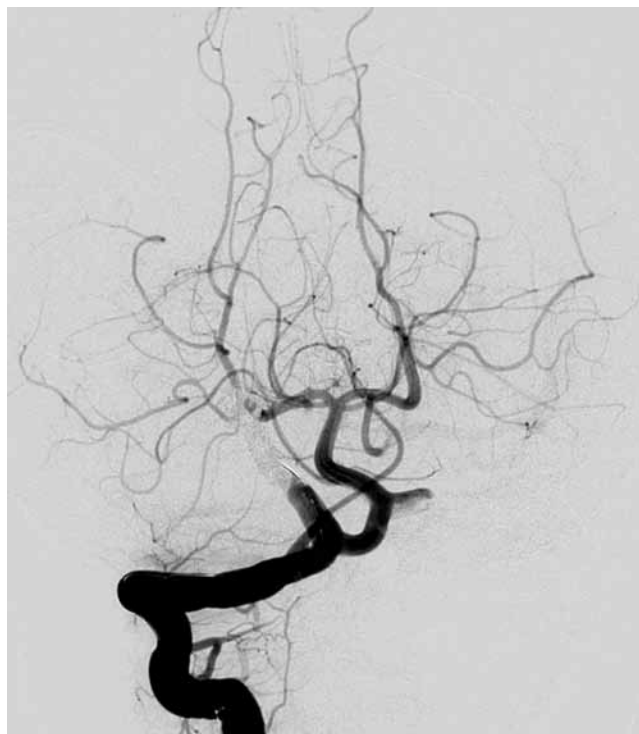

FIG. 3. Case 1. Postembolization right VA injection angiogram, posteroanterior projection, confirming obliteration of the fistula.

0.010-in microguidewire and positioned in the right VA across the ostium of the feeding artery. A 2.4 Fr Echelon microcatheter was positioned in the feeding artery just proximal to the fistulous point (identified by the change in caliber of the artery). The balloon was then inflated in the VA and allowed to herniate slightly into the feeding artery (Fig. 7).

An angiogram obtained through the guide catheter showed that the balloon was occluding the fistula. An angiogram obtained through the contralateral VA demonstrated adequate perfusion of the posterior circulation. The working catheter was primed with saline and dimethyl sulfoxide according to the manufacturer's specifications. Altogether, about 2 ml of Onyx 34 was infused into the feeding artery. Onyx was noted to cast around the herniated portion of the balloon, but no reflux into the VA was seen (Fig. 8).

The balloon was slowly deflated, and the Onyx cast was thought to be stable. An angiogram obtained through a guide catheter injection showed that the fistula had been obliterated. The balloon was reinflated and the working microcatheter was withdrawn. Final angiography studies obtained after the microcatheter and balloon were removed showed no arteriovenous shunting.

Postoperative Course. Follow-up imaging 6 months after embolization confirmed that closure of the fistula was stable (Fig. 9). The patient remains at his neurological baseline.

Discussion

Little is known about the natural history of intracranial pial AVFs given the rarity of these lesions. However,

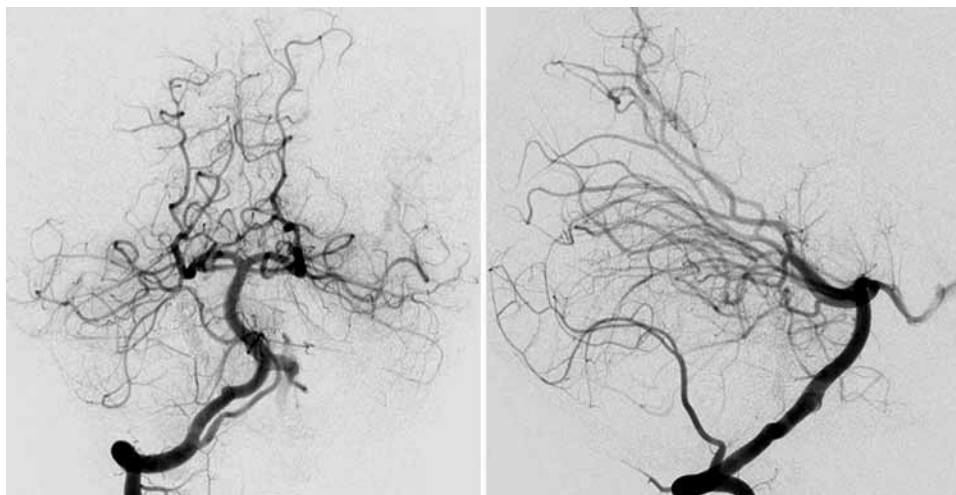


Fig. 4. Case 1. Follow-up angiograms, posteroanterior (**left**) and lateral (**right**) projections, obtained 8 months after embolization, demonstrating a durable result.

spontaneous closure of the fistula cannot be expected. If left untreated, these lesions can cause seizures, headache, hemorrhage, high-output cardiac failure, macrocephaly, neurological deficit, and symptoms of increased intracranial pressure.^{1,2,5} Their origin is unknown. Simple flow discontinuation without lesion resection has been shown to be a safe and effective treatment for pial AVFs. Consequently, endovascular embolization has become the preferred method of treatment for most pial AVFs. These fistulas are usually diagnosed during infancy or early childhood, and most cases are considered to be congenital.^{6,8}

The goal of endovascular embolization should be obliteration of the fistula with as little embolic material as possible. High-flow lesions can make it difficult to deliver the desired embolic agent precisely to the fistulous point. Delivery of embolic material into the draining vein can compromise venous outflow of the fistula or cause pulmonary embolus. Restricted venous outflow in the setting of an incompletely obliterated fistula can have disastrous consequences.

Balloons have been used successfully to modulate flow through high-flow AVFs and malformations. As far as we know, however, this is the first report on the successful embolization of giant, high-flow AVFs with Onyx. Some authors have advised against using nonadherent embolic agents, such as Onyx, to treat fistulous lesions.⁷ But we have found that the increased ability to control the delivery of Onyx, as compared with N-butyl cyanoacrylate, allows more precise targeting and delivery of embolic material to the fistulous point. The ability to modulate or arrest flow through a large artery using highly flexible and navigable balloons augments this degree of precision.

Coil embolization with balloon flow arrest has been successfully used in the treatment of single-channel high-flow fistulas in the past. However, published success rates for endovascular techniques have not been impressive. In their series of 79 patients, Hoh et al.⁴ reported that the failure rate of endovascular embolization for pial AVFs was as high as 40%. Given the fact that attempted coil embolization had already failed in the patient in Case 2, we were compelled to try a different treatment modality.

The patient in Case 1 may have also had a good outcome with coil embolization; however, we believed that the segment of artery leading to the fistula would easily accommodate an Onyx cast and would be favorable for this approach. In our opinion, Onyx infusion after flow arrest offers an additional level of control as compared with coil embolization. Even with balloon-assisted flow arrest, coil loops can frequently herniate distally into the venous pouch. Our treatment goal is to obliterate the fistula with as little embolic material as possible, and we be-

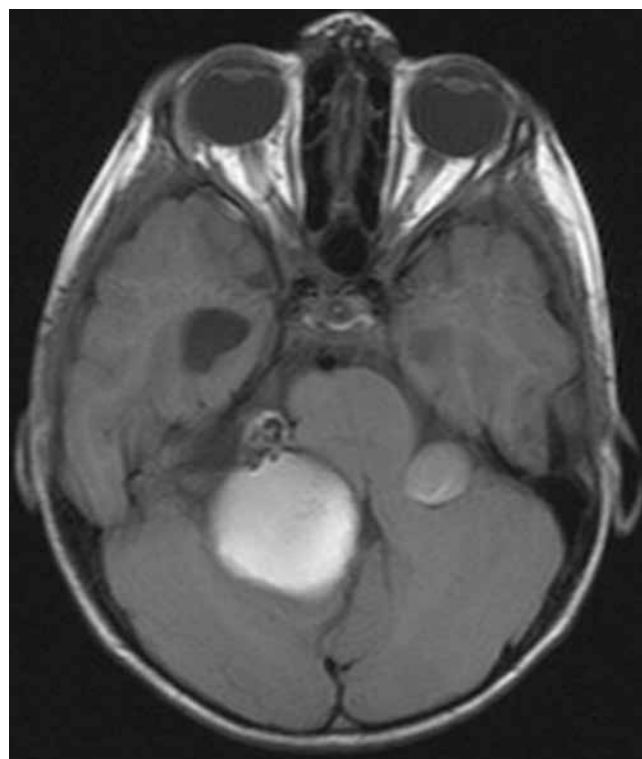


Fig. 5. Case 1. Axial MR image obtained at 6 months, demonstrating no progression of the varix, stable mass effect, and improvement in ventriculomegaly.

Balloon-assisted embolization of high-flow fistulas

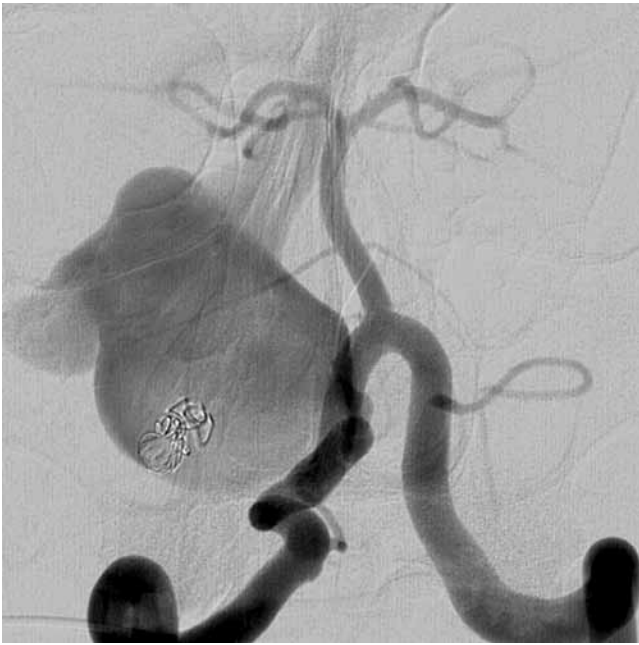


FIG. 6. Case 2. Angiogram, posteroanterior projection, demonstrating simultaneous injections of the VA. Note the presence of the coil mass within the varix from the prior embolization attempt.

lieve that the additional level of control afforded by Onyx deposition helps us to achieve this objective. Nonetheless, coil embolization remains a viable treatment option, and decisions about specific technique should be made based on the individual patient characteristics and the comfort level of the surgeon.

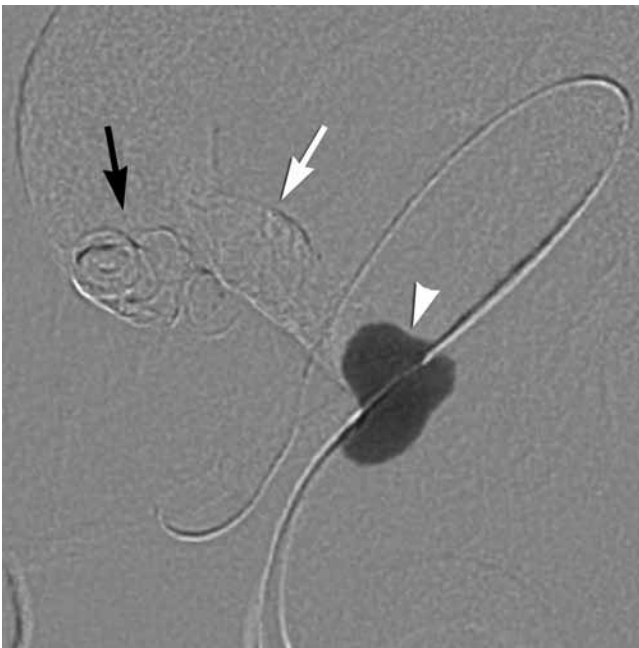


FIG. 7. Case 2. Subtracted roadmap radiograph obtained after balloon inflation, showing the conformable balloon herniating into the feeding artery of the fistula. The Onyx cast (*white arrow*) can be seen between the portion of the balloon herniating into the vessel (*white arrowhead*) and the orphaned coil mass (*black arrow*).

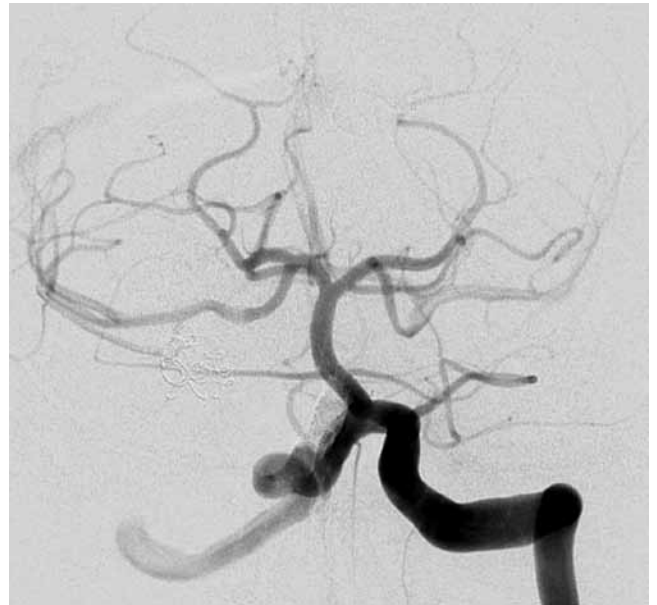

FIG. 8. Case 2. Postembolization angiogram confirming obliteration of the fistula.

Even with newly available microcatheters and balloons, a comment about the techniques used in these cases is warranted. It is our practice to use full anticoagulation in elective cases in which a balloon is utilized, to minimize the chance of thromboembolic complications. The most critical portion of the procedure is deciding when to deflate the balloon after the initial cast of Onyx has been delivered to the fistulous point. In both of our cases, we undertook a series of inflation-deflation cycles between infusions of Onyx to continually assess for stability. If the cast is not stable, venous embolization can ensue after flow resumes. Slow, patient, and meticulous injection at the initial appearance of Onyx at the microcatheter tip provides a maximally viscous and controllable cast with which to work. If the balloon actually occludes the feeding artery, the risk of the Onyx plug migrating should be minimal.

The goal should be radial expansion of the cast. Antegrade progression of the embolic agent into the venous pouch should be avoided, unless the geometry of the ensu-

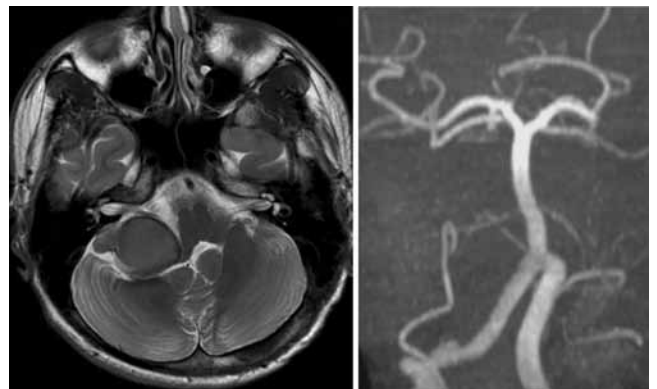


FIG. 9. Case 2. Posttreatment MR image (*left*) and MR angiogram (*right*) showing thrombosis of the varix and closure of the fistulous point.

ing cast would be favorable to prevent distal embolization (that is, V- or L-type configuration). Reflux around the distal end of the balloon is not altogether undesirable, but excessive embolic agent around the microcatheter should be avoided. We tend to allow more time than usual for the Onyx cast to solidify between injections (compared with embolization for a low-flow lesion) and are slightly more aggressive in infusing to try to radially appose the cast to the walls of the artery. We recommend removing the microcatheter with the balloon inflated to minimize the chance of disrupting the cast.

Thrombosis of the varix can lead to a temporary exacerbation of mass effect. Hydrocephalus as a result of venous occlusion has also been reported.⁶ We believe that the risk of this complication can be reduced by applying the Onyx cast precisely at the fistulous point and taking care not to allow the embolic agent to progress into the normal venous circulation. Both of our patients were hospitalized for 72 hours of observation after their procedures and treated with prophylactic dexamethasone.

The two featured cases demonstrate the novel application of balloon-assisted Onyx closure of high-flow pial AVFs, with successful and durable obliteration of the target lesions and no distal embolization of the embolic material.

Disclosure

The authors report no conflict of interest concerning the materials or methods used in this study or the findings specified in this paper.

Author contributions to the study and manuscript preparation include the following. Conception and design: Albuquerque, McDougall. Acquisition of data: all authors. Analysis and interpretation of data: Albuquerque, Newman, Hu. Drafting the article: Newman. Critically revising the article: Albuquerque, Newman, Hu.

References

1. Aoki N, Sakai T, Oikawa A: Intracranial arteriovenous fistula manifesting as progressive neurological deterioration in an infant: case report. **Neurosurgery** **28**:619–623, 1991
2. García-Mónaco R, Taylor W, Rodesch G, Alvarez H, Burrows P, Coubes P, et al: Pial arteriovenous fistula in children as presenting manifestation of Rendu-Osler-Weber disease. **Neuroradiology** **37**:60–64, 1995
3. Halbach VV, Higashida RT, Hieshima GB, Hardin CW, Dowd CF, Barnwell SL: Transarterial occlusion of solitary intracerebral arteriovenous fistulas. **AJNR Am J Neuroradiol** **10**:747–752, 1989
4. Hoh BL, Putman CM, Budzik RF, Ogilvy CS: Surgical and endovascular flow disconnection of intracranial pial single-channel arteriovenous fistulae. **Neurosurgery** **49**:1351–1364, 2001
5. Lasjaunias P: A revised concept of the congenital nature of cerebral arteriovenous malformations. **Interv Neuroradiol** **3**:275–281, 1997
6. Lv X, Jiang C, Li Y, Yang X, Wu Z: Clinical outcomes of endovascular treatment for intracranial pial arteriovenous fistulas. **World Neurosurg** **73**:385–390, 2010
7. Mounayer C, Hammami N, Piotin M, Spelle L, Benndorf G, Kessler I, et al: Nidal embolization of brain arteriovenous malformations using Onyx in 94 patients. **AJNR Am J Neuroradiol** **28**:518–523, 2007
8. Nakiri GS, Abud TG, Oliveira RS, Santos AC, Machado HR, Abud DG: Endovascular treatment of intracranial pial arteriovenous fistula. **Arq Neuropsiquiatr** **68**:463–465, 2010
9. Nelson PK, Niimi Y, Lasjaunias P, Berenstein A: Endovascular embolization of congenital intracranial pial arteriovenous fistulas. **Neuroimaging Clin N Am** **2**:309–317, 1992
10. Tomlinson FH, Rüfenacht DA, Sundt TM Jr, Nichols DA, Fode NC: Arteriovenous fistulas of the brain and the spinal cord. **J Neurosurg** **79**:16–27, 1993
11. Viñuela F, Fox AJ, Kan S, Drake CG: Balloon occlusion of a spontaneous fistula of the posterior inferior cerebellar artery. Case report. **J Neurosurg** **58**:287–290, 1983
12. Weon YC, Yoshida Y, Sachet M, Mahadevan J, Alvarez H, Rodesch G, et al: Supratentorial cerebral arteriovenous fistulas (AVFs) in children: review of 41 cases with 63 non choroidal single-hole AVFs. **Acta Neurochir (Wien)** **147**:17–31, 2005
13. Yoshida Y, Weon YC, Sachet M, Mahadevan J, Alvarez H, Rodesch G, et al: Posterior cranial fossa single-hole arteriovenous fistulae in children: 14 consecutive cases. **Neuroradiology** **46**:474–481, 2004
14. Youn SW, Han MH, Kwon BJ, Kang HS, Chang HW, Kim BS: Coil-based endovascular treatment of single-hole cerebral arteriovenous fistulae: experiences in 11 patients. **World Neurosurg** **73**:2–10, 2010

Manuscript submitted December 20, 2010.

Accepted April 1, 2011.

Address correspondence to: Felipe C. Albuquerque, M.D., c/o Neuroscience Publications, Barrow Neurological Institute, St. Joseph's Hospital and Medical Center, 350 W. Thomas Road, Phoenix, Arizona 85013. email: neuropub@chw.edu.