



Published in final edited form as:

Neurosurgery. 2011 February ; 68(2): E581–E586. doi:10.1227/NEU.0b013e31820208a6.

Intraventricular Hemorrhage Secondary to Intranidal Aneurysm Rupture—Successful Management by Arteriovenous Malformation Embolization Followed by Intraventricular Tissue Plasminogen Activator: Case Report

Glen A. Pollock, MD, DVM^{*}, Ali Shaibani, MD[†], Issam Awad, MD[‡], H. Hunt Batjer, MD[§], Bernard R. Bendok, MD[§]

^{*}Department of Neurosurgery and Brain Repair, University of South Florida, Tampa, Florida

[†]NeuroInterventional Surgery, Northwest Community Hospital, Arlington Heights, Illinois

[‡]Section of Neurosurgery, University of Chicago Hospitals, Chicago, Illinois

[§]Department of Neurological Surgery, Feinberg School of Medicine, Northwestern University, Chicago, Illinois

Abstract

BACKGROUND AND IMPORTANCE: Intraventricular hemorrhage related to arteriovenous malformation (AVM) rupture is associated with significant morbidity and mortality.

Intraventricular tissue plasminogen activator (tPA) has been used to treat spontaneous intraventricular hemorrhage. We demonstrate the successful application of endovascular occlusion to seal the rupture site of an AVM followed by intraventricular tPA.

CLINICAL PRESENTATION: A 32-year-old woman presented with a right frontoparietal parasagittal AVM abutting the motor cortex. The AVM was diagnosed when the patient was 13 years old, and she initially underwent conservative management. At the age of 30, the patient suffered an intracranial hemorrhage, leaving her with left hemiparesis. After rehabilitation, the patient regained ambulation; however, she remained spastic and hyperreflexic on the left side. Two years after her major hemorrhage, she presented for elective treatment of her AVM. The patient was advised to undergo staged embolization before surgical resection of her AVM. The initial embolization was uneventful. A second embolization was complicated by intraventricular hemorrhage and coma. The patient was treated with placement of an external ventricular drain followed by embolization of intranidal aneurysm. After embolization of the intranidal aneurysm the ruptured, the patient was treated with intraventricular tPA. The patient had rapid clearance of the intraventricular hemorrhage and significant improvement in her neurological examination, following commands 24 hours later and returning almost to baseline.

Correspondence: Bernard R. Bendok, MD, Associate Professor of Neurological, Surgery and Radiology, Northwestern University Feinberg, School of Medicine, and, McGaw Medical Center, 676 N St. Clair St, Ste 2210, Chicago, IL 60611. bbendok@nmff.org.

Disclosure

The authors have no personal financial or institutional interest in any of the drugs, materials, or devices described in this article.

CONCLUSION: This case demonstrates the feasibility of treating AVM-related intraventricular hemorrhage with tPA if the rupture source can be confidently sealed interventionally. This strategy can be lifesaving but needs further study to ensure its safety.

Keywords

Cerebral arteriovenous malformation; Intracranial aneurysm; Intracranial hemorrhage; Intraventricular hemorrhage; Tissue plasminogen activator

Intracranial hemorrhage as a result of arteriovenous malformation (AVM) rupture is the main cause of morbidity and mortality in patients with AVMs and is complicated by intraventricular hemorrhage (IVH) in as many as 16% of ruptured AVMs in one series.¹ IVH leads to worsened outcome compared with AVM rupture without IVH.^{2,3} IVH can lead to obstruction of normal cerebrospinal fluid (CSF) flow and absorption, leading to increased intracranial pressure and hydrocephalus; intraventricular hematomas can cause mass effect and compress periventricular structures, leading to ischemia.⁴⁻⁷ The level of consciousness on admission has been directly correlated with the amount of intraventricular blood.⁸ Casting of the entire ventricular system has been associated with high mortality, as has casting of the fourth ventricle.⁹⁻¹¹

Spontaneous IVH has been effectively treated with throm-bolytics, allowing faster clearance of the intraventricular hematoma and prevention of occlusion of ventricular catheters during treatment. The literature suggests that this technique may improve outcome, and a National Institutes of Health-funded trial (Clot Lysis Evaluating Accelerated Resolution of Intraventricular Hemorrhage) is currently ongoing to evaluate this treatment.¹² Ruptured AVMs and aneurysms as causes of IVH are considered exclusion criteria in the trials of thrombolytics for IVH resulting from the risk of hemorrhage. However, some case reports support the use of thrombolytics in cases of ruptured aneurysms after they were initially secured by surgical or endovascular therapy.^{9,12-21} There are reports of the use of tissue plasminogen activator (tPA) in cases of IVH in the presence of an unsecured ruptured AVM.^{16,22} To the best of our knowledge, securing the rupture site from an AVM with embolization followed by intraventricular tPA has not been previously reported.

CASE REPORTS

The patient is a 32-year-old woman with a right frontoparietal parasagittal AVM 4 cm in diameter with abutment of the motor cortex (Figure 1). The AVM was first diagnosed at age 13 when she presented with seizures. The patient was managed conservatively and followed up with serial imaging without deficit until she suffered an intracranial hemorrhage caused by AVM rupture at the age of 30, which left her with persistent left-sided hemiparesis. The patient was treated in the intensive care unit at that time for 12 days. The patient made progress in her rehabilitation and regained her ambulatory status. However, she remained spastic and hyperreflexic on the left side. The patient was referred to Northwestern Memorial Hospital for evaluation for further therapy in light of her substantial risk for rehemorrhage.

On cerebral angiography, there was a hypertrophied lenticulostriate artery of the right middle cerebral artery supplying the inferior aspect of the malformation and hemispheric right middle cerebral artery branches supplying the lateral aspect. There were also smaller, less prominent feeders from the right anterior cerebral artery. The drainage appeared via a large venous varix into the superior sagittal sinus with antegrade flow. At the time of the pretreatment angiogram, no intranidal or feeding artery aneurysms were visualized.

Based on the imaging, previous hemorrhage, and lifetime risk of recurrent hemorrhage, a recommendation was made to the patient for staged embolization followed by surgical resection. The patient underwent her initial embolization without complications other than a mild headache that occurred 2 days after the embolization and resolved spontaneously without other neurological changes. At the time of the initial embolization, the diagnostic cerebral angiogram revealed several small intranidal aneurysms along the inferior aspect of the AVM (Figure 2). The second staged embolization occurred 2 weeks later, after which the patient remained at her neurological baseline without other complaints. The next morning, the patient complained of a severe headache; she then became unresponsive and developed dilated unresponsive pupils and decerebrate posturing on the left side. She was taken for a noncontrasted head computed tomography (Figure 3), which revealed diffuse IVH with dilation of the fourth ventricle. An emergent left frontal external ventricular drain (EVD) was placed, and the patient was taken to the endovascular neurosurgical suite for angiogram and treatment. The patient then underwent embolization of 3 pedicle feeding arteries off the right pericallosal artery via the right anterior cerebral artery. One feeder was embolized with n-butyl-cyanoacrylate (nBCA) (Cordis Neurovascular, Miami, Florida) and the other 2 feeders with Onyx (ev3 Neurovascular, Plymouth, Minnesota). The embolization filled the intranidal aneurysms on the inferior aspect of the AVM (Figure 4).

Once the source of hemorrhage, the ruptured intranidal aneurysms, was secured by glue embolization, the patient was treated with intraventricular tPA through the left frontal EVD. The patient was treated with 1 mg IV tPA once every 12 hours until the IVH cleared. The patient was treated by withdrawing 2 cm³ CSF from the EVD and then injecting 1 mg tPA in 1 cm³ sterile saline followed by 1 cm³ sterile saline flush. The EVD was then clamped at the injection site for 60 minutes before unclamping and allowing CSF to drain. tPA was injected once every 12 hours for a total of 9 injections. No revision or replacement of the patient's EVD was necessary, and the EVD continued to drain CSF until it was removed on the 12th day after her hemorrhage. The patient remained in the intensive care unit after embolization of her intranidal aneurysms. She was initially comatose but began to follow commands 24 hours after the hemorrhage. She then slowly improved during her treatment course until she was eventually mobilized and transferred out of the intensive care unit approximately 24 hours after her EVD was removed on the 13th day after her hemorrhage (Figure 5). The patient was discharged to a rehabilitation facility on the 20th day after her hemorrhage (Figure 6). On discharge to the rehabilitation facility, the patient was alert and oriented with residual left spastic hemiparesis. She had recovered significant strength on her left side and was at her neurological baseline with the exception of her left hand, which remained weaker.

DISCUSSION

Spontaneous IVH has been effectively treated with thrombolytics, allowing faster clearance of hematoma from the ventricular system and prevention of the occlusion of ventricular catheters during CSF drainage, leading to improved out-comes.^{12,17,22,23} Ruptured AVMs or aneurysms as the cause of intracerebral or IVH have historically been contraindications to the use of thrombolytics because of the risk of rehemorrhage and further neurological deterioration and deficit.^{9,12–16–21} However, thrombolytics have been used to treat IVH in patients after endovascular treatment to secure ruptured aneurysms, eliminating or significantly reducing the risk of rehemorrhage. There are also reports of the use of thrombolytics in cases of IVH in the presence of unsecured ruptured AVMs.^{16,22} One case report discussed the use of intraventricular tPA for IVH before occlusion or obliteration of a ruptured AVM; however, we do not recommend the use of thrombolytics in patients with unsecured ruptured AVMs or aneurysms because of the potential for catastrophic rehemorrhage.²⁴

Here, we present a treatment strategy for IVH caused by intranidal aneurysm rupture in a patient with an AVM. Intraventricular tPA was administered after embolization of the intranidal aneurysm with tPA at a dose consistent with that used in the phase II Clot Lysis Evaluating Accelerated Resolution of Intraventricular Hemorrhage trial (www.CLEARIVH.com). The patient required 9 doses of tPA to achieve clearance of the intraventricular blood with resolution of a casted fourth ventricle and continued unobstructed drainage of CSF until the 12th day after her hemorrhage, when she met clinical and radiographic criteria for EVD removal. In this case, the source of hemorrhage was secured using liquid embolic agents to fill the intranidal portion of the AVM containing the aneurysm suspected of rupture while also obliterating a larger portion of the AVM nidus. The use of liquid embolics for AVM treatment is well documented, and embolics have also been used to eliminate AVM-associated aneurysms.^{25–47} Once the use of the embolic agent completely obliterated the offending aneurysm, intraventricular tPA was used to expedite the clearance of the IVH without further hemorrhage.

This treatment strategy is novel and presents a useful algorithm in patients who have significant IVH as a result of a ruptured AVM caused by intranidal or AVM-associated aneurysms. There are multiple potential benefits to the patient. We believe that this treatment strategy may lead to improved neurological outcome and to a decrease in the number of ventriculoperitoneal shunts needed after IVH.

Intraventricular tPA is a safe and effective treatment for patients with IVH secondary to AVM-associated aneurysm rupture once the aneurysm is occluded by embolization and does not pose a risk for recurrent hemorrhage that ordinarily could be exacerbated by fibrinolytic therapy.

ABBREVIATIONS:

AVM	arteriovenous malformation
EVD	external ventricular drain

IVH	intraventricular hemorrhage
tPA	tissue plasminogen activator

REFERENCES

1. Stapf C, Mohr JP, Pile-Spellman J, et al. Concurrent arterial aneurysms in brain arteriovenous malformations with haemorrhagic presentation. *J Neurol Neurosurg Psychiatry*. 2002;73(3):294–298. [PubMed: 12185161]
2. Bhattathiri PS, Gregson B, Prasad KS, Mendelow AD. Intraventricular hemorrhage and hydrocephalus after spontaneous intracerebral hemorrhage: results from the stich trial. *Acta Neurochir Suppl*. 2006;96:65–68. [PubMed: 16671427]
3. Daverat P, Castel JP, Dartigues JF, Orgogozo JM. Death and functional outcome after spontaneous intracerebral hemorrhage. A prospective study of 166 cases using multivariate analysis. *Stroke*. 1991;22(1):1–6. [PubMed: 1987664]
4. Donauer E, Reif J, al-Khalaf B, Mengedocht EF, Faubert C. Intraventricular haemorrhage caused by aneurysms and angiomas. *Acta Neurochir (Wien)*. 1993;122(1–2):23–31. [PubMed: 8333305]
5. Findlay JM, Deagle GM. Causes of morbidity and mortality following intracranial aneurysm rupture. *Can J Neurol Sci*. 1998;25(3):209–215. [PubMed: 9706722]
6. Mayfrank L, Hutter BO, Kohorst Y, et al. Influence of intraventricular hemorrhage on outcome after rupture of intracranial aneurysm. *Neurosurg Rev*. 2001;24(4):185–191. [PubMed: 11778824]
7. Mohr G, Ferguson G, Khan M, et al. Intraventricular hemorrhage from ruptured aneurysm. Retrospective analysis of 91 cases. *JNeurosurg*. 1983;58(4):482–487. [PubMed: 6827343]
8. Taheri SA, Wani MA, Lewko J. Intraventricular hemorrhage due to rupture of arteriovenous malformations. *Zentralbl Neurochir*. 1990;51(4):201–205. [PubMed: 2099057]
9. Goh KY, Poon WS. Recombinant tissue plasminogen activator for the treatment of spontaneous adult intraventricular hemorrhage. *Surg Neurol*. 1998;50(6):526–531. [PubMed: 9870812]
10. Graeb DA, Robertson WD, Lapointe JS, Nugent RA, Harrison PB. Computed tomographic diagnosis of intraventricular hemorrhage, etiology and prognosis. *Radiology*. 1982;143(1):91–96. [PubMed: 6977795]
11. Shapiro SA, Campbell RL, Scully T. Hemorrhagic dilation of the fourth ventricle: an ominous predictor. *J Neurosurg*. 1994;80(5):805–809. [PubMed: 8169618]
12. Naff NJ, Carhuapoma JR, Williams MA, et al. Treatment of intraventricular hemorrhage with urokinase: Effects on 30-day survival. *Stroke*. 2000;31(4):841–847. [PubMed: 10753985]
13. Findlay JM, Grace MG, Weir BK. Treatment of intraventricular hemorrhage with tissue plasminogen activator. *Neurosurgery*. 1993;32(6):941–947. [PubMed: 8327096]
14. Haines SJ, Lapointe M. Fibrinolytic agents in the treatment of intraventricular hemorrhage in adults. *Crit Rev Neurosurg*. 1998;8(3):169–175. [PubMed: 9575312]
15. Mayfrank L, Lippitz B, Groth M, Bertalanffy H, Gilsbach JM. Effect of recombinant tissue plasminogen activator on clot lysis and ventricular dilatation in the treatment of severe intraventricular haemorrhage. *Acta Neurochir (Wien)*. 1993;122(1–2):32–38. [PubMed: 8333306]
16. Mayfrank L, Rohde V, Gilsbach JM. Fibrinolytic treatment of intraventricular haemorrhage preceding surgical repair of ruptured aneurysms and arteriovenous malformations. *Br J Neurosurg*. 1999;13(2):128–131. [PubMed: 10616579]
17. Fountas KN, Kapsalaki EZ, Parish DC, et al. Intraventricular administration of rt-pa in patients with intraventricular hemorrhage. *South Med J*. 2005;98(8):767–773. [PubMed: 16144170]
18. Naff NJ, Hanley DF, Keyl PM, et al. Intraventricular thrombolysis speeds blood clot resolution: Results of a pilot, prospective, randomized, double-blind, controlled trial. *Neurosurgery*. 2004;54(3):577–583. [PubMed: 15028130]
19. Nyquist P, Hanley DF. The use of intraventricular thrombolytics in intraventricular hemorrhage. *J Neurol Sci*. 2007;261(1–2):84–88. [PubMed: 17553525]
20. Nyquist P, LeDroux S, Geocadin R. Thrombolytics in intraventricular hemorrhage. *Curr Neurol Neurosci Rep*. 2007;7(6):522–528. [PubMed: 17999899]

21. Rohde V, Schaller C, Hassler WE. Intraventricular recombinant tissue plasminogen activator for lysis of intraventricular haemorrhage. *J Neurol Neurosurg Psychiatry*. 1995;58(4):447–451. [PubMed: 7738552]
22. Todo T, Usui M, Takakura K. Treatment of severe intraventricular hemorrhage by intraventricular infusion of urokinase. *J Neurosurg*. 1991;74(1):81–86. [PubMed: 1984512]
23. Kumar K, Demeria DD, Verma A. Recombinant tissue plasminogen activator in the treatment of intraventricular hemorrhage secondary to periventricular arteriovenous malformation before surgery: case report. *Neurosurgery*. 2003;52(4):964–969. [PubMed: 12657195]
24. Schwarz S, Schwab S, Steiner HH, Hacke W. Secondary hemorrhage after intraventricular fibrinolysis: a cautionary note: a report of two cases. *Neurosurgery*. 1998;42(3):659–662. [PubMed: 9527003]
25. Biondi A, Jean B, Vivas E, et al. Giant and large peripheral cerebral aneurysms: Etiopathologic considerations, endovascular treatment, and long-term follow-up. *AJNR*. 2006;27(8):1685–1692. [PubMed: 16971615]
26. Cekirge HS, Saatci I, Geyik S, Yavuz K, Ozturk H, Pamuk G. Intracapsular combination of metallic coils and onyx liquid embolic agent for the endovascular treatment of cerebral aneurysms. *J Neurosurg*. 2006;105(5):706–712. [PubMed: 17121131]
27. Debrun G, Vinuela F, Fox A, Drake CG. Embolization of cerebral arteriovenous malformations with bucrylate. *J Neurosurg*. 1982;56(5):615–627. [PubMed: 7069472]
28. Deveikis JP. Endovascular therapy of intracranial arteriovenous malformations. Materials and techniques. *Neuroimaging Clin N Am*. 1998;8(2):401–424. [PubMed: 9562596]
29. Dowzenko A, Jaworski M. [endovascular embolization of cerebral arteriovenous malformation (avm)]. *Neurol Neurochir Pol*. 2003;37(4):861–870. [PubMed: 14746245]
30. Dudeck O, Jordan O, Hoffmann KT, et al. Embolization of experimental wide-necked aneurysms with iodine-containing polyvinyl alcohol solubilized in a low-angiotoxicity solvent. *AJNR Am J Neuroradiol*. 2006;27(9):1849–1855. [PubMed: 17032855]
31. Ezura M, Takahashi A, Jokura H, Shirane R, Yoshimoto T. Endovascular treatment of aneurysms associated with cerebral arteriovenous malformations: experiences after the introduction of Guglielmi detachable coils. *J Clin Neurosci*. 2000;7(Suppl 1):14–18. [PubMed: 11013090]
32. Frizzel RT, Fisher WS III. Cure, morbidity, and mortality associated with embolization of brain arteriovenous malformations: a review of 1246 patients in 32 series over a 35-year period. *Neurosurgery*. 1995;37(6):1031–1039. [PubMed: 8584142]
33. Goto K, Uda K, Ogata N. Embolization of cerebral arteriovenous malformations (avms)-material selection, improved technique, and tactics in the initial therapy of cerebral avms. *Neurol Med Chir (Tokyo)*. 1998;38(Suppl):193–199. [PubMed: 10235005]
34. Henkes H, Nahser HC, Berg-Dammer E, Weber W, Lange S, Kuhne D. Endo-vascular therapy of brain avms prior to radiosurgery. *Neurol Res*. 1998;20(6):479–492. [PubMed: 9713837]
35. Henkes H, Reinartz J, Preiss H, Miloslavski E, Kirsch M, Kuhne D. Endovascular treatment of small intracranial aneurysms: Three alternatives to coil occlusion. *Minim Invasive Neurosurg*. 2006;49(2):65–69. [PubMed: 16708333]
36. Lanzino G, Kanaan Y, Perrini P, Dayoub H, Fraser K. Emerging concepts in the treatment of intracranial aneurysms: stents, coated coils, and liquid embolic agents. *Neurosurgery*. 2005;57(3):449–459. [PubMed: 16145523]
37. Lawton MT, Hamilton MG, Spetzler RF. Multimodality treatment of deep arteriovenous malformations: thalamus, basal ganglia, and brain stem. *Neurosurgery*. 1995;37(1):29–35. [PubMed: 8587687]
38. Lubicz B, Piotin M, Mounayer C, Spelle L, Moret J. Selective endovascular treatment of intracranial aneurysms with a liquid embolic: a single-center experience in 39 patients with 41 aneurysms. *AJNR Am J Neuroradiol*. 2005;26(4):885–893. [PubMed: 15814939]
39. Mawad ME, Cekirge S, Ciceri E, Saatci I. Endovascular treatment of giant and large intracranial aneurysms by using a combination of stent placement and liquid polymer injection. *J Neurosurg*. 2002;96(3):474–482. [PubMed: 11883831]

40. Murayama Y, Vinuela F, Tateshima S, Vinuela F Jr, Akiba Y. Endovascular treatment of experimental aneurysms by use of a combination of liquid embolic agents and protective devices. *AJNR Am J Neuroradiol.* 2000;21(9):1726–1735. [PubMed: 11039357]
41. Nakahara I, Taki W, Kikuchi H, et al. Endovascular treatment of aneurysms on the feeding arteries of intracranial arteriovenous malformations. *Neuroradiology.* 1999;41(1):60–66. [PubMed: 9987772]
42. The N-BCA Trial Investigators. N-butyl cyanoacrylate embolization of cerebral arteriovenous malformations: results of a prospective, randomized, multi-center trial. *AJNR Am J Neuroradiol.* 2002;23(5):748–755. [PubMed: 12006271]
43. Nishi S, Taki W, Nakahara I, et al. Embolization of cerebral aneurysms with a liquid embolus, eval mixture: report of three cases. *Acta Neurochir (Wien).* 1996;138(3):294–300. [PubMed: 8861698]
44. Song DL, Leng B, Xu B, Wang QH, Chen XC, Zhou LF. [clinical experience of 70 cases of cerebral arteriovenous malformations embolization with onyx, a novel liquid embolic agent]. *Zhonghua Wai Ke Za Zhi.* 2007;45(4):223–225. [PubMed: 17502012]
45. Sorimachi T, Koike T, Takeuchi S, et al. Embolization of cerebral arteriovenous malformations achieved with polyvinyl alcohol particles: angiographic reappearance and complications. *AJNR Am J Neuroradiol.* 1999 20(7):1323–1328. [PubMed: 10472993]
46. Weber W, Kis B, Siekmann R, Jans P, Laumer R, Kuhne D. Preoperative embolization of intracranial arteriovenous malformations with onyx. *Neurosurgery.* 2007;61(2):244–252. [PubMed: 17762736]
47. Weber W, Kis B, Siekmann R, Kuehne D. Endovascular treatment of intracranial arteriovenous malformations with onyx: technical aspects. *AJNR Am J Neuroradiol.* 2007;28(2):371–377.

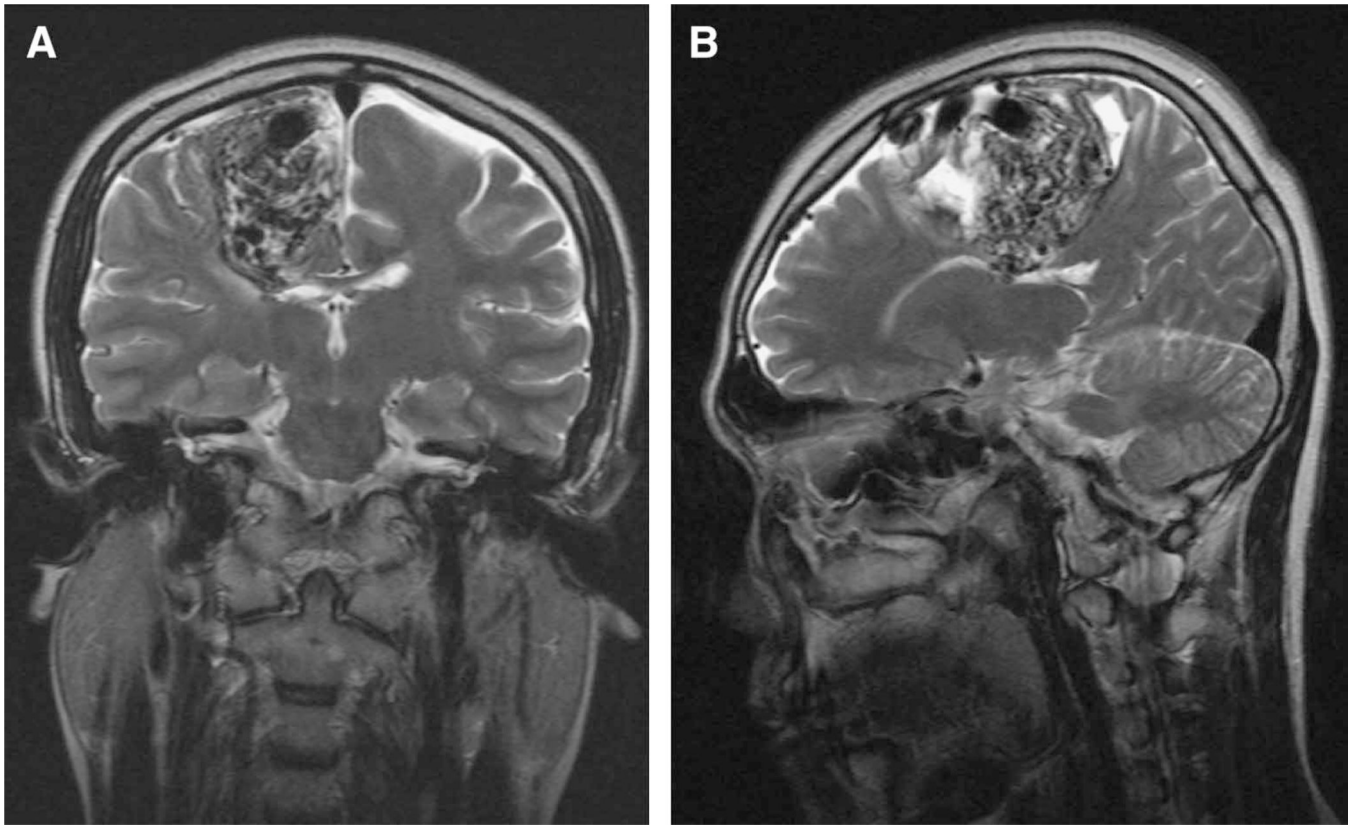


FIGURE 1.
MRI of the brain revealing a right frontoparietal parasagittal AVM. Coronal view (A) and Sagittal view (B).

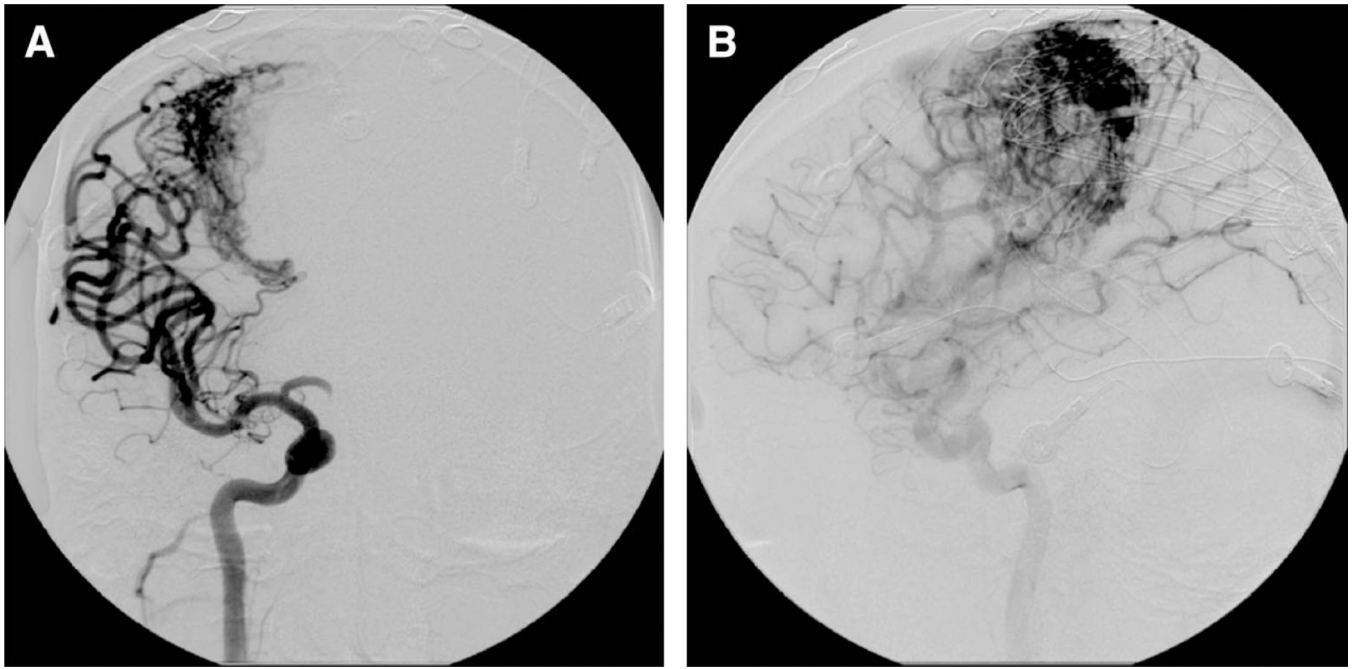


FIGURE 2.
*Preembolization cerebral angiogram revealing multiple intracranial aneurysms. AP view (A)
and lateral view (B).*

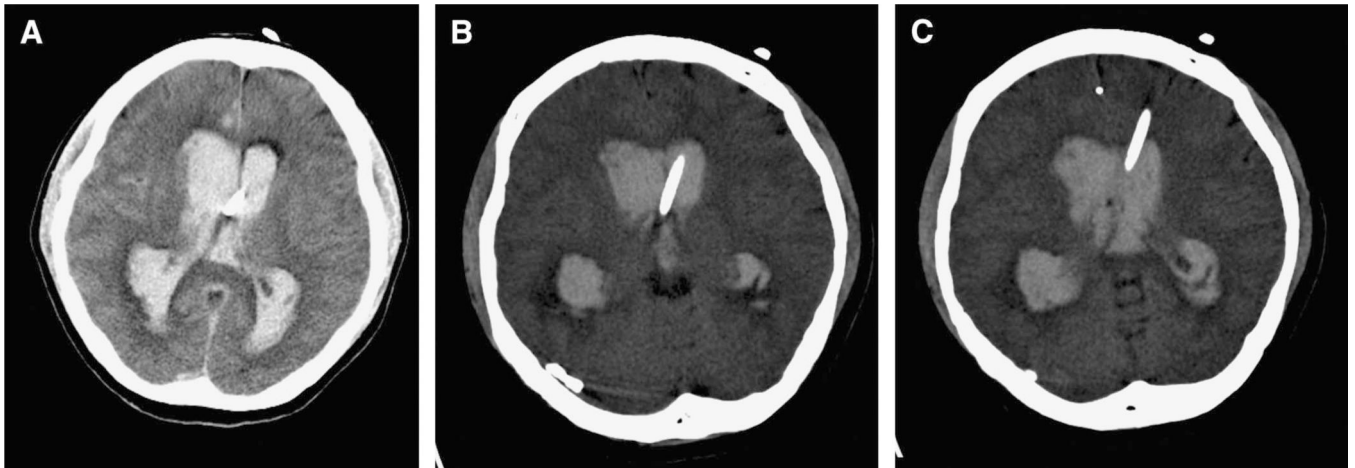


FIGURE 3.
Initial brain CT scan post-hemorrhage.

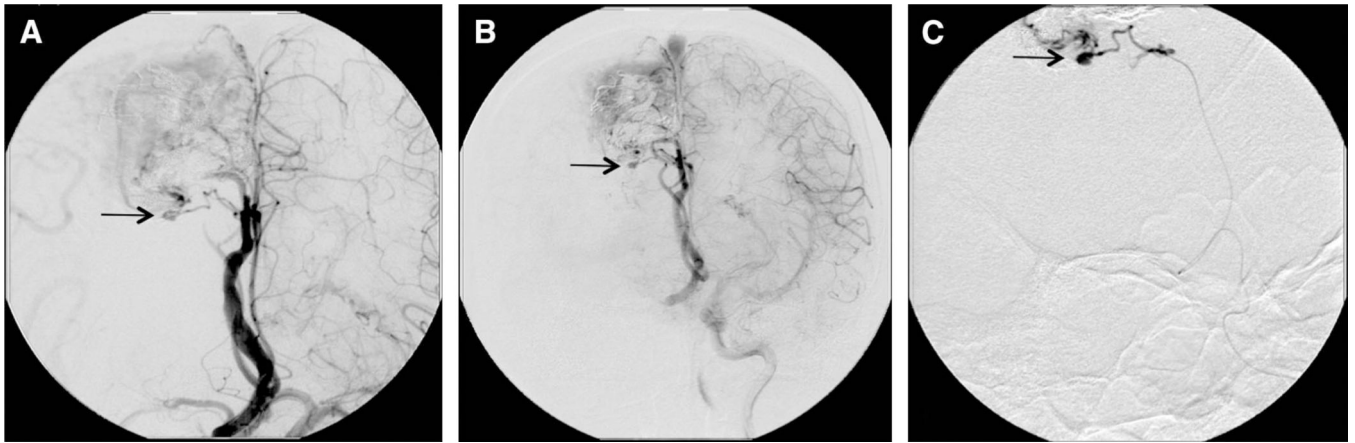


FIGURE 4.
Detection (A and B) and embolization (C) of the ruptured intranidal aneurysm.

Author Manuscript

Author Manuscript

Author Manuscript

Author Manuscript

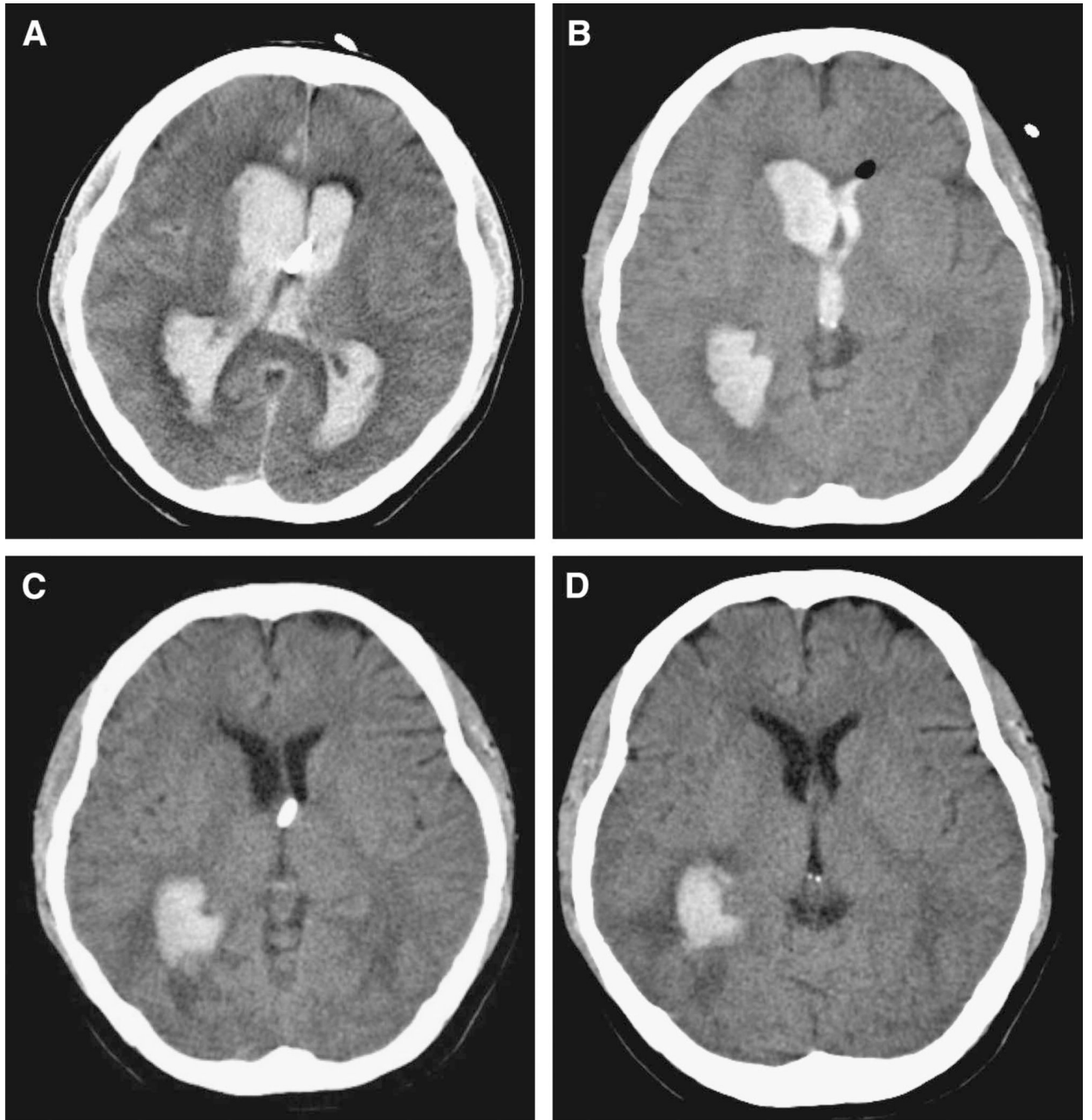


FIGURE 5.
Follow-up brain CT scans at day 1 (A), day 3 (B), day 5 (C), and day 7 (D) post-hemorrhage.

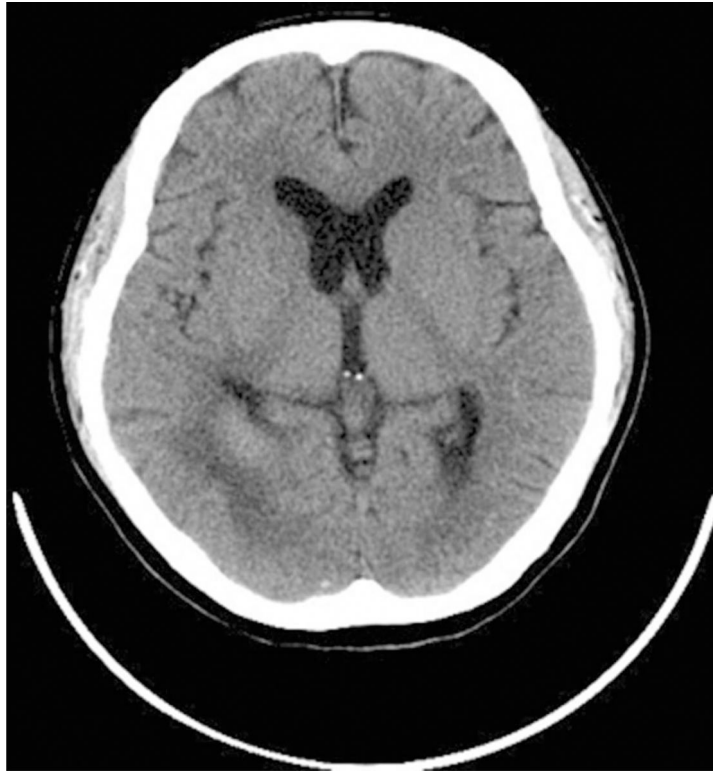

FIGURE 6.
Brain computed tomography after 5 days of tissue plasminogen activator.