

Cerebral Venous Sinus Thrombosis Associated With Cerebral Hemorrhage

Is Anticoagulant Treatment Safe?

Blanca Fuentes, MD, PhD, Patricia Martínez-Sánchez, MD, PhD, Pilar García Raya, MD, Maria José Abenza, MD, and Exuperio Díez Tejedor, MD, PhD

Abstract: The current recommended treatment for cerebral venous sinus thrombosis (CVST) is anticoagulation, and the presence of intracranial hemorrhage (ICH) is not a contraindication. We present a case of ICH associated with CVST in which heparin treatment was associated with rebleeding, and we review current evidence of anticoagulation safety in patients with ICH associated with CVST. A 65-year-old man presented with right hemiparesis and loss of consciousness. Brain computed tomography showed a left frontoparietal hemorrhage. Angiographic studies with magnetic resonance imaging showed the presence of a partial superior sagittal sinus thrombosis. With a diagnosis of CVST, intravenous heparin was administered. After 24 hours the patient had a symptomatic increase in ICH size, and 2 days later the patient developed a status epilepticus with new evidence of rebleeding. Anticoagulant treatment was stopped and the patient experienced neurological improvement, with no new episodes of rebleeding. Evidence for the safety of anticoagulants in CVST comes from 2 small trials involving a total of 79 patients, but only 18 had some degree of bleeding in baseline computed tomography. A meta-analysis suggested that in CVST patients who are treated with anticoagulants, the risk of ICH is low, but acknowledged that an impact of up to 9% of new ICH cannot be ruled out. As there is not enough evidence for the safety of anticoagulant therapy in patients with early ICH associated with CVST, the therapeutic decision must be individualized and the rebleeding risk should be weighed in those patients.

Key Words: cerebral venous sinus thrombosis, cerebral hemorrhage, anticoagulants

(*The Neurologist* 2011;17:208–210)

The development of cerebral infarction associated with hemorrhagic transformation is common in patients with cerebral venous sinus thrombosis (CVST), affecting up to 30% of patients and associated with higher stroke severity and worse outcome.^{1–5} The foundation of the current treatment for CVST is anticoagulation with intravenous unfractionated heparin or subcutaneous low-molecular weight heparin. The guidelines of various neurological societies recommend anticoagulation, and specify that the presence of intracranial hemorrhage (ICH) is not a contraindication to its use.^{6–8} The explanation for the anticoagulant therapy benefit in CVST is

the reversal of obstruction, with improvement in venous return, which reduces the development of venous hypertension and infarction and subsequent neurological deterioration. However, anticoagulants may increase the risk of bleeding in the area of the venous cerebral infarction, as has been recognized in the last update of the European Federation of the Neurological Societies guidelines on the treatment of cerebral venous and sinus thrombosis in adult patients.⁸

An analysis of prognostic factors in the subgroup of patients with the greatest number of CVST published so far has been reported. In those patients with early hemorrhagic transformation, as revealed in the first neuroimaging procedure performed, heparin treatment had no significant influence on outcome. However, in those patients who developed delayed bleeding complications, the lack of early administration of heparin was associated with a worse prognosis.⁴

Here, we present a case of ICH associated with CVST in which treatment with intravenous unfractionated heparin was associated with neurological deterioration with rebleeding, and we review the available evidence on the safety of this treatment.

CASE REPORT

A 65-year-old man presented at the Emergency Room with abrupt onset of clonic movements in his right limbs, loss of consciousness, relaxation of sphincters, and subsequent aphasia. He had only a history of sleep apnea syndrome with intolerance to treatment with continuous positive airway pressure and no other vascular risk factors. Physical examination in the emergency room showed right hemiparesis (0/5 in the right upper extremity and 3/5 in the right leg). Blood tests showed 58% hematocrit, and a discrete increase in mean corpuscular volume (98.2 fl) and fibrinogen (426), with all other hematological and biochemical parameters normal. Brain computed tomography (CT) showed a left parenchymal parietal hemorrhage with slight edema and high attenuation of the superior longitudinal sinus (Fig. 1). Owing to the atypical location of the hemorrhage, subsequent angiographic studies with CT and magnetic resonance imaging were conducted, and they showed the presence of a partial superior longitudinal sinus thrombosis with a parenchymal hemorrhage in the parietal lobe (Fig. 2), ruling out the presence of arteriovenous malformations or dural arteriovenous fistulas.

With a diagnosis of thrombosis of the superior longitudinal sinus, and following current recommendations for CVST treatment, intravenous unfractionated heparin was administered. The activated partial thromboplastin time was monitored with blood analyses performed every 4 to 6 hours and subsequent changes in heparin dosage to maintain levels between 1.5 and 2 times the normal value. Twenty-four hours after the initiation of anticoagulant therapy, the patient had neurological deterioration, and a brain CT showed an increase in the ICH size. Nevertheless, intravenous heparin was maintained for the treatment of the superior longitudinal sinus thrombosis. Two days later, the patient developed a status epilepticus with new evidence of rebleeding. Anticoagulant treatment was stopped and the patient was transferred to the Intensive Care Unit. Activated partial thromboplastin

From the Stroke Centre, Department of Neurology, Division of Neuroimaging, La Paz University Hospital, Universidad Autónoma de Madrid, IdiPAZ Health Research Institute, Madrid, Spain.

The authors report no conflicts of interest.

Reprints: Exuperio Díez Tejedor, MD, PhD, Department of Neurology, Stroke Centre, La Paz University Hospital, Universidad Autónoma de Madrid, Paseo de la Castellana, 261, 28046 Madrid, Spain. E-mail: ediezt@meditex.es.

Copyright © 2011 by Lippincott Williams & Wilkins

ISSN: 1074-7931/11/1704-0208

DOI: 10.1097/NRL.0b013e31821a259b

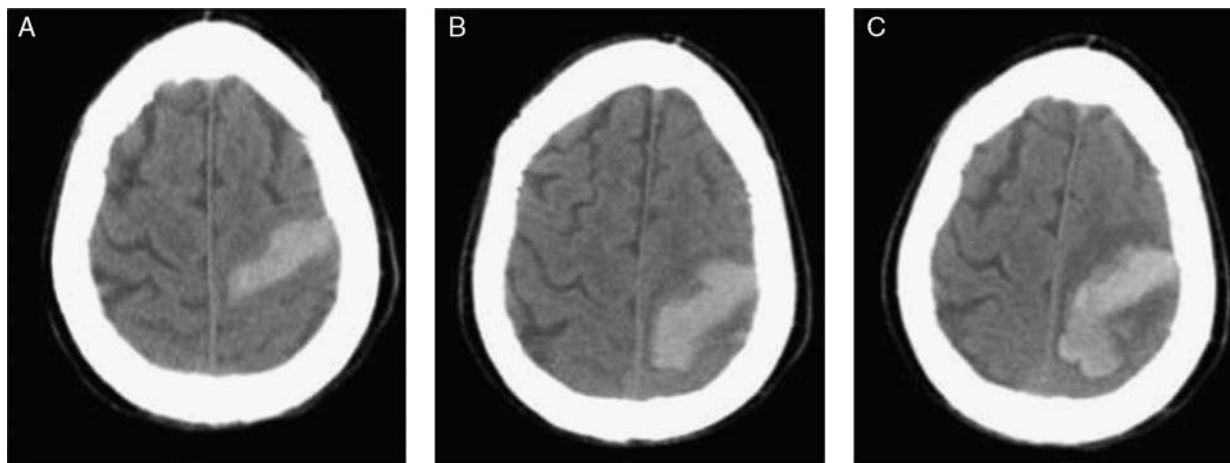


FIGURE 1. A, Cranial computed tomography (CT) on admission, showing left frontoparietal intracranial hemorrhage (ICH). B and C, Cranial CT at 24 and 72 hours after admission, showing the increased size of the ICH with surrounding edema.

time monitoring, carried out during the time the patient was on anticoagulants, was within the therapeutic range at all times. After heparin was stopped, the patient experienced progressive neurological improvement, with no new episodes of rebleeding.

DISCUSSION

The evidence for the safety and benefits of anticoagulant therapy in patients with CVST mainly comes from 2 small trials involving a total of 79 patients. The first examined the effectiveness of intravenous unfractionated heparin in patients with a confirmed diagnosis of CVST by intra-arterial contrast arteriography. Treatment with heparin was adjusted to maintain an activated partial thromboplastin time at least twice the value before treatment, up to 120 seconds. Although the target sample size was 60 patients, the trial was stopped prematurely after the inclusion of only 20 patients due to a statistically significant effect observed in patients treated with intravenous heparin. However, this study received some criticism because the principal outcome variable was a nonvalidated severity scale and the analysis of death or dependence failed to detect any significant differences between heparin and placebo.⁸ In this trial, 3 of the 10 patients assigned

to the anticoagulant treatment arm had some degree of bleeding in the CT before treatment. None of them presented with new symptomatic ICH, compared with 2 cases in the control group treated with placebo.⁹ Nevertheless, the conclusion that ICH was not a contraindication to heparin treatment was based on an additional retrospective study on the relationship between heparin treatment and ICH that included 43 patients with ICH, of whom 27 were treated with dose-adjusted intravenous heparin after the ICH.⁹

The second trial included 59 patients with confirmed diagnosis of CVST by conventional angiography or magnetic resonance imaging (including magnetic resonance angiography). The effectiveness of subcutaneous nadroparin for 10 weeks followed by oral warfarin for another 10 weeks was evaluated, compared with placebo, and the main variables of effectiveness were the Barthel Index and the Oxford Handicap Scale evaluated at 12 weeks of follow-up. Fifteen patients in the group treated with anticoagulation had some initial bleeding in the baseline brain CT, but there were no symptomatic intracranial bleeding complications.¹⁰

A meta-analysis that included data from these 2 studies suggested that in CVST patients, anticoagulant therapy was

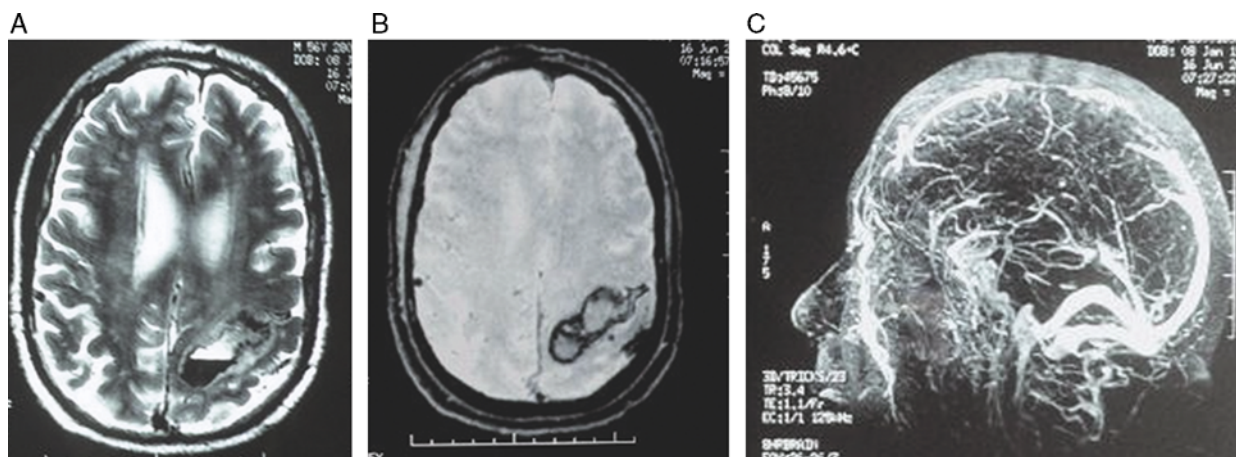


FIGURE 2. A and B, Cranial magnetic resonance (MR) images (axial T2-weighted, axial gradient-recalled echo sequence) Intracranial hemorrhage composed of a high-low-level intensity core and a peripheral rim of hypointensity. C, Maximum intensity projection image from contrast-enhanced MR venography shows filling defects due to a thrombus of the superior sagittal sinus.

associated with a “potentially” important reduction in the risk of death or dependence, but it did not reach statistical significance. Although it is suggested that this treatment “seemed to be safe” with a low risk of ICH, it was also acknowledged that 0% of symptomatic bleeding in 40 patients treated with heparin is associated with a 95% confidence level of 0% to 9%, so that an impact of up to 9% of new ICH cannot be ruled out.^{11,12}

“Pure” ICH is an uncommon complication in CVST, and the development of hemorrhagic transformation of a venous infarction is more frequent.¹³ Thus, it is possible that patients with early and large ICH as shown in the first brain imaging study were not included in those trials, and therefore, the results on the safety of anticoagulants cannot be extrapolated to all patients with associated ICH. In fact, it has been shown that patients with intracerebral hemorrhage on the admission CT/magnetic resonance imaging are less likely to be treated with intravenous heparin in clinical practice.^{1,14} In recent years, few studies have reported outcomes of patients with ICH secondary to CVST who were treated with anticoagulant drugs, and a publication bias for negative results cannot be ruled out. A small retrospective series including 7 heparin-treated patients with large (4 to 48 cc) ICH did not find recurrences or clinical deterioration.¹⁵ In contrast, a post hoc analysis of the International Study on Cerebral Vein and Dural Sinus Thrombosis showed that up to 27% of patients with early ICH (any ICH present on neuroimaging studies at the time if diagnosed with CVST) were not treated with therapeutic heparin based on the opinion of the treating physician. In addition, the bivariate comparison of early ICH patients with good or poor outcome at 6 months showed no differences for the use of heparin at therapeutic doses, and a logistic regression analysis could not identify a significant impact of heparin therapy on death or dependence at 6 months.⁴

Another aspect that has not been sufficiently evaluated is the time of starting anticoagulant treatment. It is possible that in patients with ICH secondary to CVST, the early administration of heparin may cause a greater risk of rebleeding due to the instability of the hemostasis in an edematous brain with active bleeding. Thus, delaying the onset of anticoagulation for a few days could prevent early rebleeding. In fact, the International Study on Cerebral Vein and Dural Sinus Thrombosis showed that in the group of patients with early ICH, there were no significant differences in outcome at 3 months between those who received heparin treatment within the first 24 hours after the diagnosis of CVST compared with those who were not treated with anticoagulants.⁴

Thus, the lack of definitive evidence of efficacy of heparin therapy in CVST and the concerns regarding its safety in patients with early ICH have led some researchers to suggest that anticoagulation may be harmful in patients with ICH associated with CVST.¹⁶

In conclusion, given that anticoagulants do not show statistically significant efficacy compared with placebo, as

noted in the Cochrane meta-analysis,¹¹ and as there is not enough evidence for the safety of anticoagulant therapy in patients with early ICH associated with CVST, the therapeutic decision must be individualized and made cautiously, and the rebleeding risk should be weighed, as in the case reported here. Further information regarding the safety and efficacy of anticoagulant therapy in this subgroup of CVST patients with early and large ICH is needed.

REFERENCES

1. Ferro JM, Correia M, Pontes C, et al. Cerebral Venous Thrombosis Portuguese Collaborative Study Group (Venoport). Cerebral vein and dural sinus thrombosis in Portugal: 1980-1998. *Cerebrovasc Dis*. 2001;11:177-182.
2. Breteau G, Mounier-Vehier F, Godefroy O, et al. Cerebral venous thrombosis 3-year clinical outcome in 55 consecutive patients. *J Neurol*. 2003;250:29-35.
3. Ferro JM, Canhao P, Stam J, et al. ISCVT Investigators. Prognosis of cerebral vein and dural sinus thrombosis: results of the International Study on Cerebral Vein and Dural Sinus Thrombosis (ISCVT). *Stroke*. 2004;35:664-670.
4. Giroit M, Ferro JM, Canhao P, et al. Predictors of outcome in patients with cerebral venous thrombosis and intracerebral hemorrhage. *Stroke*. 2007;38:337-342.
5. Wasay M, Nakshi R, Bobustuc G, et al. Cerebral venous thrombosis: analysis of a multicenter cohort from the United States. *J Stroke Cerebrovasc Dis*. 2008;17:49-54.
6. Einhäupl K, Boussier MG, de Bruijn SF, et al. EFNS guideline on the treatment of cerebral venous and sinus thrombosis. *Eur J Neurol*. 2006;13:553-559.
7. Alonso de Lecinana M, Egido JA. Management of cerebral infarction in the acute phase: ad hoc Editorial Committee of the Task Force on Cerebrovascular Diseases of SEN. *Neurologia*. 1998;13(suppl 3):13-23.
8. Einhäupl K, Stam J, Boussier MG, et al. EFNS guideline on the treatment of cerebral venous and sinus thrombosis in adult patients. *Eur J Neurol*. 2010;17:1229-1235.
9. Einhäupl KM, Villringer A, Meister W, et al. Heparin treatment in sinus venous thrombosis. *Lancet*. 1991;338:597-600.
10. de Bruijn SF, Stam J. Randomized, placebo-controlled trial of anticoagulant treatment with low-molecular-weight heparin for cerebral sinus thrombosis. *Stroke*. 1999;30:484-488.
11. Stam J, De Bruijn SF, DeVeber G. Anticoagulation for cerebral sinus thrombosis. *Cochrane Database Syst Rev*. 2002; CD002005.
12. Stam J, de Bruijn S, deVeber G. Anticoagulation for cerebral sinus thrombosis. *Stroke*. 2003;34:1054-1055.
13. Kalita J, Bansal V, Misra UK, et al. Intracerebral haemorrhage due to cerebral venous sinus thrombosis. *QJM*. 2008;101:247-249.
14. Ferro JM, Lopes GC, Rosas MJ, et al. Cerebral Venous Thrombosis Portuguese Collaborative Study Group. Do randomised clinical trials influence practice? The example of cerebral vein and dural sinus thrombosis. *J Neurol*. 2002;249:1595-1596.
15. Fink JN, McAuley DL. Safety of anticoagulation for cerebral venous thrombosis associated with intracerebral hematoma. *Neurology*. 2001;57:1138-1139.
16. Wasay M, Kamal AK. Anticoagulation in cerebral venous sinus thrombosis: are we treating ourselves? *Arch Neurol*. 2008;65: 985-987.