

CASE REPORT

Microangiopathy of the inner ear, deafness, and cochlear implantation in a patient with Susac syndrome

ALINE GOMES BITTENCOURT, ANDREA FELICE DOS SANTOS,
MARIA VALERIA SCHMIDT GOFFI-GOMEZ, KELLEN KUTSCHER,
ROBINSON KOJI TSUJI, RUBENS DE BRITO & RICARDO FERREIRA BENTO

Department of Otolaryngology, University of São Paulo School of Medicine, São Paulo, Brazil

Abstract

Conclusion: The cochlear implant was beneficial as an attempt to restore hearing and improve communication abilities in this patient with profound sensorineural hearing loss secondary to Susac syndrome. **Objective:** To report the audiological outcomes of cochlear implantation (CI) in a young woman with Susac syndrome after a 6-month follow-up period. Susac syndrome is a rare disorder. It is clinically characterized by a typical triad of sensorineural deafness, encephalopathy, and visual defect, due to microangiopathy involving the brain, inner ear, and retina. **Methods:** This was a retrospective review of a case at a tertiary referral center. After diagnosis, the patient was evaluated by a multidisciplinary team and received a cochlear implant in her right ear. **Results:** The patient achieved 100% open-set sentence recognition in noise conditions and 92% monosyllable and 68% medial consonant recognition in quiet conditions after 6 months of implant use. She reported the use of the telephone 3 months after activation.

Keywords: Encephalopathy, sensorineural hearing loss, retina, branch retinal artery occlusion, retinocochleocerebral vasculopathy

Introduction

Susac syndrome (SS) is a rare disorder involving microangiopathy of the brain, inner ear, and retina and was initially described in 1979 by Susac et al. [1]. It predominantly affects women between 30 and 40 years old. The classic triad of clinical symptoms includes acute or subacute encephalopathy, sensorineural hearing loss (SNHL), and branch retinal artery occlusion (BRAO) [2]. SS has also been called RED-M (retinopathy, encephalopathy, deafness-associated microangiopathy), SICRET (small infarcts of cochlear, retinal, and encephalic tissues), and retinocochleocerebral vasculopathy [3–5]. The cause and pathogenesis of this condition remain unknown. The course of the disease is usually self-limited and fluctuating; about 33% of patients may have residual cognitive, visual, and/or hearing disability [2,6].

So far, two cases of SS involving cochlear implantation (CI) have been reported in the literature [3,7]. We report the audiological outcomes of CI in a young woman with profound SNHL secondary to SS after a 6-month follow-up period.

Case report

A 20-year-old woman with a complaint of a 4-year history of decreased hearing associated with bilateral tinnitus was admitted into the CI evaluation process. She had been using hearing aids for the past 2 years, with limited ability to hear speech. Audiological examination revealed poor word recognition and bilateral profound SNHL. Auditory brainstem response and otoacoustic emissions could not be elicited.

The onset of neurological symptoms started with isolated seizures when the patient was 4 years old.

Correspondence: Dra Aline Gomes Bittencourt, Department of Otolaryngology, Hospital das Clínicas, University of São Paulo, Av. Dr Enéas de Carvalho Aguiar, 255, 6° andar/sala 6167, CEP: 05403-000, São Paulo/SP, Brasil. Fax: + 55 11 3088 0299. E-mail: alinebittencourt@hotmail.com

(Received 3 April 2011; accepted 22 May 2011)

ISSN 0001-6489 print/ISSN 1651-2251 online © 2011 Informa Healthcare
DOI: 10.3109/00016489.2011.593549

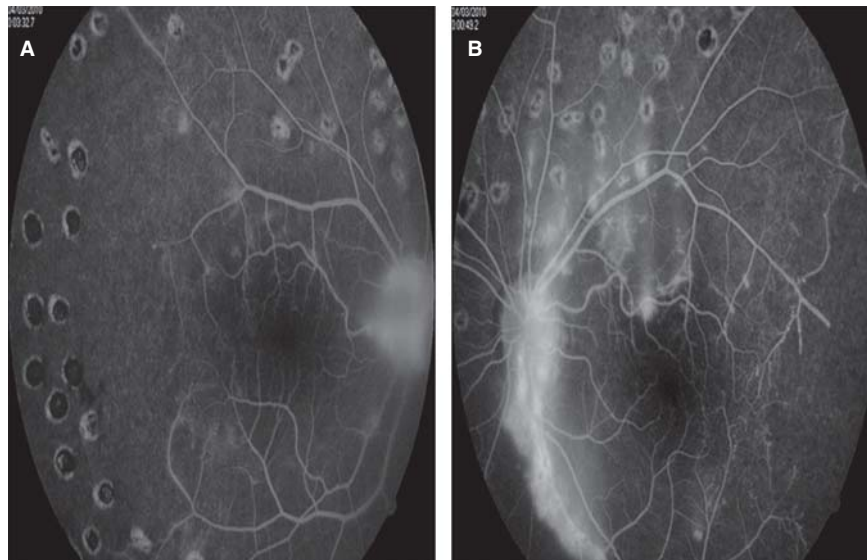


Figure 1. Fluorescein angiography of the right (A) and left (B) eyes shows occlusions of the retinal artery branch.

By the age of 15 years (2005), she developed visual hallucinations followed by loss of consciousness and falling.

Concomitantly, she presented hypoesthesia over the L2–L4 dermatomes and chronic headache, accompanied by photophobia, nausea, vomiting, and vertigo. The hearing loss in the left ear was initially progressive; 20 days later, the right ear was affected by sudden deafness. Her electroencephalogram showed paroxysms and irregular slow waves in the projection of the left hemisphere, in the temporal region. On that occasion, her psychological examination demonstrated a depressive personality.

In 2008, she experienced blurred vision in the left eye and, subsequently, visual deficit in the right eye.

On ophthalmologic examination, visual acuity was 20/20 in the left eye and 20/50 in the right eye. Fundoscopic examination revealed the proliferation of blood vessels, and retinal panphotocoagulation was performed for the regression of the neovascularization. BRAO was well documented by fluorescein angiography (Figure 1). Partial improvement was achieved after treatment with cyclophosphamide and methylprednisolone pulses.

Laboratory evaluations were normal, including blood cell count, C-reactive protein, coagulation profile, and serology for infective agents and autoimmune diseases. Following a lumbar puncture, a cerebrospinal fluid (CSF) study revealed elevated erythrocyte count and increased protein level. Brain magnetic

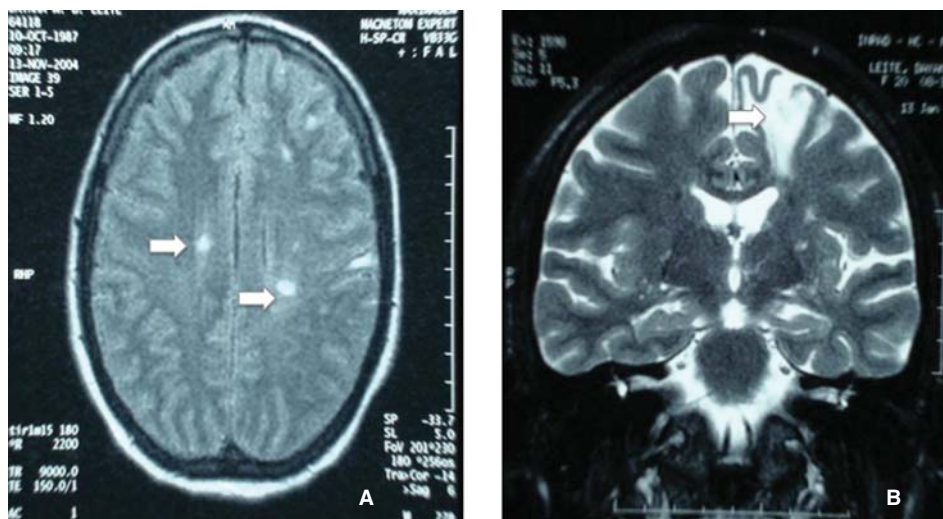


Figure 2. (A) Axial T1-enhanced brain MRI: retractable ischemic lesions in the region of the left pericallosum artery. (B) Coronal T2 brain MRI: hyperintense foci in the bilateral frontoparietal subcortical white matter, these are more frequent and extensive on the left side.

	250Hz	500Hz	1KHz	2KHz	3KHz	4KHz	6KHz	8KHz
Right ear	95dB	120dB	120dB	Absent	Absent	Absent	Absent	Absent
Left ear	105dB	120dB	120dB	Absent	Absent	Absent	Absent	Absent

Figure 3. Hearing thresholds before CI.

resonance imaging (MRI) on T2 sequences demonstrated multifocal hyperintense lesions in both the gray and white matter, which are pathognomonic for SS (Figure 2).

The patient maintained severe auditory deficits, moderate visual field defects, and no neuropsychological sequelae. In 2009, the patient received a Nucleus Freedom Contour Advance device (Cochlear Ltd, Lane Cove, Australia) in her left ear. The implant’s magnet was removed intraoperatively and replaced with a nonmagnetic plug to allow successive MRI. The electrodes were fully inserted, and there were no postoperative complications.

Results

The device was activated 30 days after the surgery, with a Freedom speech processor and adhesive magnets allowing perfect transmission between the coil and the implant. The patient was programmed with the advanced combination encoder strategy, at 900 Hz and eight maxima with the ADRO preprocessing strategy.

Aided hearing thresholds in the implanted ear before CI were around 115 dB HL (Figure 3) and, after 3 months of CI use, approximately 20 dB HL (Figure 4). Speech perception results were based on the center protocol [8], including open-set speech tests presented at 65 dB SPL. Results after 6 months of implant use showed 100% sentence recognition in quiet and in noise (signal-to-noise ratio = 0 dB), as well as 92% monosyllable and 68% medial consonant recognition. The patient reported the use of the telephone and an appreciation of music 3 months after activation.

	250Hz	500Hz	1KHz	2KHz	3KHz	4KHz	6KHz	8KHz
Left ear	15dB	25dB	25dB	15dB	30dB	20dB	20dB	55dB

Figure 4. Aided hearing thresholds in the implanted ear after CI.

Intraoperatively electrically evoked compound action potential was recorded through neural response telemetry (NRT) with Custom Sound EP® software. Impedances were adequate and homogeneous in both the intraoperative and postoperative sessions. Adequate and homogeneous NRT thresholds were found along all 11 tested electrodes in the intraoperative session. Thresholds were registered around 186 current units in the apical, medial, and basal regions. Figure 5 shows the amplitude of the basal and apex electrodes in the intraoperative and postoperative sessions. Although thresholds were similar throughout the array, it seems that the threshold amplitude of neural response was higher at the base in the postoperative session. Figure 6 shows the recovery and spread of excitation functions of electrode 20, tested in the intraoperative session, when it showed adequate conduction and selectivity of the stimulation. The saturation level (Figure 6A) was 331.78 µV; the absolute refractory period (t0) and curviness parameter for the model function (tau) were 304.93 µs and 789.34 µs, respectively.

Discussion

The course of this disorder is variable. Patients with SS usually take from a few weeks to 2 years to exhibit the complete clinical triad of symptoms, and only 3% show all the features at the onset [4,9]. Most cases seem to stabilize without additional attacks after 2 years [4,10,11]. In 75% of cases, SS begins with neuropsychiatric disorders, either alone or associated with visual and/or hearing symptoms [5]. Acute or subacute encephalopathy is demonstrated by cognitive dysfunction (memory loss, confusion, and/or

Acta Otolaryngol Downloaded from informahealthcare.com by Nyu Medical Center on 01/12/15
For personal use only.

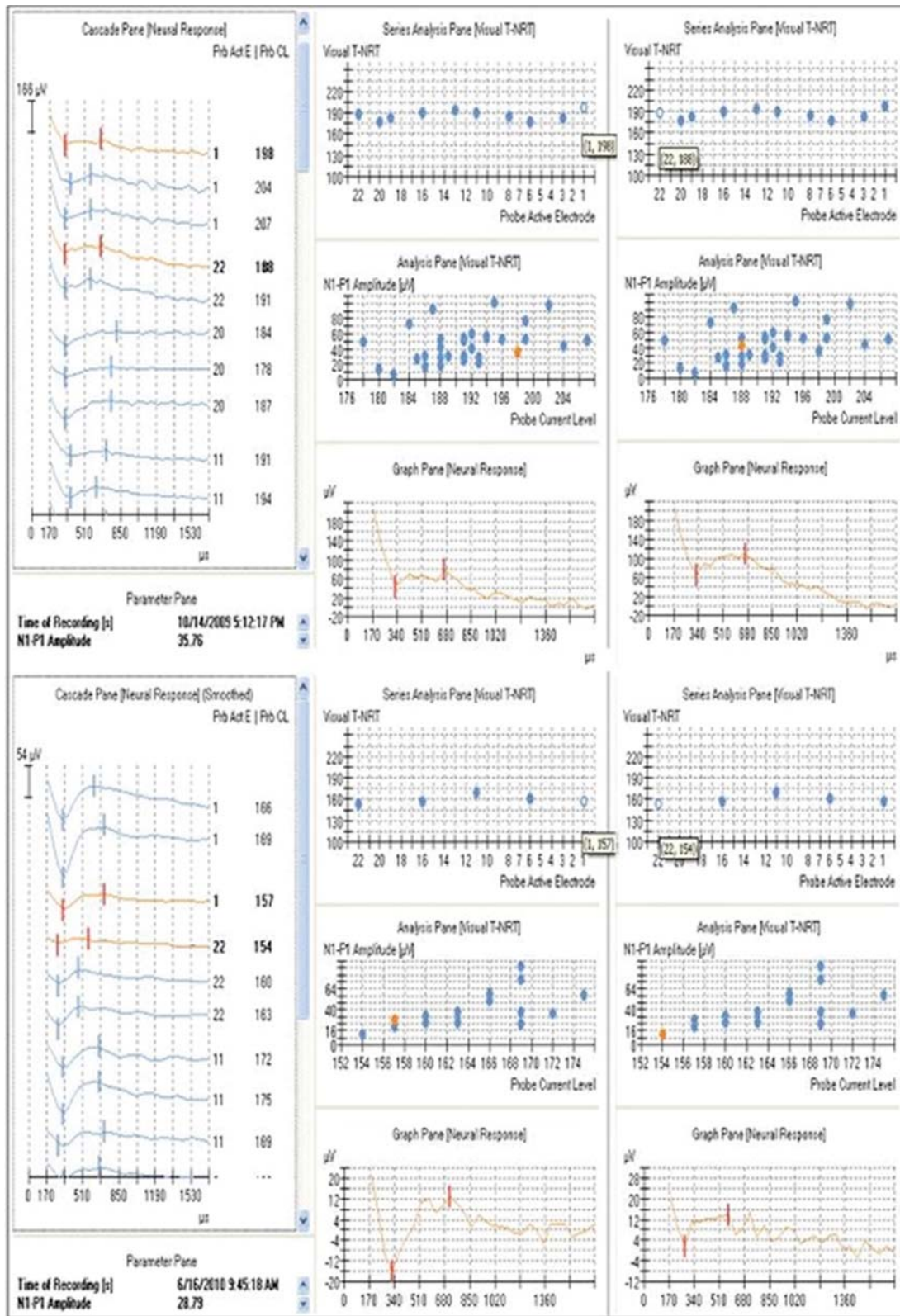


Figure 5. Intraoperative (top) and postoperative (bottom) amplitude growth function of the neural response telemetry (NRT). (A) Amplitude (calculated threshold) on electrode 1 and (B) amplitude (calculated threshold) on electrode 22 (calculated threshold).

Acta Otolaryngol Downloaded from informahealthcare.com by Nyu Medical Center on 01/12/15
For personal use only.

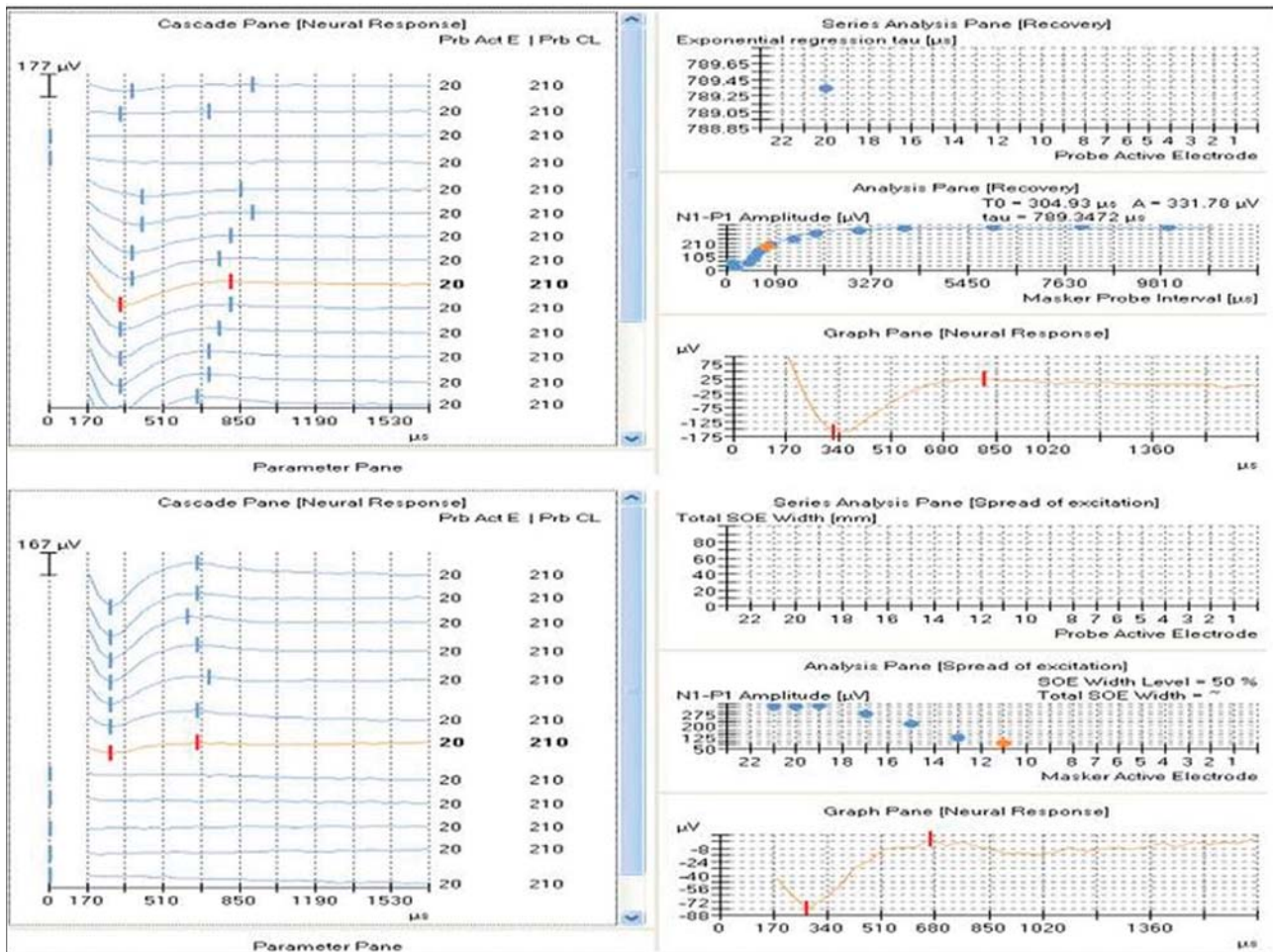


Figure 6. Intraoperative recovery function (A) and spread of excitation function (B) of the neural response telemetry (NRT). Given that the intraoperative threshold at electrode 20 was 178 current units, both functions performed 32 current units above threshold.

dementia), ataxia, diplopia, nystagmus, dysarthria, dysmetria, seizures, or corticospinal tract dysfunction [12]. Personality change and bizarre behavior may also appear. Headache is a common prodromal symptom that can precede encephalopathy by several months and is usually migraine-like [4,11,13,14]. During the encephalopathic phase, electroencephalograms usually show diffuse slowing [4,10,14]. CSF invariably shows an elevated protein count with different degrees of lymphocytic pleocytosis [5,13,14]. This usually returns to normal after the acute phase [2,6]. The associated retinopathy is usually characterized by a sudden onset of impaired vision [10]. Small peripheral arteriolar occlusions can be asymptomatic and not detected on a fundoscopic exam [6]. Retinal fluorescein angiography may show the BRAO and the pathognomonic multifocal fluorescence of the branch arterioles [4,13]. Our patient presented occlusions of some retinal veins, which is unusual [4,9].

Inner ear involvement is demonstrated by a bilateral, asymmetric SNHL on pure-tone audiometry

tests (typically at low and medium frequencies) and/or by decreased vestibular responses in caloric tests [3,4,13]. The cochlear involvement has been attributed to infarction of the cochlear apex region supplied by end arterioles [8,13,14]. Confirming this idea, Figure 5 shows that although NRT thresholds were similar throughout the array, the threshold amplitudes of neural response were higher at the base, probably due to a higher number of ganglion cells. Nevertheless, the recovery and spread of the excitation functions of electrode 20 in the intraoperative session showed adequate conduction and selectivity of the stimulation, even in the apical region. A prominent jerk nystagmus may be present and is probably related to microinfarction of the membranous labyrinth. Tinnitus, vertigo, unsteady gait, nausea, and vomiting are also common symptoms [10,11]. Petty et al. mentioned that auditory brainstem evoked responses are variable [9], which might be due to the degree of hearing loss. However, Connell and Brodie reported that otoacoustic

emissions were present in their case [7], suggesting an auditory neuropathy spectrum disorder [15]. On the other hand, Roeser et al. did not mention this aspect as part of audiological diagnosis or management [3]. The presence of robust NRT in our case suggests good synchrony because evoked action potentials could be elicited both intraoperatively and postoperatively.

The T2-weighted MRI sequences of our patient demonstrated multifocal hyperintense lesions (Figure 2). They may appear during the acute encephalopathy of SS, as numerous small hyperintense foci on T2-weighted images in the white (more prominent) and gray matter. These lesions may appear on T1-weighted images as hypointense areas during the subacute or late phases of the disease. There is a predilection for corpus callosum involvement, and the brainstem and cerebellum are habitually involved [3,10]. The parenchymal lesions or leptomeninges may show enhancement on contrast material [10,13].

Brain biopsy has been performed in some cases [1,10]. It was clear that the disease was characterized by microinfarctions, but the nature of the arteriolar occlusion was not further defined [9,14].

Laboratory testing does not reveal any evidence of a collagen vascular disease, procoagulant state, autoimmune disturbance, or infectious disease [2,13,14]. The evaluations of our patient were normal, including blood cell count, C-reactive protein, coagulation profile, and serology for infective agents and autoimmune diseases. Patients with this syndrome are commonly misdiagnosed, and the differential diagnosis includes multiple sclerosis, lupus erythematosus, disseminated encephalitis, Ménière's disease, migraine, and thromboembolic strokes [10,11].

Two reported cases of bilateral hearing impairment because of SS have undergone CI [3,7]. The SNHL is initially managed with hearing aids. CI may be considered as a viable auditory rehabilitation method when the SNHL progresses to a profound level and the patient no longer experiences substantial improvement from appropriate amplification aids. Connell and Brodie reported on a patient with SS whose hearing improved after 6 months of CI; noise testing results changed from 0% to 94% correct answers, and word recognition results changed from 0% to 76% at 60 dB [7]. Roeser et al. described significant hearing restoration after a successful bilateral CI in a patient with SS [3]. Our case showed similar results, with 100% open-set sentence recognition in noise conditions and 92% monosyllable recognition in quiet conditions.

In this case of SS, the implant provided many benefits in restoring hearing and improving communication abilities.

Declaration of interest: The authors report no conflicts of interest. The authors alone are responsible for the content and writing of the paper.

References

- [1] Susac JO, Hardman JM, Selhorst JB. Microangiopathy of the brain and retina. *Neurology* 1979;29:313–16.
- [2] Susac JO. Susac's syndrome. *Am J Neuroradiol* 2004;25:351–2.
- [3] Roeser MM, Driscoll CL, Shallop JK, Gifford RH, Kasperbauer JL, Gluth MB. Susac syndrome – a report of cochlear implantation and review of otologic manifestations in twenty-three patients. *Otol Neurotol* 2008;30:34–40.
- [4] Saw VP, Canty PA, Green CM, Briggs RJ, Cremer PD, Harrisberg B, et al. Susac syndrome: microangiopathy of the retina, cochlea, and brain. *Clin Exp Ophthalmol* 2000;28:373–81.
- [5] Ayache D, Plouin-Gaudon I, Bakouche P, Elbaz P, Gout O. Microangiopathy of the inner ear, retina, and brain (Susac syndrome): report of a case. *Arch Otolaryngol Head Neck Surg* 2000;126:82–4.
- [6] Gross M, Banin E, Eliashar R, Ben-Hur T. Susac syndrome. *Otol Neurotol* 2004;470–3.
- [7] Connell SS, Brodie HA. Role of cochlear implantation in Susac's syndrome. *Otolaryngol Head Neck Surg* 2004;131:P280.
- [8] Goffi-Gomez MVS, Guedes MC, Sant'Anna SGB, Peralta CGO, Tsuji RK, Castilho AM, et al. Critérios de seleção e avaliação médica e audiológica dos candidatos ao implante coclear: Protocolo HCFMUSP. *Arq Otorrinolaringol* 2004;7:197–204.
- [9] Petty GW, Matteson EL, Younge BR, McDonald TJ, Wood CP. Recurrence of Susac syndrome (Retinocochleocerebral vasculopathy) after remission of 18 years. *Mayo Clin Proc* 2001;76:958–60.
- [10] Hahn JS, Lannin WC, Sarwal MM. Microangiopathy of brain, retina, and inner ear (Susac's syndrome) in an adolescent female presenting as acute disseminated encephalomyelitis. *Pediatrics* 2004;114:276–81.
- [11] Do TH, Fisch C, Evoy F. Susac syndrome: report of four cases and review of the literature. *Am J Neuroradiol* 2004;25:382–8.
- [12] Crawley BK, Close A, Canto C, Harris JP. Susac's syndrome: intratympanic therapy for hearing loss and a review of the literature. *Laryngoscope* 2009;119:141–4.
- [13] Demir MK. Case 142: Susac syndrome. *Radiology* 2009;250:598–602.
- [14] Maddestra M, Sabatini S, Paci A. Encephalopathy, hearing loss, and retinal occlusions (Susac's syndrome): a new case. *Ital J Neurol Sci* 1998;9:225–7.
- [15] Berlin CI, Hood LJ, Morlet T, Wilensky D, Li L, Mattingley KR, et al. Multi-site diagnosis and management of 260 patients with auditory neuropathy/dys-synchrony auditory neuropathy spectrum disorder. *Int J Audiol* 2010;49:30–43.