

Dissecting aneurysm of the middle cerebral artery treated with heparin infusion in a 6-year-old child; neurological recovery with delayed spontaneous thrombosis: case illustration and literature review

G. Anichini · E. Passacantilli · J. Lenzi ·
G. Guidetti · A. Santoro

Received: 22 May 2011 / Accepted: 5 July 2011 / Published online: 16 July 2011
© Springer-Verlag 2011

Abstract Aneurysms in the pediatric population are a rare pathology with specific features which requires a deep knowledge of their pathogenesis for the best therapeutic choice; the authors report their experience with a patient presenting aneurysm of the middle cerebral artery (MCA) associated with proximal stenosis of the vessel. A six-year-old girl came to our observation after sudden onset of headache and left hemiparesis. Angio-MRI and angio-CT scan showed a right MCA dissecting aneurysms associated with proximal stenosis of the vessel. Patient started a therapy with low molecular weight heparin (LMWH), replaced, 15 days later, with acetyl-salicylic acid (ASA). Patient showed a rapid and almost complete neurological recovery, despite several radiological exams confirmed a complete occlusion of the right MCA. As many other authors noted, dissecting aneurysms in the pediatric population are probably due to a defect of the entire arterial wall. Combination of stenosis, turbulence and partial thrombosis of the aneurysm led to a complete occlusion of artery involved, leading to the formation of collateral circles. In our case, complete thrombosis was probably delayed with anticoagulant therapy and the progressive

reinforcement of collateral circles lead to the patient's neurological recovery.

Keywords Pediatric aneurysm · Fusiform aneurysm · Aneurysm thrombosis · Low-molecular weight heparin

Introduction

Aneurysms in childhood are a rare pathology; incidence is estimated between 0.5 and 5% [1–3]. Many studies have been published about their pathogenesis, but risk factors are still a matter of discussion; although some of the authors consider them as a congenital disease [4, 5], it has been suggested that various vessel wall dysfunctions can result in a failure to repair insults; subsequently, associated conditions (infections, traumas, etc.), which act on the vessel structural defect, lead to the formation of the aneurysm [6, 7]. On the basis of aetiology and morphological features, four groups of paediatric aneurysms can be identified: dissecting, infectious, traumatic and saccular aneurysms [6, 7].

Dissecting aneurysms (fusiform aneurysms) are relatively more common in the paediatric population and show several differences when compared with the adult ones; they are often found in the posterior circulation and are associated with proximal or distal stenosis of the artery involved; spontaneous thrombosis of the aneurysm can cause a complete occlusion of the artery, with the possibility of neurological deficits. We report the case of a six-year-old girl with a right middle cerebral artery (MCA) dissecting aneurysm and acute onset of hemiparesis, treated in emergency with low molecular weight heparin (LMWH) infusion, who presented neurological recovery and secondary complete occlusion of the vessel.

G. Anichini · E. Passacantilli (✉) · J. Lenzi · A. Santoro
Department of Neurological Sciences, Neurosurgery,
University of Rome “Sapienza”, Viale Giacinta Pezzana 92,
00197 Rome, Italy
e-mail: e.passacantilli@gmail.com

G. Guidetti
Department of Neurological Sciences, Neuroradiology,
University of Rome “Sapienza”, Rome, Italy

Case report

A six-year-old girl was admitted to emergency department with acute onset of headache, asthenia and left hemiparesis; her vital signs were normal. Strength on the left side of the body was 2/5. No previous pathologies were referred by her parents; her blood exams were normal.

CT scans showed a small hyperdense spot located in the middle portion of the right Sylvian fissure (Fig. 1a). A contrast enhanced MRI scan confirmed a hypointense image in T2-weighted, fast field echo (FFE) and in T1-weighted images, without any enhancement after gadolinium injection; DWI images also revealed a hyperintense area (hypointense on ADC sequences) in right basal ganglia, which was suspected to be an oncoming ischemic lesion on right MCA territory (Fig. 1b, c). Angio-MRI showed a dissecting aneurysm of the M1 segment of the right MCA and a reduction of caliber of the artery proximal to the aneurysm (Fig. 1d), associated with a stenosis of the right middle cerebral artery (MCA) along its M1 segment.

Therapy started with infusion of 1,100 UI of LMWH in bolo, followed by an intravenous infusion of 500 UI of LMWH for 1 h. After 12 h, the patient's neurological conditions started to improve, showing mild regression of her hemiparesis. After 3 days, a CT and angio-CT scan confirmed the presence of a right M1 dissecting aneurysm associated with proximal stenosis of the artery (Fig. 1e). After 15 days, the patient started to assume oral therapy with 25 mg of acetyl-salicylic acid (ASA) for a month. One and three months later, several angio-MRI scans revealed a complete occlusion of the right MCA (Fig. 1f), but physical examination revealed complete regressions of the neurological symptoms (upper arm strength 4/5). After 3 years of follow-up, the patient presents slight hemiparesis (4/5).

Discussion

Aneurysms in childhood are rare; their prevalence is estimated around 0.5–5% in most of the series [1–3, 8], with an

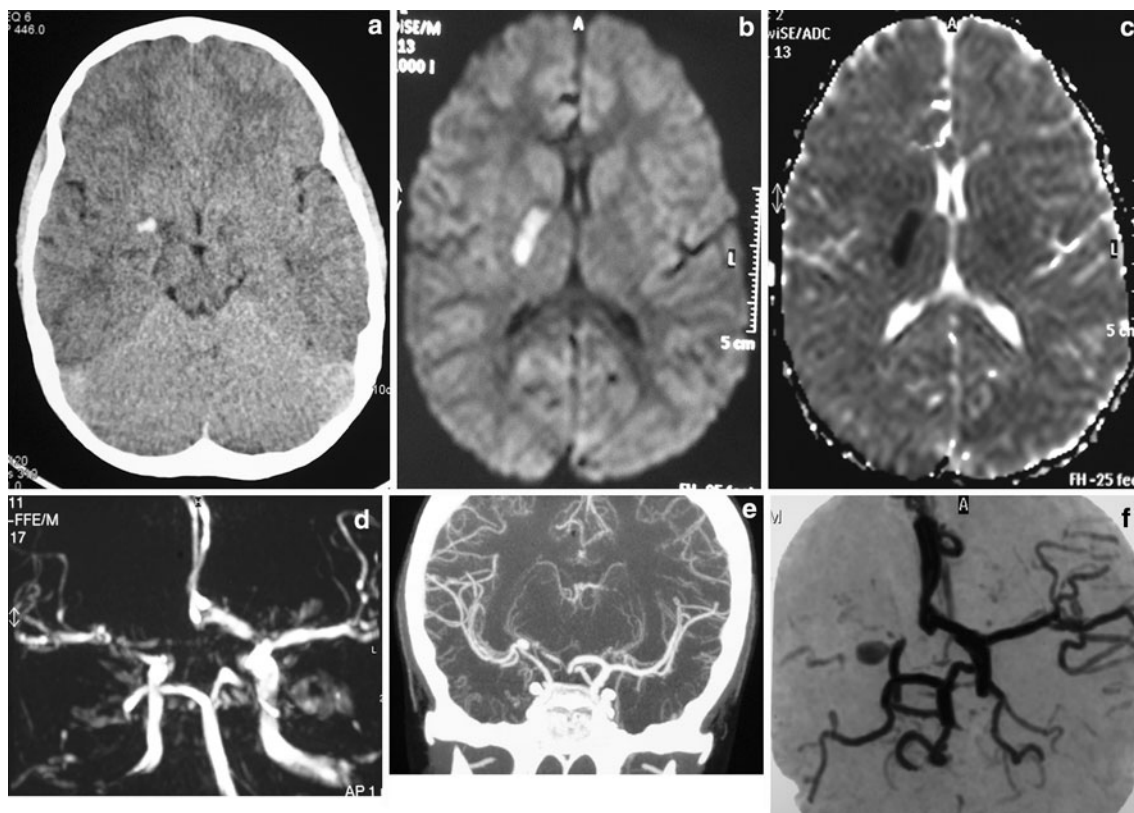


Fig. 1 a CT scan performed in emergency room after 6 h from symptoms onset (right hemiparesis 2/5); hyperdense image on the right MCA; b brain MRI showing ischemic area, hyperintense on DWI sequences; c brain MRI—ADC sequences; d angio-MRI after the hospitalization showing aneurysm of the MCA with associated stenosis of the vessel; patient started LMWH infusion (right

hemiparesis 2/5); e angioCT scan performed 3 days after the admission; dissecting aneurysm of the right MCA with stenosis of the afferent vessel; f angio-MRI after 3 months: complete occlusion of the right MCA; patient under antiplatelet therapy (right hemiparesis 4/5)

overall average of 1.5% of total intracranial aneurysms treated [9, 10]. Approximately, each neurosurgical center treats one pediatric aneurysm per year; male dominance is reported almost in all the series, although rates vary widely [8–10].

Aneurysms in children show many characteristic features which are markedly different from those of the adult age, both in terms of pathogenesis and clinical aspects. As reported in the literature, the most common localizations are the internal carotid artery (ICA) bifurcation (25–50%), followed by the posterior circulation, mainly posterior cerebral artery (PCA), basilar artery (BA) and vertebral artery (VA); middle cerebral artery (MCA) and anterior cerebral artery (ACA) are less frequent but are possible sites [8, 9, 12, 13]. Lasjaunias et al. suggested that paediatric aneurysms can be divided into four main groups:

- dissecting aneurysms: large fusiform and with partial thrombosis;
- infectious aneurysms: usually found in distal vessels and associated with a history of septic emboli;
- traumatic aneurysm: secondary to an important trauma;
- saccular aneurysm: in the same location as aneurysms in adults, the majority located in the anterior circulation.

Several series are reported in the literature regarding the treatment of paediatric aneurysms [6, 7]. The endovascular option is usually preferred but hard to obtain; Proust et al. [3] reported a series of 22 patients, with a good outcome in 64% of the cases, while recent works are even more encouraging [8, 14, 15]. However, surgical treatment is mandatory in all the cases in which embolization fails or balloon occlusion test of the afferent vessel is impracticable; surgery with direct clipping, trapping and, in selected cases, even extra-intracranial by-pass have shown good results in all the recent series [8, 9, 11, 16, 17].

Our case is attributed to the group of dissecting (fusiform) aneurysms. Parents referred no history of trauma or previous pathologies; however, in order to exclude a septic or immunological pathogenesis, radiological investigations (echocardiography and chest radiography) and complete blood analysis including inflammation markers were performed, without significant findings. These specific kind of aneurysms are notoriously difficult to manage, mainly owing to the anatomical features of the sac and its relationship with nervous and vascular structures. Endovascular occlusion with stents can be considered, but long-term follow-up data are not still available. Options for surgical treatment can be summarized as follows: trapping of the sac, occlusion of the parent vessel, wrapping of the sac and conservative management. The ideal solution, clipping of the aneurysm, is rarely feasible, due to the absence of a neck, the calcified wall and the presence of perforating

arteries. Moreover, occlusion of the parent artery (M1, in this case) or Hunterian ligation presents a relatively high risk of neurological deficits [8, 11, 18].

On the other hand, dissecting/fusiform aneurysms display particular features that challenge traditional pathogenetic and therapeutic assumptions. As Lasjaunias et al. [6, 7] noted that these aneurysms are associated with proximal or distal stenosis of the parent vessel, an aspect which suggests a mural dysfunction. As in our case, a combination of stenosis, turbulence and partial thrombosis of the aneurysm led to a complete occlusion of artery involved, a phenomenon that has been described in several cases [6–8]. Although complete occlusion of the artery is usually well tolerated in these patients mostly due to the presence of anastomoses through the circle of Willis and/or sub-pial collateral circles which are well developed in children [6]. In our case, we opted for a conservative approach consisting of therapy with 1100 IU of LMWH followed, 15 days later, by ASA 100 mg ¼ cpr per os. Despite this therapy, the parent vessel showed a complete occlusion that was confirmed by angio-MRI scan, even though the patient's neurological hemiparesis gradually resolved.

On the basis of these considerations, we can presume that anticoagulant and/or anti-platelet therapy can delay complete thrombosis and support the advent of compensatory collateral circulation. Anticoagulant therapy with heparin infusion may represent an effective therapeutic approach for the treatment of pediatric fusiform aneurysms.

Acknowledgments The authors would like to thank Mrs. Sharon Hobby for the precious help during the revision of the present manuscript.

References

1. Locksley HB (1966) Natural history of subarachnoid hemorrhage, intracranial aneurysms and arteriovenous malformations. Based on 6368 cases in the cooperative study. *J Neurosurg* 25:219–239
2. Norris JS, Wallace MC (1998) Pediatric intracranial aneurysms. *Neurosurg Clin N Am* 9:557–563
3. Proust F, Toussaint P, Garnieri J et al (2001) Pediatric cerebral aneurysms. *J Neurosurg* 94:733–739
4. Agid R, Souza MP, Reintamm G et al (2005) The role of endovascular treatment for pediatric aneurysms. *Childs Nerv Syst* 21:1030–1036
5. Allison JW, Davis PC, Sato Y et al (1998) Intracranial aneurysms in infants and children. *Pediatr Radiol* 28:223–229
6. Lasjaunias P, Wuppalapati S, Alvarez H, Rodesch G, Ozanne A (2005) Intracranial aneurysms in children aged under 15 years: review of 59 consecutive children with 75 aneurysms. *Childs Nerv Syst* 21(6):437–450
7. Krings T, Geibprasert S, Ter Brugge KG (2010) Pathomechanisms and treatment of pediatric aneurysms. *Childs Nerv Syst* 26(10):1309–1318
8. Liang J, Bao Y, Zhang H et al (2009) The clinical features and treatment of pediatric intracranial aneurysm. *Childs Nerv Syst* 25(3):317–324

9. Huang J, McGirt MJ, Gailloud P, Tamargo RJ (2005) Intracranial aneurysms in the pediatric population: case series and literature review. *Surg Neurol* 63(5):424–432
10. Meyer FB, Sundt TM Jr, Fode NC et al (1989) Cerebral aneurysms in childhood and adolescence. *J Neurosurg* 70:420–425
11. Sharma BS, Sinha S, Mehta VS et al (2007) Pediatric intracranial aneurysms-clinical characteristics and outcome of surgical treatment. *Childs Nerv Syst* 23(3):327–333
12. Menon G, Furtado SV, Nair S (2005) Intracranial arterial aneurysms in children and adolescents. *Indian J Cerebrovasc Surg* 1:80–84
13. Vaid VK, Kumar R, Kalra SK, Mahapatra AK, Jain VK (2008) Pediatric intracranial aneurysms: an institutional experience. *Pediatr Neurosurg* 44:296–301
14. Fulkerson DH, Voorhies JM, McCanna SP et al (2010) Endovascular treatment and radiographic follow-up of proximal traumatic intracranial aneurysms in adolescents: case series and review of the literature. *Childs Nerv Syst* 26(5):613–620
15. Tai YP, Chou IC, Yang MS et al (2010) Neonatal intracranial aneurysm rupture treated by endovascular management: a case report. *Pediatr Neonatol* 51(4):249–251
16. Krishna H, Wani AA, Behari S et al (2005) Intracranial aneurysms in patients 18 years of age or under, are they different from aneurysms in adult population? *Acta Neurochir (Wien)* 147(5):469–476
17. Zhang YJ, Barrow DL, Day AL (2002) Extracranial-intracranial vein graft bypass for giant intracranial aneurysm surgery for pediatric patients: two technical case reports. *Neurosurgery* 50:663–668
18. Drake CG, Peerless SJ (1997) Giant fusiform intracranial aneurysms: review of 120 patients treated surgically from 1965 to 1992. *J Neurosurg* 87(2):141–162