

Images in Cardiovascular Medicine

Right Hemiparesis in Right Carotid Stenosis

P. Profice, MD; F. Pilato, MD; A. Broccolini, MD; A. Santoliquido, MD;
G. Della Marca, MD; V. Di Lazzaro, MD

A 72-year-old right-handed man with a history of hypertension and past smoking, taking low-dose aspirin therapy (100 mg once a day) for cardiovascular prevention, presented with sudden onset of right hemiparesis and confusion. The right hemiparesis improved during the following days, but the patient was still confused.

He arrived at the emergency department 6 days after the onset of symptoms. On neurological examination, the patient showed mild disorientation both in time and in place; no other neurological signs could be elicited. Blood pressure was 160/90 mm Hg. Blood count, prothrombin time, activated thromboplastin time, ionogram, C-reactive

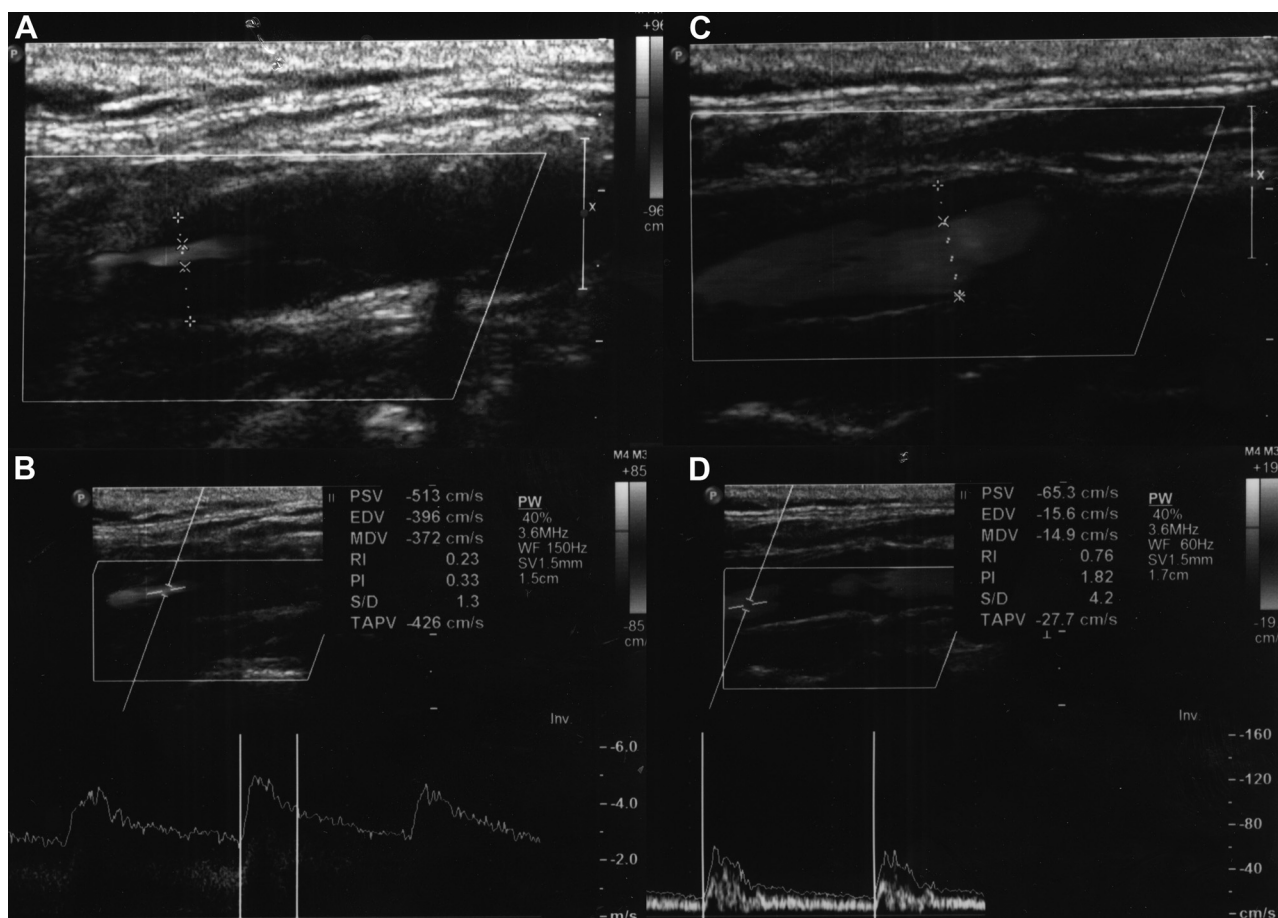


Figure 1. Ultrasound (2-dimensional) images of left (A) and right (C) internal carotid arteries (ICAs) and Doppler waveforms of left (B) and right (D) ICAs showing severe stenosis and increased peak systolic velocity (513 cm/s) of the left ICA and normal peak systolic velocity (65.3 cm/s) of the right ICA.

From the Institute of Neurology (P.P., F.P., A.B., G.D.M., V.D.L.) and Department of Internal Medicine (A.S.), Università Cattolica, Rome, Italy; and Department of Neuroscience, AFaR-Fatebenefratelli Association for Biomedical Research, “San Giovanni Calibita-Fatebenefratelli” Hospital, Isola Tiberina, Rome, Italy (V.D.L.).

Correspondence to Vincenzo Di Lazzaro, Istituto di Neurologia, Università Cattolica, L.go A. Gemelli 8, 00168 Rome, Italy. E-mail vdilazzaro@rm.unicatt.it

(*Circulation*. 2011;124:360-362.)

© 2011 American Heart Association, Inc.

Circulation is available at <http://circ.ahajournals.org>

DOI: 10.1161/CIRCULATIONAHA.110.991372

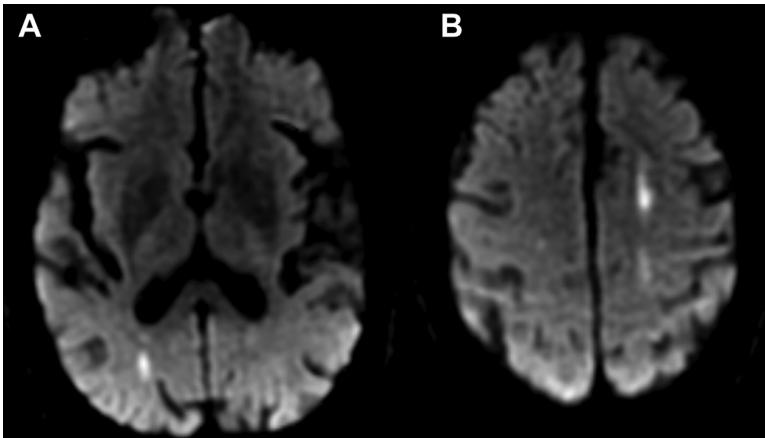


Figure 2. Diffusion-weighted magnetic resonance imaging showing acute watershed infarcts in right (A) and left (B) hemispheres.

protein, troponin Ic, and creatine kinase were normal. ECG revealed normal sinus rhythm (76 bpm). Extracranial carotid and vertebral arteries eco-color-doppler showed >80% stenosis of the proximal right internal carotid artery (ICA) and no significant stenosis of the left ICA (Figure 1A through D). Diffusion-weighted magnetic resonance imaging of the brain showed bilateral acute border-zone ischemic lesions suggesting watershed infarcts (Figure 2A and B). Magnetic resonance time-of-flight angiogram of intracranial arteries showed agenesis of left A1 segment of the anterior cerebral artery (Figure 3A), with left A2 segment arising from the anterior communicating artery. Contrast-enhanced magnetic resonance angiogram of the neck confirms the right ICA stenosis (Figure 3B). The patient was treated with clopidogrel and atorvastatin and underwent right ICA endoarterectomy successfully after 15 days.

Discussion

Knowledge of the presence and clinical relevance of variation of circle of Willis plays a crucial role in the diagnosis and management of acute stroke. The neurological symptoms can be influenced by changes in normal brain-vessel anatomy. Anatomic variation of circle of

Willis is not uncommon: It has been reported that only 42% of subjects showed a complete circle of Willis on magnetic resonance angiogram.¹

It has been reported in magnetic resonance angiogram studies that the A1 segment can be absent in >5% of subjects,¹ and it has been suggested that this condition can be a significant predisposing factor for bilateral anterior cerebral artery territory infarction.^{2,3} In this patient, right carotid is the principal supplier of left anterior cerebral artery because of aplasia of the left A1 segment. The right carotid stenosis was therefore very likely responsible for bilateral border-zone infarcts. The clinical symptoms and the neuroradiological picture demonstrated that brain ischemia was more pronounced in the left hemisphere, which can be considered the extreme border zone of the right carotid. The pathogenesis of watershed infarction is still debated; both the hemodynamic and the embolic mechanisms can be involved.⁴ In our case, the bilateral border-zone infarcts seem to suggest a hemodynamic pathogenesis secondary to severe carotid stenosis. Intracranial vascular imaging should be considered in stroke patients, not only for investigating intracranial stenosis, but also for evaluating variations of circle of Willis that can influence stroke pathophysiology.

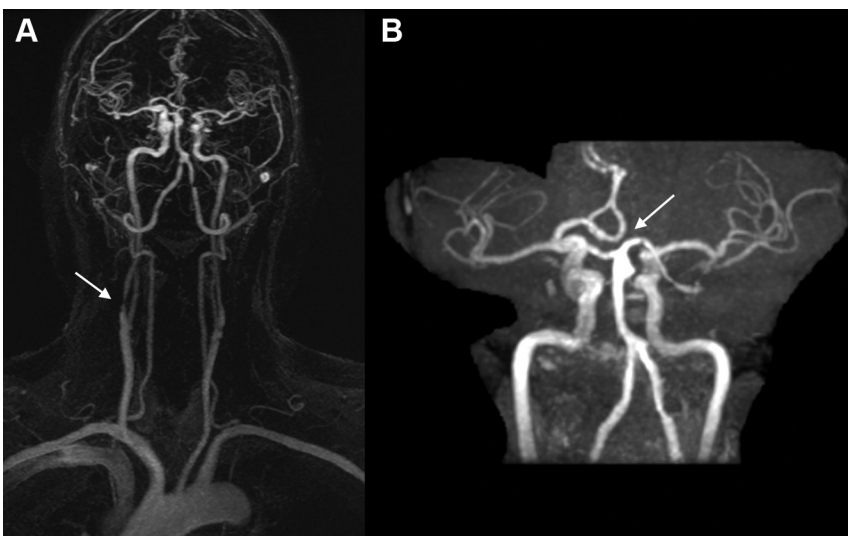


Figure 3. A, Contrast-enhanced magnetic resonance angiogram of the neck: Arrow shows narrowing of proximal ICA. **B,** Time-of-flight magnetic resonance angiogram: Arrow shows agenesis of left A1 segment.

Disclosures

None.

References

1. Krabbe-Hartkamp MJ, van der Grond J, de Leeuw FE, de Groot JC, Algra A, Hillen B. Circle of Willis: morphologic variation on three-dimensional time-of-flight MR angiograms. *Radiology*. 1998;207:103–111.
2. Yamaguchi K, Uchino A, Sawada A, Takase Y, Kuroda Y, Kudo S. Bilateral anterior cerebral artery territory infarction associated with unilateral hypoplasia of the A1 segment: report of two cases. *Radiat Med*. 2004;22:422–425.
3. Chuang YM, Liu CY, Pan PJ, Lin CP. Anterior cerebral artery A1 segment hypoplasia may contribute to A1 hypoplasia syndrome. *Eur Neurol*. 2007;57:208–211.
4. Momjian-Mayor I, Baron JC. The pathophysiology of watershed infarction in internal carotid artery disease: review of cerebral perfusion studies. *Stroke*. 2005;36:567–577.