

Appendix A. Supplementary material

Supplementary data associated with this article can be found, in the online version, at doi:10.1016/j.jocn.2011.03.001.

References

- Guidetti B, Gagliardi FM. Epidermoid and dermoid cysts. Clinical evaluation and late surgical results. *J Neurosurg* 1977;**47**:12–8.
- Russell DS, Rubenstein LJ. Dermoid and epidermoid cysts. In: Russell DS, Rubenstein LJ, editors. Pathology of tumors of the central nervous system, 1st ed. London: Edward Arnold; 1989. p. 690.
- Love JG, Kernohan JW. Dermoid and epidermoidal tumors of the central nervous system (cholesteatomas). *JAMA* 1936;**107**:1876–83.
- MacCarty CS, Leavens ME, Love JG, et al. Dermoid and epidermoid tumors in the central nervous system of adults. *Surg Gynecol Obstet* 1959;**108**:191–8.
- Ulrich J. Intracranial epidermoids: a study on their distribution and spread. *J Neurosurg* 1964;**21**:1051–8.
- Iaconetta G, Carvalho GA, Vorkapic P, et al. Intracerebral epidermoid tumor: a case report and review of the literature. *Surg Neurol* 2001;**55**:218–22.
- Netsky MG. Epidermoid tumors. Review of the literature. *Surg Neurol* 1988;**29**:477–83.
- Chandler WF, Farhat SM, Pauli FJ. Intrathalamic epidermoid tumor. Case report. *J Neurosurg* 1975;**43**:614–7.
- Gupta V, Sinha S, Singh AK, et al. Thalamic epidermoid cyst. A case report. *J Neurosurg Sci* 2000;**44**:42–4.
- Yan PX, Yu CJ. Minicraniotomy treatment of an intracerebral epidermoid cyst. *Minim Invasive Neurosurg* 2004;**47**:245–8.
- Kobayashi E, Serizawa T, Mitsuhashi H. A case report of giant epidermoid in the temporal lobe: considerations of the occurrence of intramedullary epidermoids. *No Shinkei Geka* 1994;**22**:769–73.
- Taniguchi M, Takemoto O, Hirano S, et al. A case of epileptic laughter associated with temporal epidermoid cyst: surgical treatment combined with subdural grid electrode study. *No Shinkei Geka* 1994;**22**:147–50.
- Abramson RC, Morawetz RB, Schlitt M. Multiple complications from an intracranial epidermoid cyst: case report and literature review. *Neurosurgery* 1989;**24**:574–8.
- Ahmed I, Auguste KI, Vachhrajani S, et al. Neurosurgical management of intracranial epidermoid tumors in children. *J Neurosurg Pediatr* 2009;**4**:91–6.
- Altschuler EM, Jungreis CA, Sekhar LN, et al. Operative treatment of intracranial epidermoid cysts and cholesterol granulomas: report of 21 cases. *Neurosurgery* 1990;**26**:606–13.
- Berger MS, Wilson CB. Epidermoid cysts of the posterior fossa. *J Neurosurg* 1985;**62**:214–9.
- Hamada Y, Kishi H, Matsuo S. Intraparenchymal epidermoid cyst of the right frontal lobe: a case report. *No Shinkei Geka* 1985;**13**:695–9.
- Kaido T, Okazaki A, Kurokawa S, et al. Pathogenesis of intraparenchymal epidermoid cyst in the brain: a case report and review of the literature. *Surg Neurol* 2003;**59**:211–6.
- Kawamura T, Ikeda H, Nakasato N, et al. A case of intracerebral epidermoid associated with aspergillosis. *No Shinkei Geka* 1992;**20**:463–7.
- Yamakawa K, Shitara N, Genka S, et al. Clinical course and surgical prognosis of 33 cases of intracranial epidermoid tumors. *Neurosurgery* 1989;**24**:568–73.
- Davidson HD, Ouchi T, Steiner RE. NMR imaging of congenital intracranial germinal layer neoplasms. *Neuroradiology* 1985;**27**:301–3.
- Fawcitt RA, Isherwood I. Radiodiagnosis of intracranial pearly tumours with particular reference to the value of computer tomography. *Neuroradiology* 1976;**11**:235–42.
- Vajtai I, Tassi D, Varga Z, et al. Malignant melanoma evolving inside a cerebral epidermoid cyst. *Orv Hetil* 1995;**136**:1171–4.
- Dechambre S, Duprez T, Lecouvet F, et al. Diffusion-weighted MRI postoperative assessment of an epidermoid tumour in the cerebellopontine angle. *Neuroradiology* 1999;**41**:829–31.
- Ikushima I, Korogi Y, Hirai T, et al. MR of epidermoids with a variety of pulse sequences. *AJNR Am J Neuroradiol* 1997;**18**:1359–63.

doi:10.1016/j.jocn.2010.12.055

Can subcortical infarction cause apraxia of eyelid opening?

Sang-Soo Lee *, Hyung-Suk Lee

Department of Neurology, Chungbuk National University School of Medicine, 52 Naesudong-ro, Cheongju-si, Chungbuk 361-711, South Korea

ARTICLE INFO

Article history:

Received 5 July 2010

Accepted 11 December 2010

Keywords:

Borderzone infarction

Eyelid apraxia

Perfusion CT scans

Subcortical infarction

ABSTRACT

Apraxia of eyelid opening is the inability to voluntarily open the eyes in the absence of motor dysfunction or blepharospasm. It has been described mostly in association with extrapyramidal diseases and only rarely in cortical lesions. We report a right-handed woman with a right subcortical lesion due to borderzone infarction showing eyelid opening apraxia.

© 2011 Elsevier Ltd. All rights reserved.

1. Introduction

Apraxia of eyelid opening (AEO) is a non-paralytic inability to voluntarily open the eyes and the absence of orbicularis oculi contraction, despite frontalis muscle contraction, normal spontaneous lid elevation, no ocular motor nerve dysfunction, no ocular sympathetic dysfunction and no ocular myopathy.¹ This syndrome has mostly been described in extrapyramidal diseases such as multiple system atrophy, Parkinson's disease, progressive supranuclear palsy, blepharospasm and motor neuron disease. It has been less frequently reported after bilateral or non-dominant hemisphere

vascular lesions. Most of these reported vascular lesions were cortical infarctions in the territory of the middle cerebral artery (MCA).^{2–4} AEO has rarely been reported with deep-seated vascular lesions.^{5,6} We present a right-handed woman who developed AEO after a right frontal subcortical lesion due to borderzone infarction.

2. Case report

A 76-year-old right-handed woman with no significant past medical history woke up in the early morning with dysarthric speech and left-sided weakness. She was alert and well oriented with left-sided neglect. She had no evidence of orofacial or limb apraxia. She had minimal left central facial weakness and left hemiparesis. The plantar response was flexor bilaterally. The pupils

* Corresponding author. Tel.: +82 43 269 6336; fax: +82 43 275 7591.
E-mail address: sslee@chungbuk.ac.kr (S.-S. Lee).

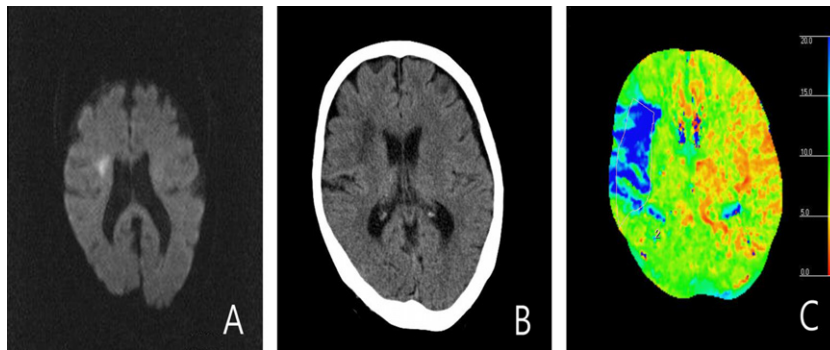


Fig. 1. (A) Day 1: axial diffusion-weighted MRI showing high signal intensity in the right frontal subcortical area; (B) day 3: CT scan showing low density in the same area; and (C) day 1: perfusion CT scan showing an increase in the mean transit time in the right frontal lobe. This figure is available in colour at www.sciencedirect.com.

were 4 mm, symmetrical, and equally reactive. She had full extra-ocular movement, although she revealed right conjugate gaze preference. She could not open her eyes on command, despite frontalis muscle contraction. Although she kept her eyes closed most of time, she opened them spontaneously at times. There was no evidence of ptosis. Eye closure was normal. No involuntary contraction of the orbicularis oculi was seen. Diffusion-weighted MRI and follow-up CT scans showed a deep right frontal subcortical lesion consistent with an internal carotid artery borderzone infarction (Fig. 1). There was no evidence of a basal ganglia lesion on imaging studies. Magnetic resonance angiography revealed occlusion in the distal main trunk of the right MCA and multifocal luminal irregularities in the posterior cerebral and vertebral arteries. Her symptoms had disappeared completely 6 days after infarction.

3. Discussion

The transient eyelid opening difficulty in our patient is consistent with AEO. This syndrome has been described only rarely in acute stroke lesions. However, AEO is an underestimated syndrome that should be taken into consideration in clinical practice with the frequent occurrence of MCA stroke. The precise neuroanatomical lesion responsible for AEO is unclear. Dysfunctions in the basal ganglia, rostral brainstem, or frontal lobe, especially the medial frontal lobe, have been suggested.⁷ Supranuclear control of eyelid opening seems to be so unequally distributed such that non-dominant hemisphere lesions are more common than dominant hemisphere lesions.^{2,3}

As well as being associated with extrapyramidal diseases, AEO has been described in bilateral or unilateral cortical dysfunction, but very rarely in patients with deep-seated lesions.^{5,6} Our patient is unique because she had a subcortical lesion due to a borderzone infarction. Given the angiographical findings and the absence of

cardiac thrombus, the occlusion in the MCA was likely to be atherosclerotic.

Two mechanisms could be suggested in our patient. The first is that cortical dysfunction caused AEO, because she had hemineglect and hypoperfusion in the frontal cortex as detected by perfusion CT scan (Fig. 1), despite the internal borderzone infarction on CT scan and diffusion-weighted MRI. This could result from a functional frontal lobe lesion of greater magnitude than appears on anatomical imaging such as CT scans or MRI. The second mechanism might be abnormal interruption of striatofrontal ganglionic connections for supranuclear control of eyelid opening.

Our patient exhibited AEO without other ocular or lid abnormalities and radiographical examinations indicated unilateral right hemispheric subcortical involvement. This case suggests that AEO could be associated with subcortical lesions. Thus, clinicians confronted with acute AEO should consider a subcortical lesion as well as focal cortical lesions.

Acknowledgement

The authors thank Dr. Earl Lee for the helpful review of the manuscript.

References

1. Lepore FE, Duvoisin RC. Apraxia of eyelid opening: an involuntary levator inhibition. *Neurology* 1985;**35**:423–7.
2. Johnston JC, Rosenbaum DM, Picone CM, et al. Apraxia of eyelid opening secondary to right hemisphere infarction. *Ann Neurol* 1989;**25**:622–4.
3. Averbuch-Heller L, Stahl JS, Remler BF, et al. Bilateral ptosis and upgaze palsy with right hemispheric lesions. *Ann Neurol* 1996;**40**:465–8.
4. Kaiboriboon K, Oliveira GR, Leira EC. Apraxia of eyelid opening secondary to a dominant hemispheric infarction. *J Neurol* 2002;**249**:341–2.
5. Verghese J, Milling C, Rosenbaum DM. Ptosis, blepharospasm, and apraxia of eyelid opening secondary to putaminal hemorrhage. *Neurology* 1999;**53**:652.
6. Myint PK, Anderson KN, Antoun NM, et al. Eyelid apraxia associated with bilateral paramedian thalamic infarct. *Age Ageing* 2008;**37**:343–4.
7. Boghen D. Apraxia of lid opening: a review. *Neurology* 1997;**48**:1491–503.