

Case report

Perfusion computer tomography helps to differentiate seizure and stroke in acute setting

Chuh-Hyoun Lie^a, Mirko Seifert^b, Jörg Poggenborg^b, Gereon R. Fink^{a,c}, Lothar Burghaus^{a,*}^a Department of Neurology, University Hospital of Cologne, 50924 Cologne, Germany^b Department of Radiology, University Hospital of Cologne, Cologne, Germany^c Institute of Neuroscience and Medicine, Cognitive Neurology Section, Research Centre Juelich, Juelich, Germany

ARTICLE INFO

Article history:

Received 21 July 2010

Received in revised form 5 June 2011

Accepted 25 June 2011

Available online 23 July 2011

Keywords:

Perfusion CT

Nonconvulsive status epilepticus

Stroke

1. Introduction

The acute onset of neurological symptoms raises the suspicion of stroke, but a subgroup of patients suffers conditions that mimic stroke. Seizures are a common feature of stroke-mimicking symptoms and include postictal state with Todd's paralysis or inhibitory seizures. In an acute setting, imaging is an important part of the diagnostic work-up in stroke patients, because thrombolytic therapy relies on the exclusion of hemorrhage. Non-enhanced computer tomography (CT) is the most common imaging technique in acute stroke, and additional scans (CT angiography [CT-A], perfusion CT [P-CT]) help to improve the diagnostic value. The wealth of data regarding the use of P-CT in acute stroke is contrasted by the absence of data regarding the diagnostic value of P-CT in epilepsy. We report the case of a patient with an acute onset of aphasia and right-sided hemiparesis, in which a P-CT scan revealed regional hyperperfusion and further diagnostic supported an epileptic origin.

2. Case report

2.1. Medical history

A 68-year-old patient was admitted to the hospital with aphasia and right-sided hemiparesis. The patient had a history of left occipital meningioma resection 3 years ago, causing a right homonymous hemianopsia. Slight secondary deterioration in the later course, due to recurrent meningioma, resulted in a radiation therapy 3 months ago. No other neurological deficits, apart from hemianopsia, were observed either post-surgery or post-radiation.

2.2. Diagnostic issues

Initially, an acute stroke was assumed and a CT scan was performed in order to assess whether thrombolytic therapy could be administered. The nonenhanced CT scan showed a left occipital post-operative defect, while no signs of an acute ischemia were found. CT-A and P-CT were performed additionally.

2.3. Methods

Using a Philips multislice scanner (Brilliance G), P-CT comprised of two series during intravenous administration of iodinated contrast material. Region of interest analysis was applied, thereby allowing for a comparison of areas between hemispheres with regard to cerebral blood flow (CBF), cerebral blood volume (CBV) and mean transit time (MTT).

2.4. Results

P-CT revealed regional hyperperfusion, with elevated CBF and CBV in the left parietal lobe, while MTT was not significantly altered when comparing both hemispheres (see Fig. 1, see Table 1). CT-A did not show significant differences in the diameter between the right and left posterior cerebral artery.

2.5. Further course and therapy

Later on, the patient presented clonic movements of the right leg, which could be prevented by intravenous application

* Corresponding author. Tel.: +49 221 478 4014; fax: +49 221 478 88819.

E-mail address: lothar.burghaus@uk-koeln.de (L. Burghaus).

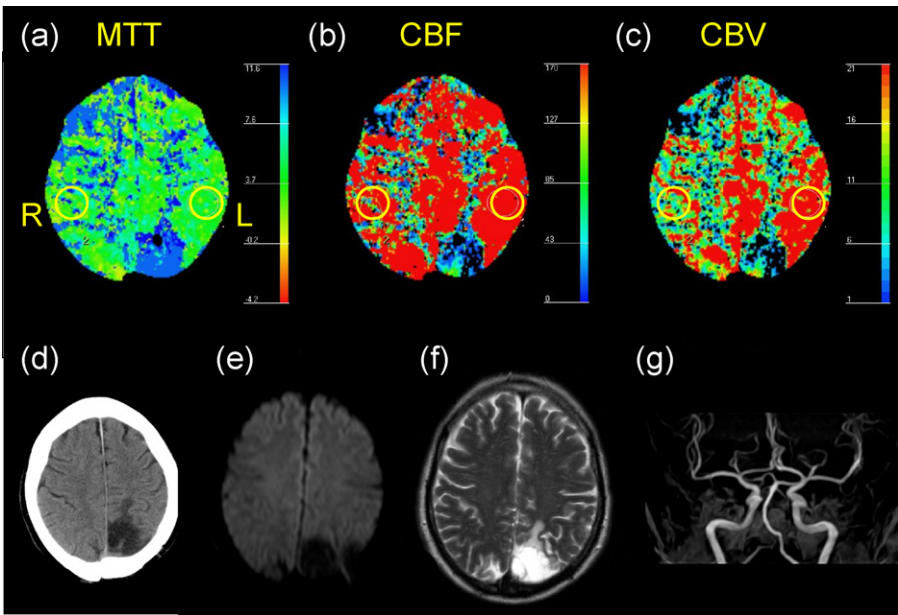


Fig. 1. (a–c) Perfusion CT showing the mean transit time (MTT [s]) and the regionally increased cerebral blood flow (CBF [ml/100 g/min]) and cerebral blood volume (CBV [ml/100 g]) in the left parietal lobe; (d) Non-enhanced CT-scan; (e–g) MRI-data: exclusion of acute infarction on (e) diffusion-weighted imaging (DWI), (f) T2-weighted imaging and exclusion of stenosing artery disease by (g) intracranial time-of-flight angiography. Right (R), Left (L).

of lorazepam 4 mg. Electroencephalography (EEG) showed a widespread delta-focus in the left hemisphere, including a parietooccipital maximum with several sharp waves. An antiepileptic therapy with levetiracetam was initiated (day 1: 500 mg bid, day 2: 1000 mg bid [maintenance dose]). Subsequently, no more clonic jerks were observed. Aphasia and right-sided hemiparesis resolved completely within the next few hours. Thereafter, the patient reported right-sided hemihypaesthesia and hemiparaesthesia prior to the onset of his right sided hemiparesis and aphasia, which had occurred for the first time, and for less than a minute, two weeks before. Magnetic resonance imaging (MRI) including MR angiography (MR-A), diffusion-weighted images (DWI), and apparent diffusion coefficient (ADC) was performed the following day. Cerebral ischemia and stenosing artery disease could be excluded as well as recurrent menigeoma (see Fig. 1). In comparison to postictal EEG, follow-up EEG showed a smaller theta-delta-focus with a maximum left occipital and rare sharp waves. Since then, just two episodes of headache and difficulties in concentrating have occurred, potentially caused by focal seizures.

3. Discussion

This case demonstrates P-CT as a useful tool to differentiate stroke and stroke-mimicking conditions in the acute setting. Initially, P-CT was performed in order to assess whether thrombolytic therapy could be administered. Contrary to expectations, P-CT revealed regional hyperperfusion, and further clinical course as well as EEG revealed an epileptic origin of symptoms. With the patient having no history of epilepsy, this first epileptic episode was remarkable, as it presented itself as a prolonged focal inhibitory seizure. The patient was fully conscious but noted sensory phenoma prior to the subacute onset of aphasia

and right-sided hemiparesis, which is an unusual seizure propagation phenomenon (occipital → parietal → temporal → frontal), especially because the symptoms developed before convulsive movements of the right leg occurred. This may also be due to a high-frequent series of seizures, which sometimes causes unusual propagations and symptoms (epileptic region versus symptomatic region). In any case, during the performance of P-CT epileptic activity was present, as hyperperfusion could not be explained otherwise. Other conditions, probably causing focal hyperperfusion, could be excluded: CT-A and MR-A did not show signs of a vascular pathology, and laboratory test and MRI did not show any signs of an encephalitis.

Focal inhibitory seizures are less easily recognized, as seizures present themselves more often with positive phenomena such as tonic, clonic or myoclonic movements. Nonconvulsive status epilepticus (NCSE) probably occurs more often than is generally assumed, but terminologies used in the literature have been inconsistent. Inhibitory seizures have been described e.g. as inhibitory epilepsy, aphasic status epilepticus or nonconvulsive seizure paralysis and comprise entities such as focal or generalized nonconvulsive status epilepticus or subtle status epilepticus. Inhibitory epileptic activity with inhibition of motor function has been suggested to arise from epileptic foci in so called ‘negative motor areas’ [1], which have been located in different association areas. Inhibitory phenomena thus may arise from interference of information processing in such multimodal areas.

Previous perfusion studies of patients with prolonged focal inhibitory seizures using SPECT [2] showed regionally hyperperfused brain regions contralateral to the side of clinical symptoms, which compares well with our findings. Cerebral perfusion measurements have been used for seizure focus determination, as epileptic activity was found to be associated with increased

Table 1

Region of interest	Mean transit time (s)	Cerebral blood volume (ml/100 g)	Cerebral blood flow (ml/100 g/min)
Left parietal lobe (L)	3.85	39.70	618.24
Right parietal lobe (R)	3.72	12.13	195.54

metabolic demands and temporarily increased regional hyperperfusion. SPECT studies demonstrated regional hyperperfusion in the ictal and hypoperfusion in the postictal phase. Recent MRI data is compatible with these findings, showing regional hyperperfusion in ictal states and providing complementary data by delineation of associated diffusion changes in focal status epilepticus [3].

While mainly SPECT and MRI have been used before for characterization of brain perfusion alterations in ictal or periictal conditions, P-CT data are still rare. The advantage of P-CT is that it is broadly available and could easily be applied in the acute management of epileptic conditions. Short processing times using CT are especially favourably in patients who need monitoring and who do not tolerate more time-consuming examinations. Recent studies using P-CT have been promising in that they demonstrate the feasibility of delineating regional hyperperfusion in nonconvulsive status epilepticus [4]. Although in our case Todd's paresis might be discussed as a possible differential diagnosis, the clinical signs and the observation of regional cortical hyperperfusion could be well explained by focal nonconvulsive status epilepticus. Moreover, the cerebral perfusion alterations are consistent with other recent P-CT studies [4], which demonstrated cortical hyperperfusion to be a discriminating feature of nonconvulsive status epilepticus, as compared to postictal states. Consistent with these data, a previous P-CT study delineated regional hypoperfusion in a case of postictal Todd's paresis [5]. These differential findings also suggest that the underlying pathophysiology of postictal Todd's paresis differs from that of focal inhibitory seizures.

While these observations are promising, further systematic studies may help to validate the method and to better understand the dynamics and the pathophysiological correlates of different perfusion parameters using P-CT in the context of ictal and periictal conditions.

4. Conclusion

Our case confirms the feasibility and the diagnostic value of perfusion CT in the emergency situation, where therapeutic decisions have to be made quickly and where the clinical differentiation between stroke and a nonconvulsive status epilepticus may not be unequivocal.

References

- [1] Luders HO, Dinner DS, Morris HH, Wyllie E, Comair YG. Cortical electrical stimulation in humans. The negative motor areas. *Adv Neurol* 1995;67:115–29.
- [2] Bussi re M, Pelz D, Reid RH, Young GB. Prolonged deficits after focal inhibitory seizures. *Neurocrit Care* 2005;2(1):29–37.
- [3] Szabo K, Poepel A, Pohlmann-Eden B, Hirsch J, Back T, Sedlaczek O, et al. Diffusion-weighted and perfusion MRI demonstrates parenchymal changes in complex partial status epilepticus. *Brain* 2005;128:1369–76.
- [4] Hauf M, Slotboom J, Nirkko A, von Bredow F, Ozdoba C, Wiest R, et al. Cortical regional hyperperfusion in nonconvulsive status epilepticus measured by dynamic brain perfusion CT. *AJNR* 2009;30(4):693–8.
- [5] Mathews MS, Smith WS, Wintermark M, Dillon WP, Binder DK. Local cortical hypoperfusion imaged with CT perfusion during postictal Todd's paresis. *Neuroradiology* 2008;50(5):397–401.