



Case Report

Central Nervous System Vasculitis With Positive Antithyroid Antibodies in an Adolescent Boy

Sarah L. Tsai MD^{a,*}, Evan C. Lewis MD^b, Erick Sell MD^b, Sharon Whiting MD^b

^a Division of Endocrinology, Children's Hospital of Eastern Ontario, Ottawa, Ontario, Canada

^b Division of Neurology, Children's Hospital of Eastern Ontario, Ottawa, Ontario, Canada

ARTICLE INFORMATION

Article history:

Received 6 December 2010

Accepted 18 April 2011

ABSTRACT

Hashimoto's encephalopathy is diagnosed when patients exhibit features of corticosteroid-responsive encephalopathy and positive antithyroid antibodies. The relationship between antithyroid antibodies and encephalopathy is subject to considerable debate. We describe corticosteroid-responsive encephalopathy in a 14-year-old boy with positive antimicrosomal antibodies. His history included subtle neurocognitive decline. He presented with seizures. He underwent a brain biopsy before initiating treatment after his third episode. That biopsy was consistent with central nervous system vasculitis. This report is unique because, to our knowledge, it describes the first pretreatment brain biopsy of a pediatric patient who fits the criteria for Hashimoto's encephalopathy.

© 2011 Elsevier Inc. All rights reserved.

Introduction

The diagnosis of Hashimoto's encephalopathy has been controversial since its inception. It is generally considered a diagnosis of exclusion in patients with encephalopathy who also exhibit positive serum antithyroid antibodies. The neurologic features are variable and include, but are not limited to, stroke-like episodes, dementia, psychiatric signs, seizures, coma, and myoclonus. The thyroid status of patients may be euthyroid, hypothyroid, or hyperthyroid [1].

The terminology used to describe encephalopathic patients with positive antithyroid antibodies is also controversial. Some authors think that the term "Hashimoto's encephalopathy" is appropriate for patients in whom no other cause for encephalopathy has been identified, because the antibodies could play a pathogenetic role [1,2]. In contrast, some authors suggest using "corticosteroid-responsive encephalopathy associated with Hashimoto thyroiditis" or similar terminology, because no proof is available that a relationship exists between the patient's thyroid status, antithyroid antibodies, and encephalopathy [3].

This report describes an adolescent boy with corticosteroid-responsive encephalopathy and positive antithyroid antibodies. This report is unique because it involves the first pretreatment

brain biopsy, to the best of our knowledge, of a pediatric patient who fits the criteria for Hashimoto's encephalopathy.

Case Report

A previously healthy 14-year-old boy with no medical history and no history of drug abuse presented with two similar episodes of seizure in a 3-month period (on day 0 and day 89). The first seizure was described as generalized, and the second as a focal, right-sided seizure with secondary generalization. No focal neurologic deficits were identified on examination. Blood, urine, and cerebrospinal fluid cultures and virology produced negative results. Inflammatory markers were drawn at presentation and during admission. Antinuclear antibody, anticardiolipin antibodies (immunoglobulin M and immunoglobulin G), lupus anticoagulant, classic antineutrophil cytoplasmic antibodies, and protoplasmic-staining antineutrophil cytoplasmic antibodies were negative throughout the patient's course. The patient was not tested for glutamic acid decarboxylase 65 autoantibodies or *N*-methyl-D-aspartate receptor subunit 1 autoantibodies. Additional inflammatory markers and the results of the patient's lumbar puncture are listed in Table 1. Magnetic resonance imaging revealed an uncomplicated type 1 Chiari malformation with no acute abnormalities that remained unchanged during both presentations. On first presentation, an electroencephalogram revealed diffuse frontal and posterior slowing, more significant on the left side. On second presentation, an electroencephalogram indicated diffuse abnormalities over the anterior quadrants, consistent with a postictal state. He was discharged with a regimen of clobazam.

Between his first and second presentations, the patient's electroencephalogram had normalized. Somatosensory evoked potentials were normal, and thyroid function tests produced normal results. However, testing for serum antithyroid antibodies (antithyroid peroxidase) produced positive results (Fig 1). He did not manifest goiter or clinical signs, or signs of thyroid dysfunction.

After discharge from his second presentation, the patient's memory, school performance, and interests declined, and he began to exhibit odd behaviors, such as prolonged laughter. Neuropsychologic tests (on day 140) revealed below-average functioning in most areas, especially in terms of nonverbal intellectual and attentional abilities.

* Communications should be addressed to: Dr. Tsai; Division of Endocrinology; Children's Hospital of Eastern Ontario; 401 Smyth Road; Ottawa, Ontario K1H 8L1, Canada.

E-mail address: s.lenihan.tsai@gmail.com

Table 1. Inflammatory markers and results of cerebrospinal fluid analysis during three presentations of patient

Test	Presentation 1 (Day 0)	Presentation 2 (Day 89)	Presentation 3 (Day 165)
Inflammatory markers			
ESR, mm/hr (normal range, 0–10)			
At presentation	10	9	38
Next day	30	NSQ	
CRP, mg/L (normal range, 0–8)			
At presentation	5.7	2.4	
Next day	34.3	23.1	
Leukocytes, $\times 10^9$ (normal range, $4.5\text{--}13 \times 10^9$)			
At presentation	10.2	14.3	33.4
Next day	10.3	9.5	12.5
C3, g/L (normal range, 0.70–1.70)			
At presentation	1.27		
30 days later			1.61
C4, g/L (normal range, 0.15–0.45)			
At presentation	0.19		
Thirty days later			0.19
Analysis of cerebrospinal fluid			
Protein, g/L (normal range, 0.15–0.60)	1.44	0.77	1.54
Glucose, mmol/L (normal range, 2.8–4.4)	4.1	2.9	4.0
Leukocytes, $\times 10^6$ /L (normal range, $0\text{--}5 \times 10^6$)	3	3	7
Erythrocytes, $\times 10^6$ /L (normal range, $0\text{--}1 \times 10^6$)	602	0	1
Opening pressure, cm H ₂ O (normal range, 10–20)	21.8		39
Abbreviations:			
C3 and C4 = Complement components			
CRP = C-reactive protein			
ESR = Erythrocyte sedimentation rate			
NSQ = Insufficient quantity for test			

He came to medical attention a third time after a 30-minute episode of status epilepticus (on day 165). Neurologic examination revealed a weak corneal and gag reflex, with no other abnormal cranial nerve findings. Tone was generally increased, but he was able to move his limbs against gravity and withdraw from pain. Deep tendon reflexes were brisk, with downgoing toes. His cerebrospinal fluid analysis is documented in Table 1. The initial electroencephalogram revealed intermittent, rhythmic 8 Hz activity in the right frontal region that at times recruited the left hemisphere. A marked benzodiazepine effect obscured the overall interpretation. The findings of magnetic resonance imaging were unchanged.

After reviewing the patient's neuropsychologic test results, a diagnosis of central nervous system vasculitis was rendered. Inflammatory markers (Table 1) and thyroid function tests (Fig 1) were performed, and antithyroid antibodies were again positive. Testing for antithyroid antibodies in the cerebrospinal fluid sample drawn at this presentation produced a negative result (reference range, <60 IU/mL). A conventional cerebral angiogram revealed no evidence of vasculitis, and he exhibited good recovery during the next week. He then developed more seizure activity, including subclinical seizures evident on electroencephalogram, originating from the right frontal region and spreading to involve the majority of the right hemisphere, with spikes in the occipital lobe. He underwent a brain biopsy on day 8

of his admission (day 173 after his first presentation), and began receiving high-dose methylprednisolone immediately afterward, with good response.

A brain biopsy revealed increased cellularity, with microglial activation and astrocytic reactions in the cortex. The leptomeninges exhibited moderate-to-dense fibrosis with isolated lymphocytes, consistent with chronic inflammation. Blood vessels demonstrated some lymphocytic infiltration in the wall or around the vessels. The vessel wall inflammation and leptomeninges stained positive for CD68, confirming the presence of microglial activation. T-cell inflammatory markers predominated in the specimen, insofar as it consisted mainly of CD3, CD4, and CD8. CD20, a marker for B cells, was negative. We found no viral inclusions or evidence of infectious etiologies. We concluded that the biopsy was consistent with a primary vasculitis of the central nervous system (Fig 2).

He was discharged from hospital 19 days after admission, and began receiving a central nervous system vasculitis treatment protocol, which consisted of monthly cyclophosphamide infusions (1 g/dose) for seven cycles and intravenous pulse methyl prednisone, followed by daily high-dose prednisone (60 mg/day) for 6 months. Afterward, the prednisone was reduced to 25 mg for 4 months, and then gradually withdrawn. He was also treated with mycophenolate (Cellcept) (Roche-Hoffman, San Francisco, CA) (1000 mg in the morning, and 750 mg in the evening).

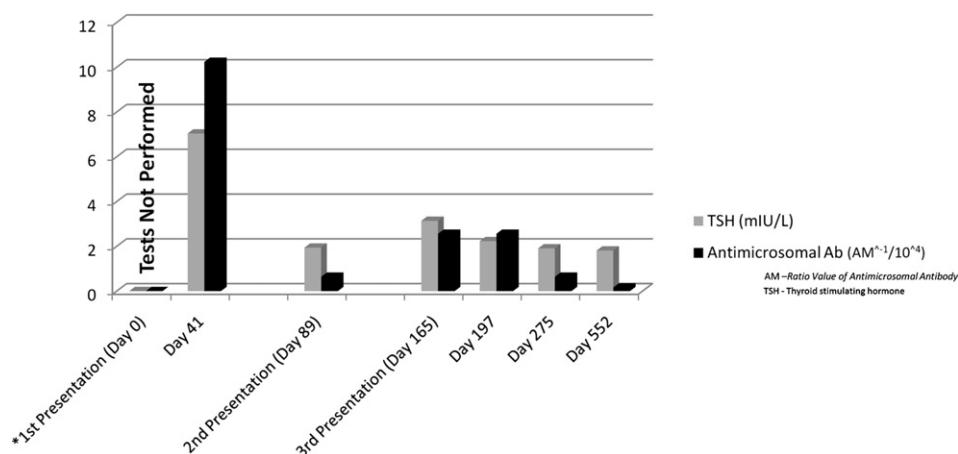


Figure 1. Thyroid function tests during the patient's three presentations. TSH = thyroid-stimulating hormone; Ab = antibody. *Thyroid function tests were not performed on day 0, and were first performed on day 41.

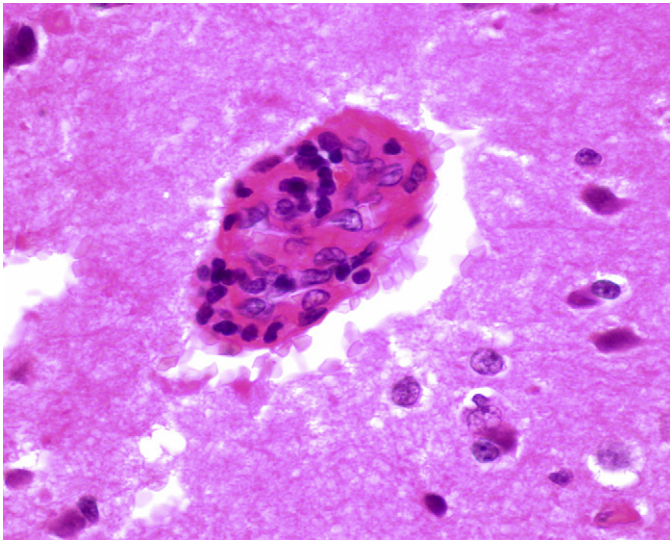


Figure 2. Photomicrograph of a small cortical blood vessel depicts a collapsed lumen. The endothelial cells are hyperplastic, and lymphocytic chronic inflammation is evident in the wall of the blood vessel.

His seizures were treated successfully with topiramate. The patient has done well during follow-up, with no further episodes of seizure. Initial difficulties in memory have been improving. He has required extra academic help at school. Follow-up neuropsychologic tests 1 year later (on day 496) revealed minor improvements in perceptive reasoning and memory. He manifested a significant reading disability, and was noted to be weak in the areas of working memory, attention, and concentration.

Follow-up thyroid function tests were performed approximately 1 month (day 197), 3 months (day 275), and 15 months (day 552) after the patient's final presentation. The resultant values are listed in Fig 1. The patient did not receive thyroid hormone supplementation at any time during his illness.

Discussion

The patient exhibited histologic findings similar to those in case reports of both Hashimoto's encephalopathy and central nervous system vasculitis. To our knowledge, no publications in the pediatric literature have described brain biopsies in cases of Hashimoto's encephalopathy pretreatment. In the adult literature, Castillo et al. [4] described brain biopsies in adult patients with steroid-responsive encephalopathy associated with autoimmune thyroiditis. The findings of brain biopsies were also described in adult patients with Hashimoto's encephalopathy [1,5]. The histologic findings in these cases were suggestive of a central nervous system vasculitis, and are similar to the findings in our patient and in patients described by Benseler et al. in their study of four children with angiography-negative primary central nervous system vasculitis [6]. Histology indicated a lymphocytic inflammation of the small and medium-sized vessels of both gray and white matter, reactive changes to the parenchyma (including mild-to-moderate gliosis), and transmural infiltration with lymphocytes. Using histologic features to distinguish Hashimoto's encephalopathy from primary central nervous system vasculitis is somewhat controversial. Conflicting evidence and failure to reach a consensus in the literature suggest either a significant overlap in histologic features or the same disease process.

A clinical diagnosis of Hashimoto's encephalopathy could have been rendered in our patient because he demonstrated neuropsychiatric signs, seizures, elevated antithyroid antibodies, and corticosteroid responsiveness. These features are also observed in patients with primary central nervous system vasculitis. Antithyroid antibodies are present in 10% of the general population [7]. Therefore, one would expect to find them in 10% of patients

with central nervous system vasculitis. Analyses of cerebrospinal fluid in both Hashimoto's encephalopathy and primary central nervous system vasculitis include elevated protein and/or lymphocyte pleocytosis [2,6,8]. Findings of magnetic resonance imaging are variable in patients with Hashimoto's encephalopathy, and range from normal to nonspecific T₂ signal abnormalities in subcortical white matter [1]. In patients with primary central nervous system vasculitis, the findings of magnetic resonance imaging include bilateral or unilateral multifocal T₂ hyperintensities in both white and grey matter [6].

Previous studies proposed antithyroid antibodies in the cerebrospinal fluid as a mechanism for the development of Hashimoto's encephalopathy [9]. In contrast, the absence of antithyroid antibodies in our patient's cerebrospinal fluid does not support the theory that an intrathecal synthesis of antithyroid antibodies and circulating immune complexes in the cerebrospinal fluid causes encephalopathy. Interestingly, cerebrospinal fluid antithyroid antibodies were reported as negative in cases of Hashimoto's encephalopathy [10]. Mijajlovic et al. reported on negative cerebrospinal fluid antithyroid antibodies in a patient with vasculitic features who responded well to glucocorticoids. In contrast, they also described positive cerebrospinal fluid antithyroid antibodies in a patient with diffuse progressive Hashimoto's encephalopathy who did not respond to corticosteroids [11]. At this point, the evidence is insufficient to determine the nature of the relationship between the presence of antithyroid antibodies in the cerebrospinal fluid and the clinical features of patients.

The titer of the patient's serum antithyroid antibodies did not appear to correlate with his clinical condition, a finding consistent with numerous sources [1,9]. Similarly, in Hashimoto's thyroiditis, the antithyroid antibody titers do not correlate with the severity of clinical status or treatment. However, their direct involvement in the pathophysiology of thyroid dysfunction was proven. The role, if any, of antithyroid antibodies in Hashimoto's encephalopathy has never been fully clarified or proven.

The relationship between Hashimoto's encephalopathy and central nervous system autoimmunity is not clear, although contributing roles of various autoantibodies have been proposed. High reactivity against human α -enolase autoimmune antigen was described in patients with Hashimoto's encephalopathy compared with healthy control subjects and patients with other neurologic illnesses [12]. Yoneda et al. demonstrated a high specificity and prevalence of α -enolase antibodies (68%) in patients who met the criteria for Hashimoto's encephalopathy [13]. Oide et al. proposed that antineuronal antibodies may play a role in the pathogenesis of Hashimoto's encephalopathy, based on brain biopsy findings during autopsy [14].

Antithyroid antibodies are present in 10% of the general population. Hence, reported cases of Hashimoto's encephalopathy may represent the coincidence of a common clinical condition in a selected group of patients with encephalopathy of unknown etiology. To date, however, no definite evidence exists for a causal relationship between encephalopathy and positive antithyroid antibodies, and as described earlier, no clear histologic features distinguish it from central nervous system vasculitis with negative antithyroid antibodies. Published cases of central nervous system vasculitis do not routinely report antithyroid antibody status. Such information may be lacking because antithyroid antibodies are not routinely measured in encephalopathic patients at certain centers, or patients may have demonstrated negative antibodies that were not reported.

Performing a brain biopsy before the initiation of treatment in patients with seizures, encephalopathy, and positive antithyroid antibodies may help delineate the pathophysiology of this condition. In elucidating the etiology of Hashimoto's encephalopathy,

further research into the pathogenesis of autoimmune encephalopathy would be highly beneficial. Future research directions could include measuring and reporting on antithyroid antibodies and thyroid function in patients with a diagnosis of primary central nervous system vasculitis. Given the similarities between the two conditions, such information could serve to move them definitively into the same diagnostic spectrum. Alternately, such information could prove that they are two distinct clinical entities.

The authors thank J. Michaud, MD (Children's Hospital of Eastern Ontario, Ottawa, Ontario, Canada), for providing the image and legend for Fig 2.

References

- [1] Chong JY, Rowland LP, Utiger RD. Hashimoto encephalopathy: Syndrome or myth? *Arch Neurol* 2003;60:164–71.
- [2] Mocellin R, Walterfang M, Velakoulis D. Hashimoto's encephalopathy: Epidemiology, pathogenesis, and management. *CNS Drugs* 2007;21:799–811.
- [3] Fatourech V. Hashimoto's encephalopathy: Myth or reality? An endocrinologist's perspective. *Best Pract Res Clin Endocrinol Metab* 2005;19:53–66.
- [4] Castillo P, Woodruff B, Caselli R, et al. Steroid-responsive encephalopathy associated with autoimmune thyroiditis. *Arch Neurol* 2006;63:197–202.
- [5] Duffy P, Yee S, Reid IN, Bridges LR. Hashimoto's encephalopathy postmortem findings after fatal status epilepticus. *Neurology* 2003;61:1124–6.
- [6] Benseler SM, deVeber G, Hawkins C, et al. Angiography-negative primary central nervous system vasculitis in children. *Arthritis Rheum* 2005;52:2159–67.
- [7] Hollowell JG, Staehling NW, Flanders WD, et al. Serum TSH, T (4), and thyroid antibodies in the United States population (1988 to 1994): National Health and Nutrition Examination Survey (NHANES III). *J Clin Endocrinol Metab* 2002;87:489–99.
- [8] Elbers J, Benseler S. Central nervous system vasculitis in children. *Curr Opin Rheum* 2008;20:47–54.
- [9] Ferracci F, Bertiato G, Moretto G. Hashimoto's encephalopathy: Epidemiologic data and pathogenetic considerations. *J Neurol Sci* 2004;217:165–8.
- [10] Hoffman F, Reiter K, Kluger G, et al. Seizures, psychosis, and coma: Severe course of Hashimoto encephalopathy in a six-year-old girl. *Neuropediatrics* 2007;38:197–9.
- [11] Mijajlovic M, Mirkovic M, Dackovic J, Zidverc-Trajkovic J, Sternic N. Clinical manifestations, diagnostic criteria and therapy of Hashimoto's encephalopathy: Report of two cases. *J Neurol Sci* 2010;288:194–6.
- [12] Fujii A, Yoneda M, Ito T, et al. Autoantibodies against the amino terminal of α -enolase are a useful diagnostic marker of Hashimoto's encephalopathy. *J Neuroimmunol* 2005;162:130–6.
- [13] Yoneda M, Fujii A, Ito A, Yokoyama H, Nakagawa M, Kuriyama M. High prevalence of serum autoantibodies against the amino-terminal of α -enolase in Hashimoto's encephalopathy. *J Neuroimmunol* 2007;185:195–200.
- [14] Oide T, Tokuda T, Yazaki M, et al. Anti-neuronal autoantibody in Hashimoto's encephalopathy: Neuropathological, immunohistochemical, and biochemical analysis of two patients. *J Neurol Sci* 2004;217:7–12.