

Arteriovenous malformation and glioma: coexistent or sequential?

Case report

ROBERT GOODKIN, M.D., BARBARA ZAIAS, M.D., AND W. JOST MICHELSEN, M.D.

Departments of Neurological Surgery and Pathology, City of Hope National Medical Center, Duarte, California; Department of Neurological Surgery, University of Southern California School of Medicine, Los Angeles, California; and Department of Neurological Surgery, Neurological Institute of New York, New York, New York

✓ A 9-year-old girl was evaluated for behavioral changes and seizures. Initial computerized tomography and cerebral angiography revealed a left cerebral vascular mass, diagnosed as an arteriovenous malformation. An embolization procedure was attempted but was terminated before completion because the patient developed a right hemiparesis. Her right-sided neurological deficit subsequently increased with enlargement of the mass lesion. On follow-up cerebral angiography approximately 2 years later the vascular malformation was no longer demonstrated. Biopsy of the mass lesion revealed it to be an anaplastic astrocytoma. This case is reported with a review of the literature on the coexistence of a brain tumor and a vascular malformation, the difficulties in diagnosis, and possible etiologies.

KEY WORDS • arteriovenous malformation • glioma • brain neoplasm

RARELY is there confusion in differentiating a brain tumor with abnormal vasculature from an arteriovenous malformation (AVM) of the brain. This report describes a 9-year-old girl in whom a left cerebral mass lesion, initially diagnosed and treated as an AVM, was subsequently proved from biopsy examination to be an astrocytoma. This case raises several questions as to the possible etiology: that is, the coexistence of two separate lesions, the evolution of one lesion into the other, a single "multipotential" lesion, or misdiagnosis.

Case Report

This 9-year-old Caucasian girl started to tire easily and her face occasionally became "beet red" beginning in September, 1983. In November, 1983, she developed a seizure. A lumbar puncture showed clear colorless cerebrospinal fluid (CSF). A computerized tomography (CT) brain scan on November 15, 1983, showed a contrast-enhancing lesion in the left centrosylvian region, with draining veins into the vein of Galen and straight sinus (Fig. 1). There was a large low-density area in the left middle fossa consistent with CSF, believed to be a dilated trapped temporal horn of the left

lateral ventricle. There was a slight midline shift from left to right. Bilateral cerebral and left vertebral angiography (Fig. 2) performed on November 16 revealed vascular malformation with some mass effect in the left centrosylvian region, being fed primarily by the left anterior choroidal artery, left lenticulostriate branches of the insular loops of the left middle cerebral artery, left medial and lateral choroidal artery, branches of the left posterior cerebral artery, and (to a lesser extent) the left thalamoperforating artery. Primary drainage was into the vein of Galen and straight sinus. This constellation of findings was considered compatible with an AVM of the left cerebrum. Anticonvulsant medication was initiated.

In January, 1984, follow-up CT revealed a slightly increased left-to-right shift of the midline, but the appearance was otherwise essentially similar to the changes seen in November, 1983. The patient was referred for embolization of the AVM. The procedure was terminated when, during two test balloon inflations, she developed a right hemiparesis.

In June, 1984, a right visual field defect was demonstrated. In July, repeat CT without contrast enhancement showed enlargement of the left cerebral lesion,

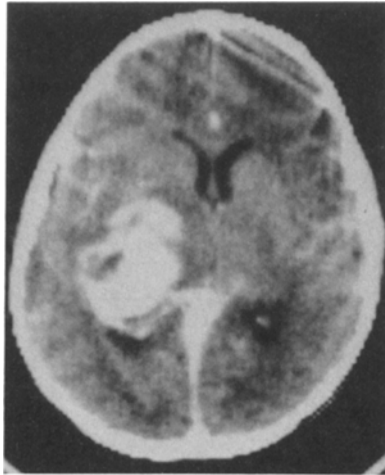


FIG. 1. Computerized tomography scan with contrast enhancement obtained on November 15, 1983. A contrast-enhancing lesion is seen in the left cerebrum. There is a mild left-to-right midline shift.

increased left-to-right shift, and ventricular enlargement. The patient's right hemiparesis increased. There was no hemiatrophy. The patient was referred for follow-up examination and, on December 12, 1984, repeat cerebral and posterior fossa angiography revealed a decrease in the vascular component of the mass lesion, occlusion of some feeding vessels, and an increase in the left temporal mass effect. At this time the possibility that the mass lesion was an evolving primary brain tumor was considered. The patient underwent a left ventriculoperitoneal shunt procedure with placement of the ventricular end of the shunt system into the fluid-

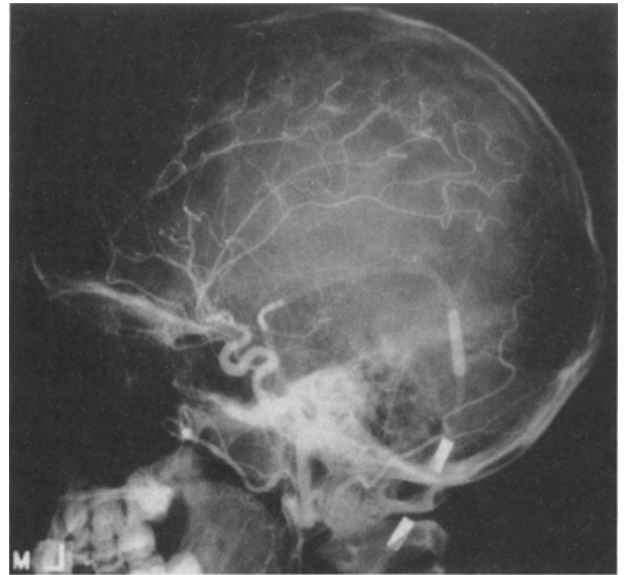


FIG. 3. Left carotid angiogram, lateral view arterial phase, obtained on September 10, 1985. The previously seen arteriovenous malformation is not visualized on this or on vertebral angiography.

filled cavity considered to be a trapped temporal horn of the left lateral ventricle. The fluid was xanthochromic, and cytological examination of the fluid specimen revealed no evidence of abnormal cells. After shunt placement, the patient's neurological status transiently improved. A follow-up CT scan showed decompression of the fluid-filled cavity in the left temporal lobe and decreased midline shift without a change in

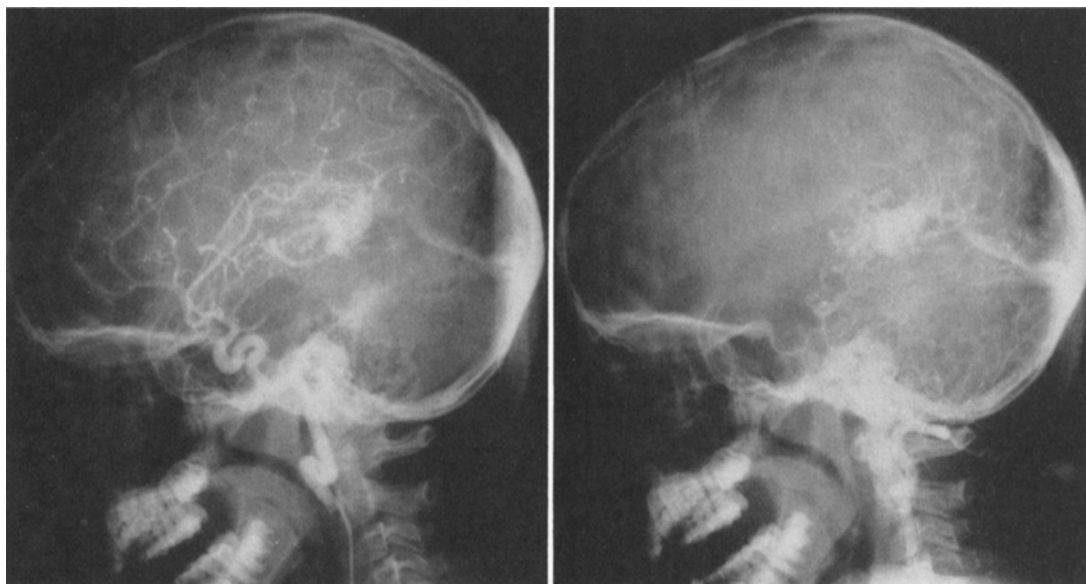

FIG. 2. Left carotid angiogram, lateral view (*left*), and left vertebral angiogram, lateral view (*right*), obtained on November 16, 1983. An arteriovenous malformation is evident in the left cerebrum.

the left cerebral mass lesion; however, serial follow-up CT scans demonstrated progressive enlargement of the left cerebral mass lesion.

In August, 1985, it had become apparent to the parents that the patient's condition was deteriorating, primarily manifested by withdrawal from activities and apathetic mood. By September, her speech had become more hesitant and on occasion she would stop speaking in the middle of a sentence. Left carotid and left vertebral angiography on September 10 showed hypovascularity of the mass. The previously demonstrated abnormal vascular pattern was not present (Fig. 3). A post-angiography CT scan delineated the left cerebral mass lesion (Fig. 4).

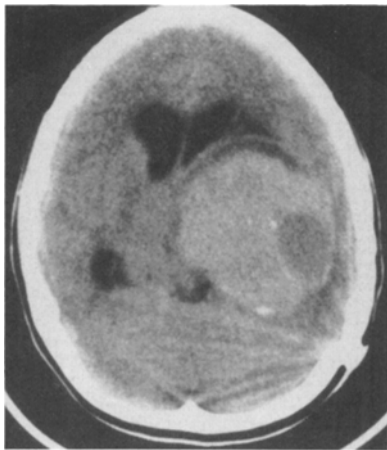


FIG. 4. Computerized tomography scan obtained after left carotid and vertebral angiography showing a tumor of the left cerebrum.

On September 12, 1985, the patient underwent a left temporal craniotomy with subtotal resection of the mass. Multiple fine vessels traversed the tumor, but no AVM was seen within the operative field. Histological examination disclosed foci of mild to moderate astrocytic proliferation, irregular dilated sinusoidal vascular channels, and an increased number of small arterioles and veins. Parenchyma adjacent to blood vessels was sparsely cellular with abundant Rosenthal fibers and hemosiderin pigment. Other areas had astrocytic proliferation and pleomorphism (Fig. 5).

Six months later (in March, 1986) the patient underwent a second subtotal resection when her condition acutely deteriorated following a probable seizure. A CT scan at that time evidenced further enlargement of the tumor. The histological diagnosis was increased cellularity, nuclear pleomorphism, and vascular proliferation consistent with anaplastic astrocytoma.

Discussion

Review of Literature

Coexistence of a vascular malformation and an intracerebral brain tumor is an infrequent occurrence. Review of the literature discloses 13 previously reported cases (Table 1). In 1958, White, *et al.*,²⁰ in their review of intracranial vascular tumors found at necropsy, included a patient with a left temporal lobe cavernous hemangioma and an astrocytoma of the septum pellucidum. Fine, *et al.*,⁴ in 1960 described a 15-year-old boy with a right parietal AVM and an intraventricular oligodendroglioma. They believed that the coexistence of the two lesions in the same patient was fortuitous. In 1966, Welcher and Seidel¹⁹ described a patient with two discrete lesions in the same hemisphere: an AVM

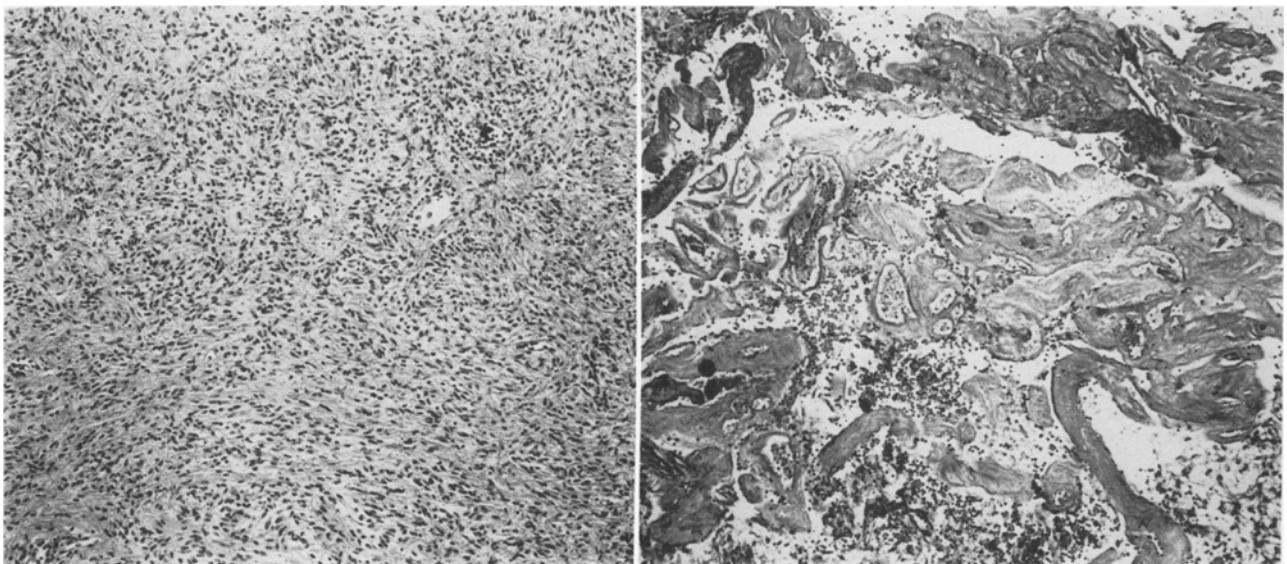


FIG. 5. Photomicrographs of the tumor. H & E, $\times 82$. *Left*: Typical tumor field showing hypercellularity and pleomorphic nuclei. *Right*: Abnormal cluster of vessels within the tumor, possibly representing residua of prior vascular malformation.

TABLE 1
Summary of 14 reported cases of coexisting vascular malformation and intracerebral brain tumor*

Authors & Year	Location	Appearance of Lesions	Clinical Features		Radiography		Surgical Findings		Autopsy Done	Remarks
			Age (yrs), Sex	Duration	SAH	Study	Mass Effect	Gross		
White, <i>et al.</i> , 1958	M = lt temporal, T = septum	Sep, Si	45, M	?	-	?	?	tumor of septum	+	cav. hemangiomas liver & lung; ? genetic syndrome
Fine, <i>et al.</i> , 1960	M = rt parietal, T = intravert.	Sep, Si	15, M	6 mos	-	vgram, bilat carotid angio	+	superficial angioma abn. tissue, rt ventricle	-	"fortuitous association"
Raynor & Kingman, 1965	M & T = ?	Cb, Si	19, M	1.5 yrs	+	carotid & vert angio, vgram	+	AVM of vermis	+	first report of intermixture of lesions
Welcher & Seidel, 1966	M & T = ?	Sep, Si	?	?	?	?	?	?	+	fibrillary astrocytoma discovered at autopsy, same hemisphere, different sites
Heffner, <i>et al.</i> , 1971	M = rt frontal meninges, T = rt frontal	Sep, Si	17, M	?, 8 yrs	-	bilat carotid; angio	+	rt frontal inflt. mass abn. meningeal vessels	-	Cb lg abn. vessels & unusual tumor vascularity; may suggest AVM & tumor
Crowell, <i>et al.</i> , 1975	M & T = rt temporal	Cb, Si	17, M	3 mos	+	rt carotid angio	+	cyst & abn. vessels & tissue	-	SAH & mass effect may be AVM & tumor
Zuccarello, <i>et al.</i> , 1979	M & T = lt temporal	Cb, ?	50, M	5 mos	-	lt carotid angio	+	2nd surg; postop scar tumor with hemorrhagic cyst	-	secondary neoplastic glial changes in response to vascular malformation
Fischer, <i>et al.</i> , 1982	M & T = lt frontal	Cb, Seq†	11, M	5 yrs	-	carotid angio, brain scan, CT	-	lt frontal; discolored tough & gelatinous tissue	-	tumor appeared 5 yrs later in same site as hemangioma
Chen, <i>et al.</i> , 1985	M & T = rt temporo-occipital	Cb, Si	19, F	several mos	-	rt carotid, angio, CT	+	calcified, soft tissue with brown cyst; adherent to dura	-	subtotal resection, with no change in size of residual mass after 5 yrs
	M & T = rt frontal	Cb, Si	25, M	(?) 12 yrs	-	CT with contrast	+	abn. tissue with calcium, hemorrhage, cysts, & abn. vessels	-	coexistent lesions
Martinez-Lage, <i>et al.</i> , 1986	M = rt parietal, T = rt frontal horn	Sep, Si	43, M	(?) 2 yrs	+	carotid & vert angio, CT	+	rt frontal horn tumor rt parietal cortical AVM	-	tumor caused SAH, not AVM
Licata, <i>et al.</i> , 1986	M = rt rolandic, T = rt parietal	Cb, Seq†	44, M	3 mos	?	angio, CT	-	angioma	-	AVM diagnosed radiographically
	M = lt occipital, T = lt temporal	Sep, Si	60, F	?	?	?	?	?	-	AVM diagnosed by angio, initially; later disappeared; CT showed mass; same site
Goodkin, <i>et al.</i> , 1990	M & T = lt parietotemporal	Cb, Seq	9, F	2 yrs	-	carotids & vert angio, CT	+	no AVM seen in operative field	-	anaplastic astrocytoma

* M = malformation; T = tumor; Sep = separate; Cb = combined; Si = simultaneous; Seq = sequential; SAH = subarachnoid hemorrhage; vgram = ventriculogram; angio = angiogram; abn. = abnormal; cav = cavernous; CT = computerized tomography; vert = vertebral artery; AVM = arteriovenous malformation.

† Same site, different time.

TABLE 2

Summary of sequence and location of lesions

Authors & Year	No. of Cases
coexistent: separate lesions (ipsilateral)	
White, <i>et al.</i> , 1958	1*
Fine, <i>et al.</i> , 1960	1
Welcher & Seidel, 1966	1
Heffner, <i>et al.</i> , 1971	1
Martinez-Lage, <i>et al.</i> , 1986	1
Licata, <i>et al.</i> , 1986	1
total cases	6
coexistent: combined within one lesion (site)	
Raynor & Kingman, 1965	1
Crowell, <i>et al.</i> , 1975	1
Zuccarello, <i>et al.</i> , 1979	1
Fischer, <i>et al.</i> , 1982	1
Chee, <i>et al.</i> , 1985	1
total cases	5
"subsequent:" one lesion after the other (same site)	
Fischer, <i>et al.</i> , 1982	1
Licata, <i>et al.</i> , 1986	1
Goodkin, <i>et al.</i> , 1990	1
total cases	3

* Tumor in septum.

and an astrocytoma. The brain tumor, discovered at necropsy, had not been suspected during life. They considered their report of coexisting lesions to be the first, apparently unaware of the reports of Fine, *et al.*, or White, *et al.* In 1965, Raynor and Kingman¹⁴ reported a patient with a hemangioblastoma and a vascular malformation occurring as one lesion. These authors credit themselves with presenting the first case of two intermixed lesions within the same mass, as well as the demonstration of an increase in size and vascularity of the lesion. In 1971, Heffner, *et al.*,⁸ reported a patient whose initial radiographic study suggested "vascular glioma;" however, surgery disclosed a nonvascular astrocytoma and a "typical AVM." Crowell, *et al.*,² described a patient who presented with subarachnoid hemorrhage (SAH) and whose angiogram showed an avascular mass; an oligodendroglioma and AVM were disclosed at the same site. Zuccarello, *et al.*,²¹ reported the case of a patient with an intermixed AVM and malignant astrocytoma. They suggested that the association of a tumor and vascular malformation represented a definite entity and not a coexistence of individual lesions. In 1982, Fischer, *et al.*,⁵ described two patients with glial neoplasms and cavernous hemangiomas. In one of these, the lesions were combined and coexistent; in the other, an oligodendroglioma apparently subsequently grew at the same site as the hemangioma. Chee, *et al.*,¹ reported a case of coexisting oligodendroglioma and angioma in which the CT scan had not shown the angioma. An interesting case is that of Martinez-Lage, *et al.*,¹² in which the SAH is believed to have originated from the intraventricular oligodendroglioma rather than the parietal AVM. Licata, *et al.*,¹¹ reported two patients with central nervous system (CNS) parenchymal tumors and AVM's; one had coexistent lesions while the other patient's tumor appeared subsequently at the site of the former angioma.

Of these 14 cases, including ours, the vast majority (11 patients) had simultaneous occurrence or coexistence of the two lesions, whereas three apparently showed subsequent development of a tumor at the same site as the previously diagnosed vascular malformation (Table 2). Among the 11 simultaneously occurring lesions, six were coexistent but separate within the same hemisphere,^{8,11,12,19} ipsilateral ventricle,⁵ or septum pellucidum²⁰ and five were coexistent but combined or intermixed.¹⁴ In the remaining three patients, tumors were found at varying periods of time after the initially diagnosed vascular lesion: 5 years,⁵ 30 months,¹¹ and 22 months (our case).

A separate group of combined or coexistent neural tumors and vascular malformations is that of peripheral nervous system neurilemmomas and angiomas reviewed in 1979 by Kasantikul and Netsky.⁹ They described eight cases of their own in addition to five culled from the literature and proposed that a common embryological origin from ectomesenchyme could explain their simultaneous occurrence. We have not included this group in our tabulation, since we are concerned with

intracranial CNS parenchymal tumors and associated vascular lesions.

Other features include an age range at occurrence from 11 to 25 years in patients with oligodendrogliomas and vascular malformations, with the only exception being a 43-year-old man. In cases in which the patient's sex was known, the majority were male: all five cases of oligodendroglioma and four of five cases of astrocytoma.

Etiology and Diagnosis

The question raised by the present case report is that of the possible occurrence of two different CNS lesions, either simultaneously or sequentially within the same patient, or the existence throughout the clinical course of only one lesion. Difficulties encountered in pathological and radiological interpretations can thwart a clear resolution of the issue. The gross and histological features of brain tumors (gliomas) and vascular malformations have many similarities. In 1937, Tönnis¹⁸ first described arteriovenous shunting and abnormal blood vessels observed at surgery for a glioblastoma multiforme. Since then, other vascular changes within malignant gliomas have been well described¹³ and include: increased small blood vessels, mainly capillaries, excessively convoluted masses of capillaries ("glomeruloids"); sinusoidal channels; and prominent endothelial and adventitial proliferation affecting all sizes of vessels. Tortuous ectatic vessels, aneurysmal dilations, and arteriovenous anastomoses with early draining veins as well as thrombosed vessels in varying stages of organization and recanalization may be seen in both tumors

AVM and glioma at same cerebral site

TABLE 3
Radiographic diagnoses in 12 cases*

Authors & Year	X-Ray Findings	Brain Scan Findings	Ventriculographic Findings	Angiographic Findings	CT Scan Findings	Remarks
Fine, <i>et al.</i> , 1960	—	—	intraventricular mass	rt AVM; hydrocephalus; no mass seen	—	angio. missed tumor, ventriculogram missed AVM
Raynor & Kingman, 1965	—	—	posterior fossa midline mass	carotid & vertebral art studies, initially normal	—	studies did not diagnose vascular malformation
Heffner, <i>et al.</i> , 1971	eroded sella depressed rt orbital plate	low rt frontal abnormality	—	carotid arts indicated rt frontal mass with abnormal vessels & early venous filling	—	initial angio. diagnosed "vascular" glioma; abnormal tumor vascular pattern suggested AVM + tumor
Crowell, <i>et al.</i> , 1975	normal	rt temporal abnormality	rt temporal lobe cyst in communication with ventricle	rt carotid art indicated large, avascular, intratemporal mass	—	no suggestion of vascular malformation
Zuccarello, <i>et al.</i> , 1979	normal	lt temporal abnormal uptake	—	lt carotid art indicated temporal mass with tortuous vessels & arteriovenous fistula	—	angio. did diagnose vascular malformation, but not tumor
Fischer, <i>et al.</i> , 1982	lt frontal Ca ⁺⁺	lt frontal abnormality	—	carotid art study normal	lt frontal Ca ⁺⁺ ; no mass effect or enhancement	no suggestion of vascular malformation no suggestion of vascular malformation
	rt temporo-occipital Ca ⁺⁺ mass	—	—	rt carotid art indicated stretched vessels; no pathologic vessels or tumor blush	rt temporo-occipital with Ca ⁺⁺ ; hydrocephalus; no abnormal enhancement	
Chee, <i>et al.</i> , 1985	—	—	—	—	rt frontal mass with Ca ⁺⁺ ; mass effect; slight enhancement	no suggestion of vascular malformation on CT
Martinez-Lage, <i>et al.</i> , 1986	no Ca ⁺⁺ no intracranial hypertension	—	—	rt carotid art study; rt parietal AVM; hydrocephalus; no abnormal vascular stain at site; lt carotid & vertebral arts normal	rt lateral ventricular hyperdense mass with faint enhancement	angio. missed mass; CT missed vascular malformation
Licata, <i>et al.</i> , 1986	—	—	—	rt carotid study; rt Rolandic AVM 2½ yrs later; rt parietal mass with abnormal vascularity; tumor	no contrast: normal; with contrast: parietal angioma; 2½ yrs: rt parietal mass with peripheral enhancement; diagnosis: abscess	angio. & CT initially correct; angio. correct, CT incorrect 2nd time
	?	?	?	lt occipital angioma	lt temporal glioma	angio. missed mass; CT missed vascular malformation
Goodkin, <i>et al.</i> , 1990	—	—	—	bilat carotid & lt vertebral art study; lt centrosylvian AVM 2 yrs later: hypovascular mass without abnormal vascularity	markedly enhancing lt centrosylvian mass with draining veins indicating vein of Galen increasing size of lt cerebral mass	initial studies diagnosed AVM; subsequent studies: disappearance of AVM, increasing size of hypovascular mass in same site

* AVM = arteriovenous malformation; CT = computerized tomography; angio. = angiogram; — = not done. Vascular malformation not initially diagnosed: a) by angio in five of 11 cases with angiography done; b) by CT in five of seven cases with CT done.

and vascular malformations. The AVM, particularly, can exhibit any or all of these features, in addition to abnormally structured arteries and veins.

Radiographic vascular changes of tumors can overlap with those of vascular malformations, causing diagnostic confusion. The presence of abnormal afferent and efferent blood vessels and arteriovenous shunting of blood, in the absence of mass effect and edema, usually leads to the radiographic diagnosis of an AVM. Difficulty may arise in differentiating an AVM which was ruptured with hematoma formation from a tumor with mass effect. Kumar, *et al.*,¹⁰ reviewed 60 cases of clinically ruptured AVM's, in which high-resolution CT demonstrated local or remote mass effect in 33 patients. There are similarities between the CT scan appearance of their cases, as illustrated in their Figs. 1 and 3, and the CT scan findings in our case. Vascular malformations may simulate tumors, showing high density on noncontrast CT but not appearing on angiography (so-called "cryptic" angiomas, now more readily appreciated by a characteristic magnetic resonance (MR) image appearance). By contrast, a recent report by Rigamonti, *et al.*,¹⁵ describes a patient with a right frontal venous malformation diagnosed by angiography, CT, and MR imaging who 1 year later developed a glioblastoma in the same site. They suggested that the initial studies did not exclude the possibility that the venous malformation represented a rather prominent venous drainage of the subsequently diagnosed glioblastoma.

Multiple etiologies for the association of vascular malformations and tumors within the same patient have been proposed. These include: fortuitous association;^{4,12} genetic predisposition;²⁰ a distinct entity, possibly of viral origin, with biological potential to evolve along different lines;⁵ a secondary or reactive neoplastic glial change to a previously existing vascular malformation;²¹ and the influence of a tumor angiogenesis factor.^{6,7,17} Another theory was that of Russell and Rubinstein,¹⁶ who rejected the concept of two different lesions, diagnosing instead either "hypervascularized tumor or undue glial reaction." Since concomitant histopathological sampling and radiographic studies throughout the duration of these lesions have not been performed in any of these cases, these proposals remain speculative.

Of the cases reviewed, a vascular malformation was not initially diagnosed by angiography in five of 11 cases^{3,5,8,14} or with CT^{1,5,11,12} (Table 3). In a case cited by Heffner, *et al.*,⁸ the angiographic pattern of abnormal vasculature associated with a frontal mass was considered to be a "vascular glioma." In the two cases of Fischer, *et al.*,⁵ the initial angiograms were normal in one and showed mass effect but no "pathologic vessels, early draining veins, or tumor blush" in the other. In the six cases in which the vascular malformation was diagnosed by angiography, a separate mass lesion was suspected in only two: by ventriculogram in one⁴ and by CT in the other.¹²

In the present case, the angiographically abnormal

vessels, initially felt to represent an AVM, regressed and disappeared over a period of 22 months. Within the same period a progressively enlarging hypovascular mass developed at the same site. Two biopsies with subtotal resection, obtained 6 months apart, confirmed a diagnosis of anaplastic astrocytoma without evidence of a vascular malformation. It is our contention that this case represents an AVM in which a malignant (anaplastic) astrocytoma grew, replacing the AVM.

We realize that this case may just as well represent a single lesion (anaplastic astrocytoma) in which the vascular pattern initially simulated the angiographic appearance of an AVM. It is suggested that future research may include, among other goals, the search for a tumor angiogenic factor in resected vascular malformations in the hope of defining a possible relationship between the two lesions.

Acknowledgment

The authors wish to thank Dr. Charles B. Wilson for his review of this case and recommendations regarding management of the patient.

References

1. Chee CP, Johnson R, Doyle D, et al: Oligodendroglioma and cerebral cavernous angioma. Case report. *J Neurosurg* 62:145-147, 1985
2. Crowell RM, DeGirolami U, Sweet WH: Arteriovenous malformation and oligodendroglioma. Case report. *J Neurosurg* 43:108-111, 1975
3. Dykstra PC: The pathology of acoustic neuromas. *Arch Otolaryngol* 80:605-616, 1964
4. Fine RD, Paterson A, Gaylor JB: Recurrent attacks of subarachnoid haemorrhage in the presence of a cerebral angioma and intraventricular oligodendroglioma. *Scot Med J* 5:342-346, 1960
5. Fischer EG, Sotrel A, Welch K: Cerebral hemangioma with glial neoplasia (angioglioma?). Report of two cases. *J Neurosurg* 56:430-434, 1982
6. Folkman J: Tumor angiogenesis. *Adv Cancer Res* 19:331-358, 1958
7. Folkman J, Merler E, Abernathy C, et al: Isolation of a tumor factor responsible for angiogenesis. *J Exp Med* 133:275-288, 1971
8. Heffner RR Jr, Porro RS, Deck MDF: Benign astrocytoma associated with arteriovenous malformation. Case report. *J Neurosurg* 35:229-233, 1971
9. Kasantikul V, Netsky MG: Combined neurilemmoma and angioma. Tumor of ectomesenchyme and a source of bleeding. *J Neurosurg* 50:81-87, 1979
10. Kumar AJ, Viñuela F, Fox AJ, et al: Unruptured intracranial arteriovenous malformations do cause mass effect. *AJNR* 6:29-32, 1985
11. Licata C, Pasqualin A, Freschini A, et al: Management of associated primary cerebral neoplasms and vascular malformations. 2: Intracranial arterio-venous malformations. *Acta Neurochir* 83:38-46, 1986
12. Martinez-Lage JF, Poza M, Esteban JA, et al: Subarachnoid hemorrhage in the presence of a cerebral arteriovenous malformations and an intraventricular oligodendroglioma: case report. *Neurosurgery* 19:125-128, 1986
13. Nyström S: Pathological changes in blood vessels of human glioblastoma multiforme: comparative studies using plastic casting, angiography, light microscopy, and elec-

AVM and glioma at same cerebral site

- tron microscopy, and with reference to some other brain tumours. *Acta Pathol Microbiol Scand* **49** (Suppl 137): 1-83, 1960
14. Raynor RB, Kingman AF Jr: Hemangioblastoma and vascular malformations as one lesion. *Arch Neurol* **12**: 38-48, 1965
 15. Rigamonti D, Spetzler RF, Drayer BP, et al: Appearance of venous malformations on magnetic resonance imaging. *J Neurosurg* **69**:535-539, 1988
 16. Russell DS, Rubenstein LJ: *Pathology of Tumors of the Nervous System*, ed 2. Baltimore: Williams & Wilkins, 1963, p 122
 17. Suddith RL, Kelly PJ, Hutchison HT, et al: *In vitro* demonstration of an endothelial proliferation factor produced by neural cell lines. *Science* **190**:682-684, 1975
 18. Tönnis W: Die bedeutung der "Angiographie cerebrale" für dieindikationsstellung zur operation von hirngeschwulsten. *Lisboa Med* **14**:773-780, 1937
 19. Welcher ER, Seidel K: Kombination eines Angioma arteriovenosum aneurysmaticum mit einem Astrocytom. *Dtsch Z Nervenheilk* **189**:231-239, 1966
 20. White RJ, Kernohan JW, Wood MW: A study of 50 intracranial vascular tumors found incidentally at necropsy. *J Neuropathol Exp Neurol* **17**:392-398, 1958
 21. Zuccarello M, Giordano R, Scanarini M, et al: Malignant astrocytoma associated with arteriovenous malformation. Case report. *Acta Neurochir* **50**:305-309, 1979

Manuscript received June 19, 1989.

Accepted in final form October 4, 1989.

Address reprint requests to: Robert Goodkin, M.D., Department of Neurological Surgery, Harborview Medical Center, ZA-86, 325 Ninth Avenue, Seattle, Washington 98104.