

AICA syndrome with facial palsy following vertigo and acute sensorineural hearing loss

Tomoko Ikegami-Takada, Masahiko Izumikawa*, Tadashi Doi, Yohei Takada, Koichi Tomoda

Department of Otolaryngology, Kansai Medical University, 2-3-1 Shinmachi, Hirakata, Osaka 573-1191, Japan

Received 1 September 2010; received in revised form 28 July 2011; accepted 29 July 2011

Available online 20 August 2011

Abstract

We report a case of infarction of the anterior inferior cerebellar artery (AICA) with peripheral facial palsy following vertigo and acute sensorineural hearing loss. A 39-year-old female presented with vertigo and sudden hearing loss, tinnitus, and aural fullness of the right ear. An audiogram revealed a severe hearing loss at all tested frequencies in the right ear. Spontaneous nystagmus toward the left side was also observed. Otoneurological examinations showed sensorineural hearing loss of the right ear and horizontal and rotatory gaze nystagmus toward the left side, and a caloric reflex test demonstrated canal paresis. Initially, we diagnosed the patient for sudden deafness with vertigo. However, right peripheral facial palsy appeared 2 days later. An eye tracking test (ETT) and optokinetic pattern test (OKP) showed centralis abnormality. The patient's brain was examined by magnetic resonance imaging (MRI) and magnetic resonance angiography (MRA) and showed an infarction localized in the pons and cerebellum. MRI and MRA revealed infarction of the right cerebellar hemisphere indicating occlusion of the AICA. Consequently, the patient was diagnosed with AICA syndrome but demonstrated regression following steroid and edaravone treatment. We suggest that performing MRI and MRA in the early stage of AICA syndrome is important for distinguishing cerebellar infarction resulting from vestibular disease.

© 2011 Elsevier Ireland Ltd. All rights reserved.

Keywords: AICA; Facial palsy; Vertigo; Sensorineural hearing loss; MRI; MRA

1. Introduction

Sudden deafness or Ménière's disease is frequently diagnosed in the case of sudden hearing loss, tinnitus, and vertigo. However the symptoms are sometimes caused by an acoustic tumor or cerebrovascular disorder. Infarction in the posterior fossa occurs most commonly in the distribution of the posterior inferior cerebellar artery and is known as Wallenberg syndrome. On the other hand, occlusion of the anterior inferior cerebellar artery (AICA) is rare. In 1943, Adams was first to describe the clinical syndrome of an AICA infarction [1]. Subsequent reports established the pathological features in AICA territory occlusion [2–6]. Recently, AICA infarction has been reported to be associated with only sudden hearing loss and vertigo [7–

11]. In this paper, we report a case of AICA syndrome with peripheral facial palsy after experiencing vertigo and acute sensorineural hearing loss in a patient without a long-standing history or cerebellar ataxia.

2. The case

A 39-year-old female (height: 165 cm, weight: 51 kg) presented with a chief complaint of rotatory vertigo and aural fullness of the right ear experienced for 2 days. She had no past history of hypertension or diabetes mellitus. The patient experienced rotatory vertigo accompanied by nausea and vomiting that occurred when she stood up suddenly. She also noticed severe vertigo and aural fullness of the right ear and thus visited our hospital. On physical examination, a continuous left-beating horizontal torsional spontaneous nystagmus with Frenzel glasses was

* Corresponding author. Tel.: +81 72 804 0101.

E-mail address: masha722@hotmail.com (M. Izumikawa).

observed along with tilting to the right when walking. She showed no symptoms of ophthalmoplegia, dysarthria, facial numbness or paralysis, Horner’s syndrome, or cerebellar dysmetria. Her eardrums, nose, throat, and neck showed no abnormal appearance. In the next day, pure tone audiometry (PTA) showed a sensorineural hearing loss of 80 dB in the right ear (Fig. 1(a)). The

tympanogram was type A which indicated the eardrum to have normal elasticity. Stapedial reflex thresholds of each ear at frequencies of 500, 1000, 2000, and 4000 Hz were also normal. The finding of the nystagmus with Frenzel Glasses showed a positional vertical nystagmus in the left side of the head position in the supine position (Fig. 2). Caloric responses to cold water simulation were poor in 5°/s in the right ear. The patient’s laboratory data and viral serology were unremarkable. An eye tracking test (ETT) showed an abnormal saccadic pursuit and an optokinetic pattern (OKP) test revealed ocular dysmetria as a centralis abnormality (Fig. 3). At first in her visit in our hospital, we consequently diagnosed right sudden hearing loss with vertigo and hospitalized the patient for steroid pulse therapy with predonine and intravenous edaravone for one week. In the morning after 7 days, except continuous vertigo for one more week, the patient had right facial palsy and her facial score according to the House-Brackmann method was grade V. Considering her severe idiopathic facial palsy, we changed the treatment to high-dose steroid therapy as an alternative Stennert’s method for 2 weeks. We also suspected a central nervous system (CNS) disorder, although such a disorder would be an unlikely candidate for a peripheral condition. Three days after experiencing vertigo and severe hearing loss, an axial T2- and diffusion-weighted magnetic resonance imaging (MRI) scan of the brain revealed acute infarction in the right cerebellar hemisphere (Fig. 4). Magnetic resonance angiography (MRA) scan of the brain demonstrated moderate stenosis of the right AICA (Fig. 5(a)). From the same day, the patient was administered heparin for 1 week. One week later, a second brain MRA showed reperfusion of the AICA (Fig. 5(b)). A follow-up PTA revealed that the hearing loss in the right side had

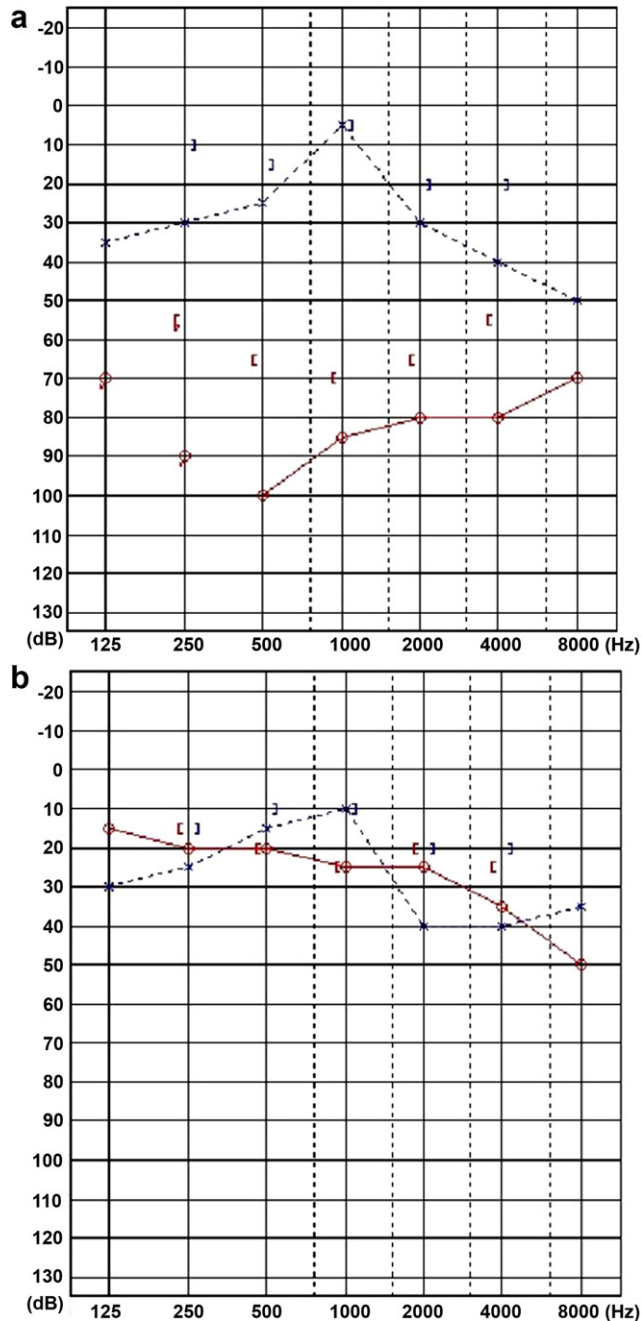


Fig. 1. Audiological findings of the right side in the masking level of 80 dB in right bone conduction. Pure tone audiometry (PTA) showed severe hearing loss (a). PTA following treatment showed recovery from hearing loss (b).

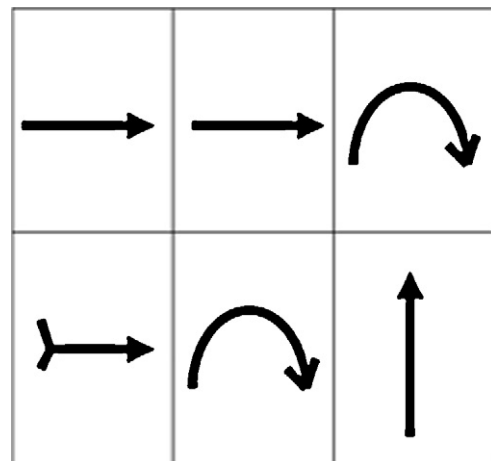


Fig. 2. The finding of the nystagmus with Frenzel Glasses showed vertical nystagmus in the left side of head position in the supine position, which appeared to be caused by a central disorder.

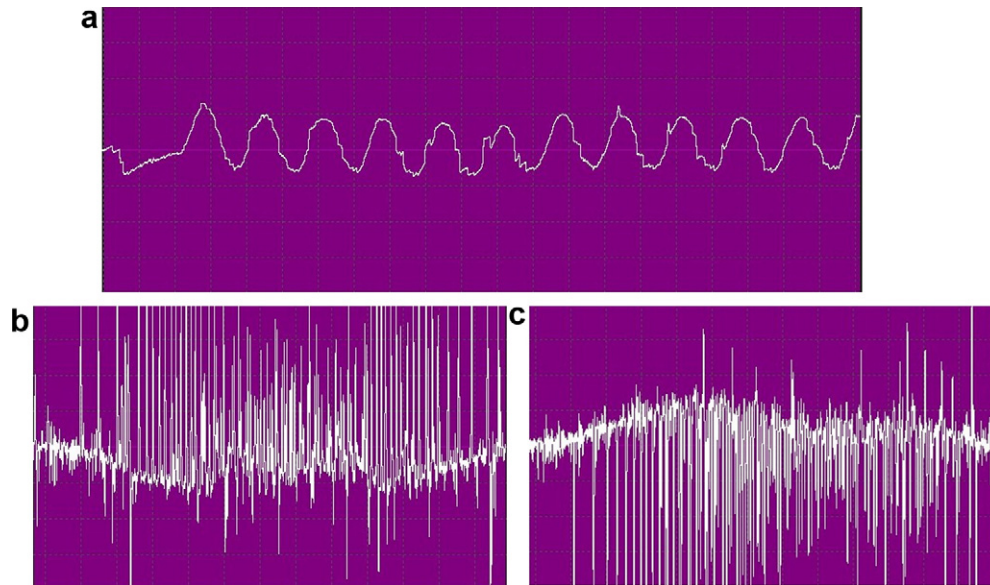


Fig. 3. An ETT showed an abnormal saccadic pursuit (a) and an OKP test revealed ocular dysmetria as a centralis abnormality (b: right), (c: left).

improved to 25 dB (Fig. 1(b)). Subsequently, the patient's vertigo, severe hearing loss, and facial palsy improved completely.

3. Discussion

In this case of AICA syndrome, at first, the patient presented with unilateral sudden deafness and vertigo with horizontal and torsional components that indicated a peripheral origin. Additional focal neurologic deficits such as cerebellar dysmetria, facial palsy or numbness, and dysphagia were not apparent. However, about one week later, unilateral facial palsy occurred. Although the patient was young and had no known history of hypertension or diabetes, the late occurrence of facial palsy following sudden deafness and vertigo was sufficient to alarm the physician to the possibility of a vascular incident, which resulted from insufficient blood supply from the internal auditory artery of the AICA. Furthermore, the spontaneous nystagmus that was observed for more than a week is unlikely to result from peripheral vestibulopathy [12]. Such delayed damage also increases the suspicion of a central origin. The internal auditory artery, which stems from the AICA, is primarily an end artery that supplies the inner ear and vestibulocochlear nerve [13,14]. Although inner ear symptoms of sudden deafness with vertigo as a sole manifestation of AICA infarction are rarely reported [8], the present study revealed that AICA infarction can cause inner ear symptoms as well as brainstem symptoms such as sensory hearing loss, lateral gaze palsy, and Horner's syndrome

[1]. Only one other study of AICA infarction presenting with auditory and vestibular symptoms and no brainstem signs has been reported [7]. Inner ear disorders usually occur as prodromal signs preceding neurologic signs. In most cases, patients develop symptoms of ataxia, dysmetria, diplopia, facial palsy, or other cerebellar dysfunction on several days following initial subsiding of the inner ear symptoms. For patients at potential high risk for vascular insufficiency, close observation for developing symptoms and follow-up neurologic examinations are important. Both MRI and MRA scans of the brain were invaluable procedures for obtaining the correct diagnosis in our patient. Usually, we depend on CT scans of the brain for evaluation because of the high expenses of MRI. Here, an unusual duration of vertigo and late facial palsy prompted the faculty to insist on further examination of the brain by MRI and MRA. Usually, inner ear symptoms with AICA infarction do not improve and complications remain indefinitely. However, in our case, the early judgment and treatment prevented the occurrence of serious conditions in the patient.

4. Summary

We report a case of AICA syndrome in a 39-year-old patient without a history of risk factors. Taken together, if patients are suspected of having a CNS disorder, they should undergo brain MRI and MRA as soon as possible. The possibility of AICA infarction should be evaluated carefully, even in young patients without a history of high-risk factors of vascular disease.

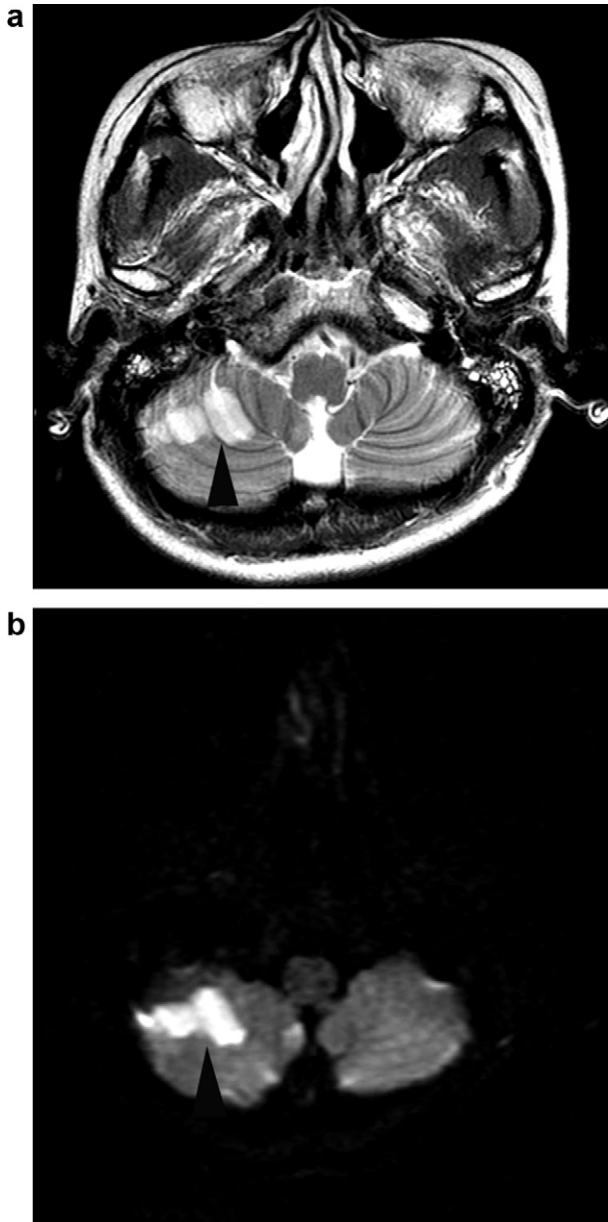


Fig. 4. Brain magnetic resonance imaging (MRI) scans. Axial T2-weighted brain MRI revealed a hyperintense area in the right cerebellar hemisphere (a). Diffusion-weighted brain MRI showed a hyperintense focus in the same area as a (b).

Conflict of interest

None.

References

[1] Adams RD. Occlusion of the anterior inferior cerebellar artery. *Arch Neurol Psychiatry* 1943;49:765–70.
 [2] Gillilan LA. The correlation of the blood supply to the human brain stem with clinical brain stem lesions. *J Neuropathol Exp Neurol* 1964;78–108.

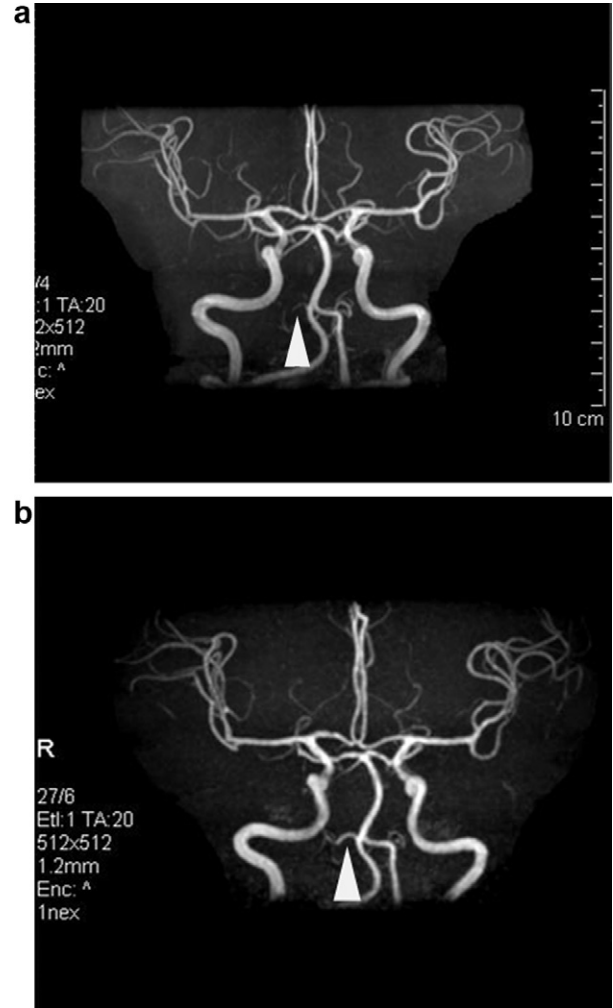


Fig. 5. Brain magnetic resonance angiography (MRA) scans. MRA before the treatment revealed moderate stenosis of the right AICA (a). MRA following treatment showed reperfusion of the AICA (b).

[3] Amarenco P, Hauw JJ, Gautier JC. Arterial pathology in cerebellar infarction. *Stroke* 1990;21:1299–305.
 [4] Amarenco P, Rouillet E, Hommel M, Chaine P, Marteau R. Infarction in the territory of the medial branch of the posterior inferior cerebellar artery. *J Neurol Neurosurg Psychiatry* 1990;53:731–5.
 [5] Atkinson WJ. The anterior inferior cerebellar artery. Its variations, pontine distribution, and significance in the surgery of cerebello-pontine angle tumors. *J Neurol Neurosurg Psychiatry* 1949;12: 137–51.
 [6] Oas JG, Baloh RW. Anterior inferior cerebellar artery syndrome. *Neurology* 1991;41(Suppl. 1):126.
 [7] Yi HA, Lee SR, Lee H, Ahn BH, Park BR, Whitman GT. Sudden deafness as a sign of stroke with normal diffusion-weighted brain MRI. *Acta Otolaryngol* 2005;125:1119–21.
 [8] Lee H, Ahn BH, Baloh RW. Sudden deafness with vertigo as a sole manifestation of anterior inferior cerebellar artery infarction. *J Neurol Sci* 2004;222:105–7.
 [9] Lee H, Sohn SI, Jung DK, Cho YW, Lim JG, Yi SD, et al. Sudden deafness and anterior inferior cerebellar artery infarction. *Stroke* 2002;33:2807–12.

- [10] Hinojosa R, Kohut RI. Clinical diagnosis of anterior inferior cerebellar artery thrombosis: autopsy and temporal bone histopathology study. *Ann Otol Rhinol Laryngol* 1990;99:261–71.
- [11] Matsushita K, Naritomi H, Kazui S, Watanebe Y, Okazaki H, Kuriyama Y, et al. Infarction in the anterior inferior cerebellar artery territory: magnetic resonance imaging and auditory brain stem responses. *Cerebrovasc Dis* 1993;3:206–12.
- [12] Son EJ, Bang JH, Kang JG. Anterior inferior cerebellar artery infarction presenting with sudden hearing loss and vertigo. *Laryngoscope* 2007;117:556–8.
- [13] Grad A, Baloh RW. Vertigo of vascular origin: clinical and electro-nystagmographic features in 84 cases. *Arch Neurol* 1989;46:281–4.
- [14] Mazzoni A. Internal auditory artery supply to the petrous bone. *Ann Otol Rhinol Laryngol* 1972;81:13–21.