

Cerebral Infarction in a Young Man Using High-dose Anabolic Steroids

Yoshiaki Shimada, MD, Asako Yoritaka, MD, PhD, Yasutaka Tanaka, MD, PhD, Nobukazu Miyamoto, MD, PhD, Yuji Ueno, MD, PhD, Nobutaka Hattori, MD, PhD, and Urabe Takao, MD, PhD

Anabolic androgenic steroid (AAS) abuse has increased among athletes in recent years. However, AAS abuse can increase hypercoagulopathy and cause cerebrovascular disease. We report a case of a 27-year-old man who had right hemiparesis, hemianopia, dysarthria, and double vision in the middle of muscle training. He suspected acute disseminated encephalomyelitis at first, because of a preceding respiratory infection. However, extensive work-up was performed, including brain magnetic resonance imaging, transcranial Doppler and transesophageal echocardiography, confirming the final diagnosis of cardioembolic stroke. Physicians should be aware that cerebrovascular disease may be a side effect of AAS, even in younger populations. **Key Words:** Anabolic androgenic steroid—cardioembolic stroke—deep vein thrombosis—patent foramen ovale—transesophageal echocardiography. © 2012 by National Stroke Association

Strokes occur relatively infrequently in young adults (ie, individuals who are 15-45 years old). For instance, the prevalence of stroke in young adults has been reported to be twice that of multiple sclerosis in the same age group. Because young stroke patients are usually healthy, in general they have a better prognosis than their older counterparts. Nonetheless, in one large study, 5% of young patients presenting with stroke died, and 15% had some sort of severe disability.¹ As early stroke intervention becomes a practical reality in many medical centers, an understanding of the various causes of stroke and their imaging findings

becomes increasingly important in making the correct diagnosis and in promptly initiating the appropriate treatment. This statement is pertinent for stroke patients of any age but is particularly true for young patients, who, even when surviving the initial event, may face long-term disability and dependence on family or society.

High-dose anabolic androgenic steroid (AAS) abuse, which is used for muscle training, can increase hypercoagulopathy^{2,3} and cause cerebrovascular disease.⁴ We report a patient who was diagnosed with cardioembolic stroke related to the abuse of AASs.

Case Report

In April 2009, a 27-year-old man with an American father and a mother who was half Japanese was admitted to a local emergency hospital because he suddenly became aware of right hemiparesis, homonymous hemianopia, dysarthria, tinnitus, and double vision in the middle of muscle training. Upon arrival at the local hospital, these symptoms except diplopia were improved. The next morning, diplopia improved as well. A magnetic resonance imaging (MRI) scan of the brain revealed

From the Department of Neurology, Juntendo University School of Medicine, Tokyo, Japan.

Received June 24, 2011; revision received July 21, 2011; accepted July 23, 2011.

Address correspondence to: Nobukazu Miyamoto, MD, PhD, Department of Neurology, Juntendo University School of Medicine, 3-1-3 Hongo, Bunkyo-ku, Tokyo 113-0033, Japan. E-mail: nobu-m@juntendo.ac.jp.

1052-3057/\$ - see front matter

© 2012 by National Stroke Association

doi:10.1016/j.jstrokecerebrovasdis.2011.07.013

a high-intensity area in the right cerebellum, right occipital lobe, and left thalamus on T2-weighted and fluid attenuated inversion recovery (FLAIR) imaging. He had a respiratory infection a week after the onset of neurologic findings. Cerebrospinal fluid protein was 74 mg/dL, with normal cellularity in lumbar puncture. He was referred to our hospital for further examination because of suspected acute disseminated encephalomyelitis. On admission, his general examination and neurologic signs were normal. His hobby was muscle training while taking various AASs (methasterone and prostanazol) for the past 6 months. He was a nonsmoker, had no alcohol abuse, and had no history of cardioembolic factors. Routine blood studies were normal. Antibodies in the serum for HIV, syphilis, neurotrophic viruses, thyroid disease, and autoimmune disease (antinuclear, anti-SS-A/SS-B antibodies, MPO-ANCA, and PR3-ANCA) were unremarkable. The hypercoagulability factor (including tests for fibrin degradation product, D-dimer, thrombin-antithrombin complex, protein C, protein S, antithrombin III, factor V Leiden, anticardiolipin antibodies, and antiphospholipid antibodies) was normal. Soluble fibrin monomer complex was not examined. MRI with and without gadolinium enhancement revealed that there were high-intensity areas in the right cerebellum, right occipital lobe, and left thalamus on FLAIR imaging, which were hyperintense on diffusion weighted image, and enhancement by gadolinium on T1-weighted imaging was also seen in the right occipital lobe (Fig 1, A). Magnetic resonance angiography, three-dimensional computed tomography angiography, and

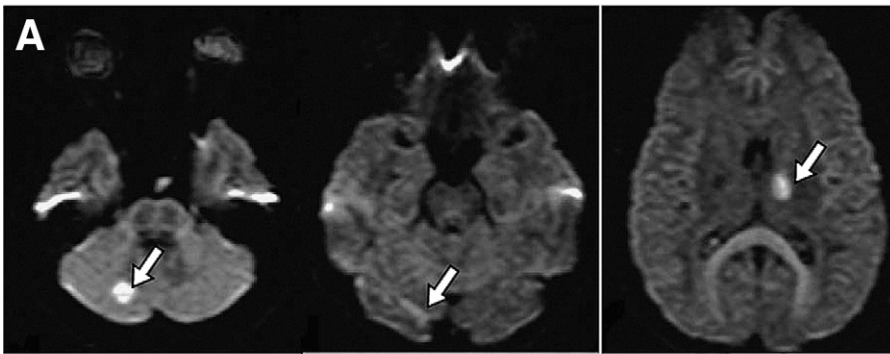
carotid ultrasonography revealed no narrowing of blood vessels and disruption. We initiated aspirin treatment for stroke of unknown etiology. We performed transcranial Doppler and transesophageal echocardiography (TEE) to identify the presence of atrial septal aneurysm (ASA) and large patent foramen ovale (PFO; Fig 1, B). The presence of deep vein thrombosis (DVT) was examined under duplex ultrasonography and visualization of thrombi was not observed, but dilation of vein and smoke-like echo was observed. These findings led us to consider the diagnosis of cardiogenic embolism (CE) in association with use of high-dose AASs and PFO and ASA. After the patient stopped taking AASs, recurrence of cerebral infarction has not occurred until now, and the improvement of smoke-like echo was shown under duplex ultrasonography. In laboratory findings, we could not detect the increasing coagulation in a healthy young man with PFO and ASA. However, imaging studies revealed the presence of suspected lower limb DVT caused by various AASs. The patient will discontinue aspirin therapy.

Discussion

Our patient developed cerebrovascular disease in association with use of high-dose AASs and PFO and ASA. To our knowledge, this is the first reported case of cryptogenic stroke caused by the abuse of AASs.

AASs are synthetic derivatives of the male hormone testosterone. Testosterone has potent anabolic effects on the musculoskeletal system, including an increase in

DWI



TEE

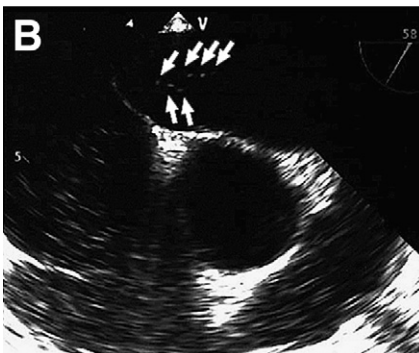


Figure 1. Magnetic resonance imaging with and without gadolinium enhancement revealed that there were high-intensity areas in the right cerebellum, right occipital lobe, and left thalamus on diffusion-weighted imaging (A). The contrast studies using agitated saline with Valsalva maneuver show a large shunt from patent foramen ovale and atrial septal aneurysm on transesophageal echocardiography (B).

lean body mass, a dose-related hypertrophy of muscle fibers, and an increase in muscle strength. On the other hand, anabolic steroids may cause arterial hypertension, cardiopathy, atherosclerosis, hypercoagulopathy, cerebrovascular disease, hepatocellular carcinoma, and psychiatric and behavioral disturbances.⁵ Experimental evidence suggests that testosterone stimulates thrombus formation by suppressing prostacyclin production in arterial smooth muscle cells in rats.⁶ However, there is a discussion about why anabolic steroids cause cerebral infarction although a clear mechanism has not been elucidated. Our case might potentially elucidate the mechanism.

The definition of paradoxical brain embolism (PBE) is the presence of thrombus in the venous system that passes through a right-to-left shunt (RLS), such as the PFO, resulting in brain infarction. Criteria for diagnosis of PBE were established as: 1) brain images suggesting embolic stroke; 2) the presence of DVT or PE; and 3) absence of other embolic sources, such as atrial fibrillation, sick sinus syndrome, dilated cardiomyopathy, acute myocardial infarction, prosthetic heart valves, intracardiac thrombus, complicated plaques in the aortic arch, and arterial stenotic lesion in the corresponding artery.⁷ PFO has been identified as a potential risk factor for ischemic stroke, particularly in young adults.⁸ PFO is also not uncommon in normal subjects, with a frequency of 24% to 29% in autopsy studies.⁹ Several studies have shown that ASA is strongly linked with PFO.¹⁰ Embolic stroke patients without risk factors should therefore be investigated for RLS.

This is a case of a healthy young man with no known risk factors for stroke other than the use of high-dose AASs that were used for muscle training. We performed TEE, evaluated ASA and large PFO, and diagnosed CE. Training with AASs has become widespread in young

people and athletes, and physicians should be aware of the side effects of AASs.

References

1. Bogousslavsky J, Regli F. Ischemic stroke in adults younger than 30 years of age. Cause and prognosis. *Arch Neurol* 1987;44:479-482.
2. Sahraian MA, Mottamedi M, Azimi AR, et al. Androgen-induced cerebral venous sinus thrombosis in a young body builder: Case report. *BMC Neurol* 2004;4:22.
3. Dickerman RD, McConathy WJ, Schaller F, et al. Cardiovascular complications and anabolic steroids. *Eur Heart J* 1996;17:1912.
4. Frankle MA, Eichberg R, Zachariah SB. Anabolic androgenic steroids and a stroke in an athlete: Case report. *Arch Phys Med Rehabil* 1988;69:632-633.
5. Santamarina RD, Besocke AG, Romano LM, et al. Ischemic stroke related to anabolic abuse. *Clin Neuropharmacol* 2008;31:80-85.
6. Nagelberg SB, Laue L, Loriaux DL, et al. Cerebrovascular accident associated with testosterone therapy in a 21-year-old hypogonadal man. *N Engl J Med* 1986;314:649-650.
7. Ueno Y, Iguchi Y, Inoue T, et al. Paradoxical brain embolism may not be uncommon-prospective study in acute ischemic stroke. *J Neurol* 2007;254:763-766.
8. Cabanes L, Mas JL, Cohen A, et al. Atrial septal aneurysm and patent foramen ovale as risk factors for cryptogenic stroke in patients less than 55 years of age. A study using transesophageal echocardiography. *Stroke* 1993;24:1865-1873.
9. Hagen PT, Scholz DG, Edwards WD. Incidence and size of patent foramen ovale during the first 10 decades of life: An autopsy study of 965 normal hearts. *Mayo Clin Proc* 1984;59:17-20.
10. Mas JL, Arquizan C, Lamy C, et al. Recurrent cerebrovascular events associated with patent foramen ovale, atrial septal aneurysm, or both. *N Engl J Med* 2001;345:1740-1746.