



Case report

Utility of bilateral Bispectral index (BIS) monitoring in a comatose patient with focal nonconvulsive status epilepticus

José L. Fernández-Torre^{a,c,d,*}, Miguel A. Hernández-Hernández^{b,d}

^a Department of Clinical Neurophysiology, Marqués de Valdecilla University Hospital, Santander, Cantabria, Spain

^b Department of Intensive Medicine, Marqués de Valdecilla University Hospital, Santander, Cantabria, Spain

^c Department of Physiology and Pharmacology, University of Cantabria (UNICAN), Santander, Cantabria, Spain

^d Instituto de Formación e Investigación Marqués de Valdecilla (IFIMAV), Santander, Spain

ARTICLE INFO

Article history:

Received 7 July 2011

Received in revised form 27 August 2011

Accepted 4 September 2011

Keywords:

Nonconvulsive status epilepticus

Nonconvulsive seizures

Bispectral index

Coma

Profound sedation

ABSTRACT

We report the case of a patient with an extensive right cerebral hematoma complicated by focal nonconvulsive status epilepticus (NCSE) in whom the use of the new bilateral BIS-Vista™ monitor was helpful in managing profound sedation and antiepileptic treatment in the absence of continuous EEG monitoring (CEEG). The analysis of color density spectral array (CDSA) showed stereotyped changes indicative of recurrent focal nonconvulsive seizures (NCSz) and NCSE. We noted a close correlation between NCSz and BIS value changes. EEGs during working hours always confirmed the persistence of focal NCSE. After several days of sedation, CDSA disclosed a gradual resolution of NCSE that was also confirmed by electroencephalography. The patient died of cardiorespiratory complications a few days later.

© 2011 British Epilepsy Association. Published by Elsevier Ltd. All rights reserved.

1. Case report

A 69-year-old woman was admitted to our intensive care unit (ICU) with the diagnosis of right fronto–parieto–temporal hematoma and subarachnoid hemorrhage secondary to the rupture of a middle cerebral artery aneurysm. She underwent endovascular embolization of the aneurysm and surgical evacuation of the hematoma. Subsequently, she was transferred to the ICU where intravenous sedation with propofol (2.0 mg/kg/h), midazolam (0.1 mg/kg/h) and prophylactic antiepileptic treatment with levetiracetam (2000 mg/24 h) were started. Three days later, a portable electroencephalogram (EEG) showed a burst-suppression pattern but seizures were absent. Over the next two days although sedation was stopped, she remained in coma (Glasgow Coma Score 3). EEG revealed recurrent and stereotyped right frontal nonconvulsive seizures (NCSz) spreading to the contralateral frontal lobe (Fig. 1a). These findings were consistent with a diagnosis of focal nonconvulsive status epilepticus (NCSE) in a comatose subject by the criteria of Young et al.,¹ and subsequently modified by Chong and Hirsch.² In addition to the spontaneous NCSz,

stimulus-induced, focal left hemispheric NCSz also occurred. In the view of these EEG findings, profound sedation with propofol and midazolam was again started. Since we do not have continuous EEG monitoring (CEEG) in our hospital and emergency EEG is only available during normal working hours, we proposed using the newest bilateral Bispectral index (BIS)-Vista™ monitor (Aspect Medical Systems Inc., Norwood, MA) version 3.00 to guide anesthetic sedation and to detect bouts of NCSz and NCSE. BIS-Vista sensors were bilaterally placed on the forehead according to manufacturer's guidelines. During the subsequent days, the patient remained sedated and analysis of color density spectral array (CDSA) showed stereotyped changes indicative of recurrent focal NCSz and NCSE (Fig. 1b). We noted a close correlation between NCSz and BIS value changes. The signal quality index (SQI-BIS) was acceptable (>50) as would be expected in relation to focal seizures without motor activity. EEGs carried out during working hours confirmed the persistence of focal NCSE. After several days of sedation, CDSA disclosed a gradual resolution of NCSE also confirmed by EEG (Fig. 1c). Sedation with propofol and midazolam was stopped, seizures did not recur, and the patient minimally improved, remaining in vegetative state. Unfortunately, she died of cardiorespiratory complications a few days later.

2. Discussion

We report the case of a patient with an extensive right cerebral hematoma complicated by focal NCSE in whom the use of the new

* Corresponding author at: Department of Clinical Neurophysiology, "Marqués de Valdecilla" University Hospital, Avda. Valdecilla, s/n, 39008 Santander, Cantabria, Spain. Tel.: +34 942 202520x72674; fax: +34 942 315095.

E-mail addresses: jlfernandez@humv.es, ftorrenfc@hotmail.com (J.L. Fernández-Torre).

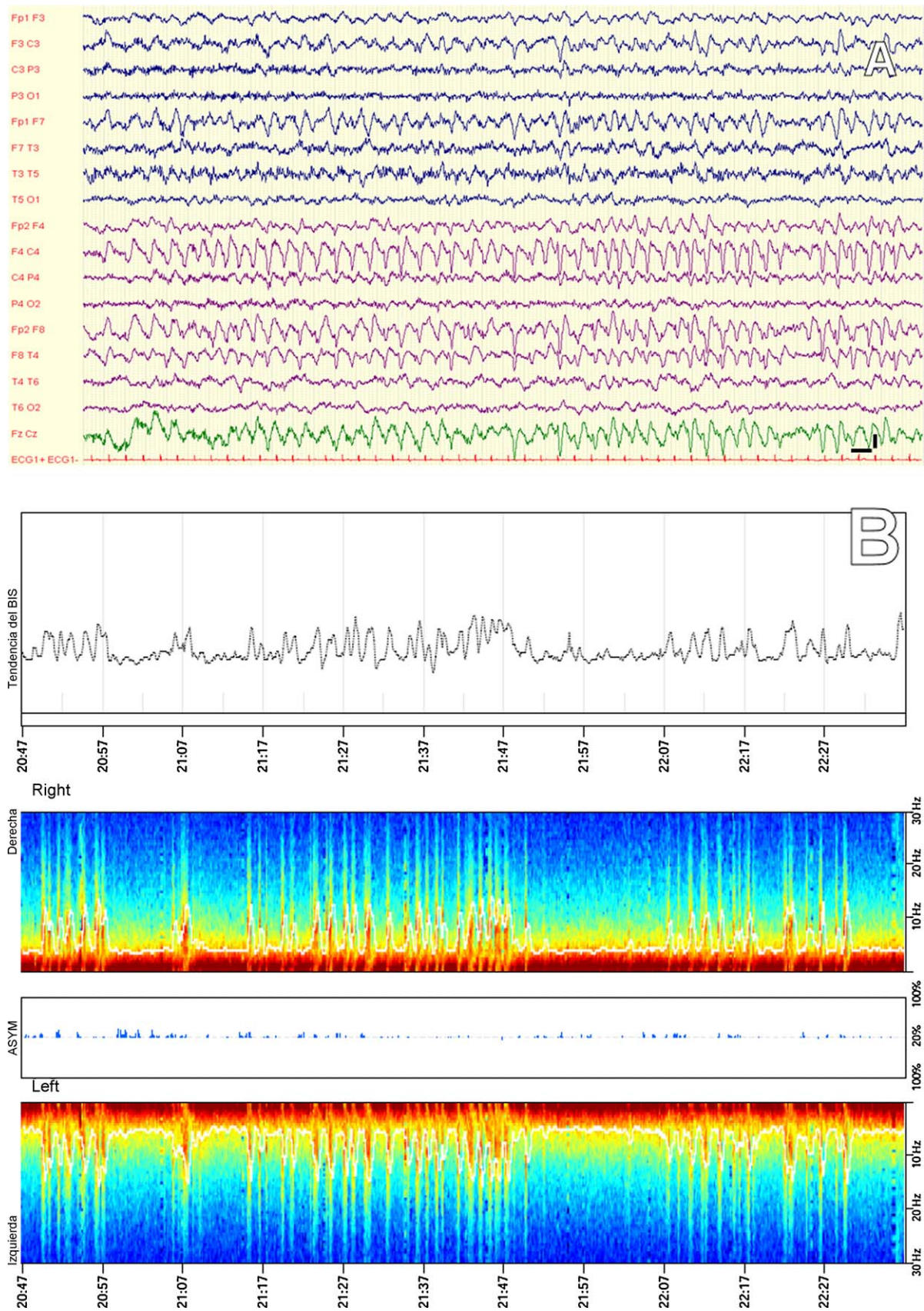


Fig. 1. (a) Digital EEG showing the existence of recurrent focal nonconvulsive seizures involving the right frontal lobe and spreading to the contralateral side. LF: 0.53 Hz; HF: 70 Hz; NF: 50 Hz; vertical bar: 100 μ V; horizontal bar: 1 s. (b) CSDA revealing the occurrence of recurrent seizures in keeping with the diagnosis of NCSE and (c) CSDA showing the resolution of the NCSE. Lower power: blue color; Higher power: red color. (For interpretation of the references to color in this figure legend, the reader is referred to the web version of the article.)

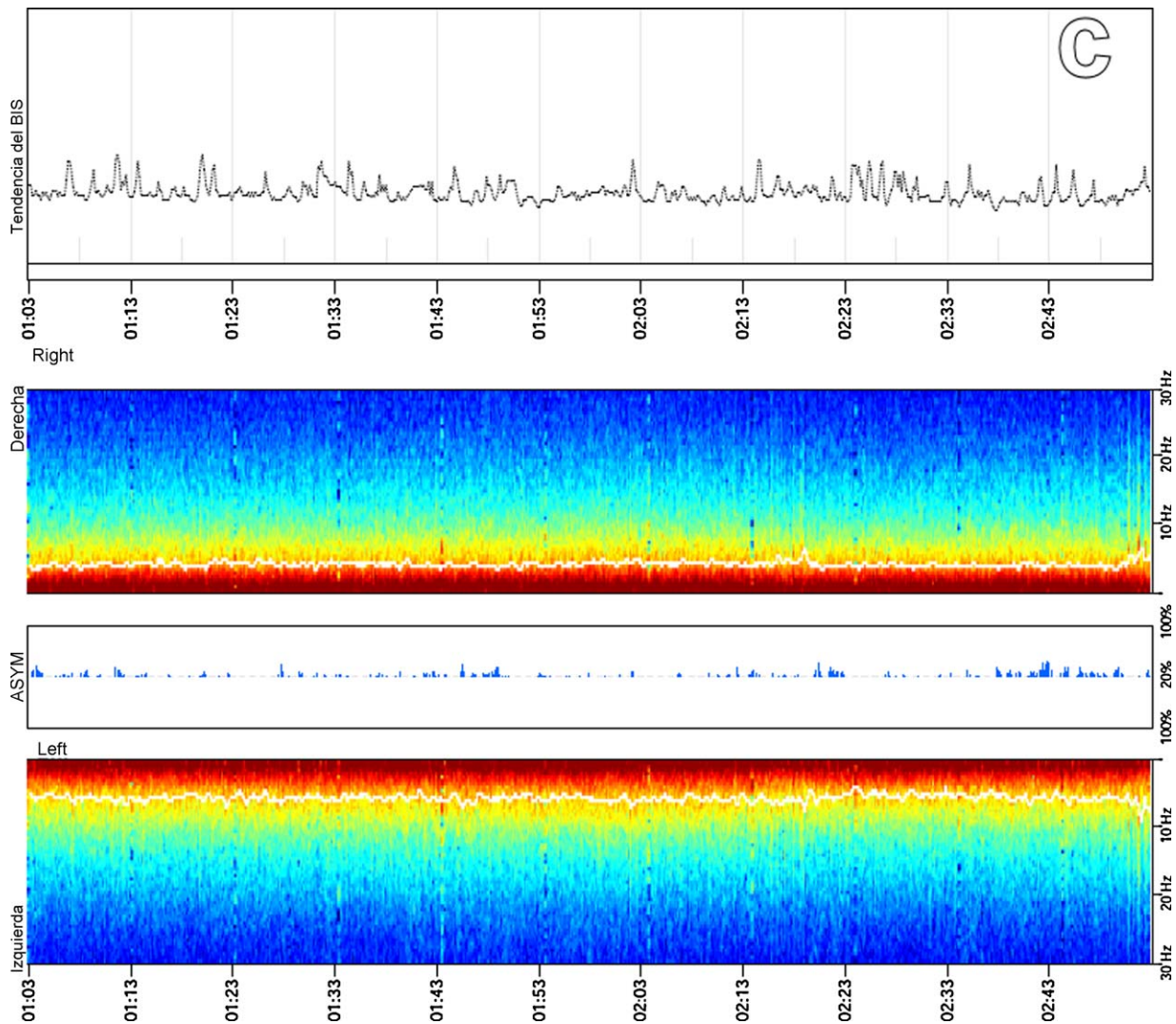


Fig. 1. (Continued).

bilateral BIS-Vista™ monitor was helpful in managing profound sedation and antiepileptic treatment in the absence of CEEG. To the best of our knowledge this is the first description in which CSDA using a bilateral BIS monitor, revealed frontal NCSE. Nowadays CEEG can greatly enhance the assessment and therapeutic approach of patients with severe brain injury,³ and is considered the best method for detecting NCSz and NCSE in comatose patients.⁴ However, this neurophysiologic technique is largely restricted to teaching hospitals and widespread use is limited. The newest BIS-Vista™ monitor is a device which offers an EEG-derived variable designed to assess responses to sedation and anesthesia. BIS is a continuous and simple method which provides a numeric value between 0 (deep sedation with isoelectric EEG) and 100 (patient fully awake). In addition, the EEG recorded by the BIS is continuously displayed (BIS-EEG), and others parameters including SQI-BIS, suppression ratio (SR-BIS), spectral edge frequency (SEF-BIS), frontal electromyogram (EMG-BIS) and CDSA are also supplied. CDSA applies fast-Fourier transformation to convert raw EEG into a time-compressed and color-coded display for frequencies between 0 and 30 Hz, with blue representing low power, and green, yellow and red representing successively higher power. The BIS bilateral system was designed to allow larger brain coverage than conventional BIS because it may record and display four channels of EEG. Moreover,

its use offers other advantages in comparison with the conventional BIS such as the asymmetry (ASYM) display which is a processed variable indicating the percentage of EEG power present in the left or right hemispheres with respect to total EEG power. Asymmetry data may be plotted as part of the CDSA display. Interestingly, recent studies have stressed that BIS monitoring may be useful in others clinical situations outside anesthesia such as detection of brain death, treatment of refractory status epilepticus or prediction of prognosis in comatose subjects,^{5–7} but these studies need to be substantiated before widespread use for these indications.

We are aware that CEEG is the method of choice for the evaluation of electric brain activity in comatose patients. Full video-EEG has been adopted in most large medical centers because it has significant advantages: better scalp coverage for partial seizures, video for assessment of movement artifacts, internet access for the physician to be able to interpret over 24 h, automated seizure detection with advanced paradigms, and finally, the ability to identify the many EEG but no-epileptic phenomena that may be confused with seizures on limited EEG recordings. We would like to highlight that under certain circumstances bilateral BIS-Vista™ monitor may be helpful in the assessment of sedated patients with possible NCSz or NCSE. It does not obviate the need for EEG, since diagnostic confirmation of

seizure activity and NCSE should be always sought. Seizures may be unrecognized when distant from the frontal or temporal lobe and when there is limited scalp EEG coverage. In this case report, BIS values and, in particular, CDSA were useful tools for monitoring NCSE outside of normal working hours. Recently, Musialowicz et al.⁷ established the utility of BIS in the assessment of the depth of propofol anesthesia in the treatment of refractory status epilepticus. Similarly, Dahaba et al.⁸ described a young patient in which BIS was successfully employed for monitoring a case of acute encephalitis and refractory repetitive partial seizures. During recent years, many investigations have concluded that NCSz and episodes of NCSE occur frequently in comatose critically ill patients and may have a negative impact on prognosis. Therefore, early detection of NCSE and continuous monitoring after the onset of antiepileptic treatment are strongly recommended.⁹ Although CEEG remains the gold standard for cerebral monitoring in the ICU, it is still not widely available. In the meantime, the use of alternative devices such as bilateral BIS may be helpful in monitoring selected cases of comatose NCSE. A drawback in our study is that this is a single case report and, larger studies are needed to assess the sensitivity and specificity of the new bilateral BIS monitoring in the management of NCSE.

Conflict of interest

None of the authors has any conflict of interest to disclose.

Acknowledgement

Dr. Fernández-Torre would like to thank to Professor Peter W. Kaplan (Baltimore, USA) by his kind revision of the manuscript.

References

1. Young GB, Jordan KG, Doig GS. An assessment of nonconvulsive seizures in the intensive care unit using continuous EEG monitoring: an investigation of variables associated with mortality. *Neurology* 1996;**47**:83–9.
2. Chong DJ, Hirsch LJ. Which EEG patterns warrant treatment in the critically ill? Reviewing the evidence for treatment of periodic epileptiform discharges and related patterns. *J Clin Neurophysiol* 2005;**22**:79–91.
3. Kilbride RD, Costello DJ, Chiappa KH. How seizure detection by continuous electroencephalographic monitoring affects the prescribing of antiepileptic medications. *Arch Neurol* 2009;**66**:723–8.
4. Friedman D, Claassen J, Hirsch LJ. Continuous electroencephalogram monitoring in the intensive care unit. *Anesth Analg* 2009;**109**:506–23.
5. Fábregas N, Gambús PL, Valero R, Carrero EJ, Salvador L, Zavala E, et al. Can Bispectral index monitoring predict recovery of consciousness in patients with severe brain injury? *Anesthesiology* 2004;**101**:43–51.
6. Escudero D, Otero J, Muñoz G, GonzaloJA, Calleja C, González A, et al. The Bispectral index scale: its use in the detection of brain death. *Transplant Proc* 2005;**37**:3661–3.
7. Musialowicz T, Mervaala E, Kälviäinen R, Uusaro A, Ruokonen E, Parviainen I. Can BIS monitoring be used to assess the depth of propofol anesthesia in the treatment of refractory status epilepticus? *Epilepsia* 2010;**51**:1580–6.
8. Dahaba AA, Liu DW, Metzler H. Bispectral Index (BIS) monitoring of acute encephalitis with refractory, repetitive partial seizures (AERRPS). *Minerva Anesthesiol* 2010;**76**:298–301.
9. Fernández-Torre JL. Estado epiléptico no convulsivo en adultos en coma. *Rev Neurol* 2010;**50**:300–8.