

# Silent Cardiac Ischemia after an Ischemic Stroke of the Right Hemisphere

Kristel M. Kasius<sup>a</sup> Evert J.P. Lamfers<sup>b</sup> Dick J. Venderink<sup>c</sup> Wim I.M. Verhagen<sup>a</sup>

Departments of <sup>a</sup>Neurology, <sup>b</sup>Cardiology and <sup>c</sup>Radiology, Canisius Wilhelmina Hospital, Nijmegen, The Netherlands

## Established Facts

- Cardiac complications frequently occur after a stroke.
- The cingulate gyrus is, according to positron emission tomography studies, less activated in silent myocardial ischemia.

## Novel Insights

- An ischemic lesion of the putamen and subsequent disruption of the limbic circuit that projects to the cingulate gyrus may contribute to either spatial neglect or to not feeling the angina.
- Silent ischemia may not only be explained by the mechanism of disruption of the autonomic neural system, but also by cerebral changes.

## Key Words

Angina pectoris • Referred pain • Myocardial ischemia • Stroke • Brain right hemisphere

angina because of putamen ischemia and secondary disturbed projection to the cingulate gyrus and no longer felt or experienced this referred pain.

Copyright © 2011 S. Karger AG, Basel

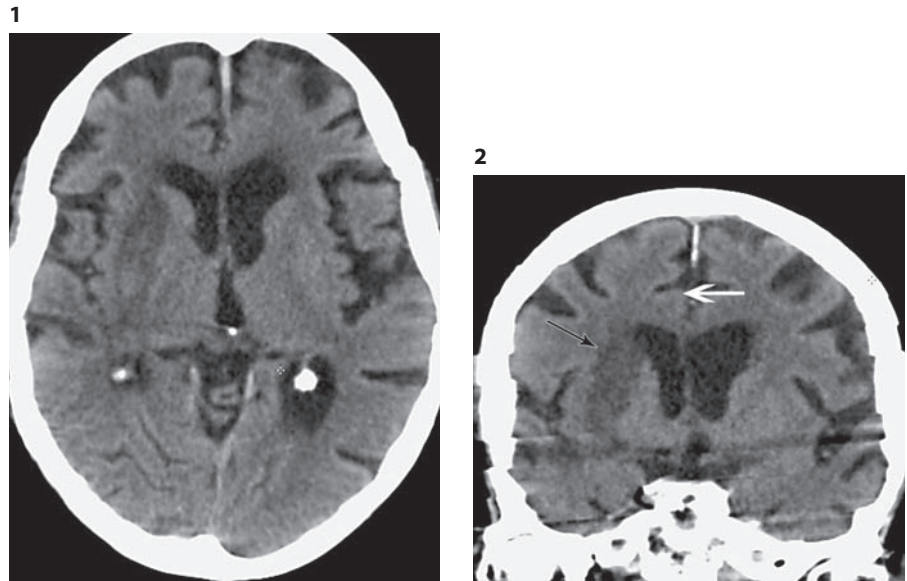
## Abstract

A patient is described who previously had daily complaints of angina pectoris, yet no longer experienced chest pain after an ischemic stroke of the right hemisphere, despite several recorded episodes of electrocardiographic changes and an elevation of cardiac enzymes compatible with myocardial ischemia. The cingulate gyrus is involved in spatial attention and neglect, and is, according to positron emission tomography studies, less activated in silent myocardial ischemia. We suggest that this patient was not aware of the

## Introduction

Angina pectoris and ischemic stroke share underlying pathological processes and risk factors. The occurrence of ischemic stroke is associated with the presence and severity of ischemic cardiac disease, such as angina pectoris [1].

In angina pectoris, several cortical areas are activated by projection of the spinothalamic tract, including the



**Fig. 1.** Axial reconstruction (3 mm) of a CT image revealing isolated putaminal infarction, sharply demarcated on the right side with preservation of the other basal nuclei.

**Fig. 2.** Coronal reconstruction (3 mm) of CT illustrating the extent of the putaminal infarction (black arrow) with the intact cingulate gyrus (white arrow) in the right hemisphere.

anterior cingulate gyrus [2]. It may therefore be possible that cardiac complaints such as angina change after brain lesions. We present a patient with noteworthy changes after a stroke.

### Case Description

In 2008, a 90-year-old female exsmoker (40 pack-years), who lived on her own, was admitted to our hospital with an ischemic stroke.

Her medical history revealed hypertension and chronic obstructive pulmonary disease; in the year 2000 she had had an inferolateral myocardial infarction, and in 2005 an acute coronary syndrome with chest pain, electrocardiogram (ECG) changes corresponding with 3-vessel coronary artery disease, increase of troponin T to 5.21  $\mu\text{g/l}$  without elevated creatine kinase and symptoms of heart failure. Since 2006 she had experienced frequent angina pain (New York Heart Association class III [3]) sometimes up to 6 times a day, with tight chest discomfort, radiating to the left arm. At times she experienced some radiation to the right side. All these complaints responded well to isosorbide dinitrate 5 mg sublingual of up to 6 doses daily.

In September 2008, early in the morning, she was found, lying on the floor of her home covered in vomit and feces, with a left-sided hemiparesis. She had not taken her medication that morning.

Upon admission, she had no complaints of chest pain. There were no hemodynamic instabilities or fever. She was notably dyspneic. Upon neurological examination, she had tonic head and eye deviation to the right, a left central facial nerve palsy and a hemi-inattention and hemisensory loss on the left side. There was a left-sided hypotonic paralysis of the arm and hypertonic paresis (Medical Research Council [4] scale grade 1–2) of the left leg. The tendon reflexes were brisk on the left side and plantar responses were extensor.

A brain CT scan revealed hypodensity of the putamen and sulcus effacement in the territory of the right medial cerebral artery (fig. 1, 2). An ECG showed sinus rhythm, normal axis and QRS duration, and slight ST-segment depression. Blood tests showed normal glucose levels, elevated urea (12.2 mmol/l, normal range: 3.0–7.0 mmol/l) and creatinine (104  $\mu\text{mol/l}$ , normal range: 60–110  $\mu\text{mol/l}$ ), C-reactive protein (33 mg/l, normal range: 0–4 mg/l) and leukocytes ( $23 \times 10^9/\text{l}$ , normal range:  $4.0\text{--}11.0 \times 10^9/\text{l}$ ). There was clinical and radiological evidence of right upper-lobe pneumonia. Intravenous amoxicillin/potassium clavulanate 1,000/200 mg 2 $\times$  daily was started. The symptoms of heart failure were treated intravenously with 20 mg furosemide.

We concluded that the neurological symptoms could be attributed to a severe ischemic stroke in the right medial cerebral artery territory. The patient was admitted to the stroke unit with continuous observation of heart rhythm and frequency, respiratory frequency and oxygen saturation. Acetylsalicylic acid was continued and dipyridamole was added.

Because of changes in the ST segment on the monitor, a new ECG was performed. The patient did not have complaints about chest pain or pain radiating to the left arm. She was somewhat nauseous and a bit more dyspneic. The ECG showed sinus rhythm, normal axis and QRS duration with evident ST depression in V<sub>4</sub>–V<sub>6</sub>, II, III and aVF corresponding with ischemia, probably 3-vessel disease. Compared to the ECG at admission, the ST abnormalities were more severe.

The next morning, ST depression was evidently less distinct. Creatine kinase was increased to 3,130 U/l and there was also some elevation of troponin T (0.13  $\mu\text{g/l}$ ). In the evening, there was again an increase of the ST depression without (corresponding) complaints of chest pain. An ongoing lateral myocardial infarction was diagnosed by the consulting cardiologist.

After 10 days, the patient regained some perception on her left side. However, the chest pain that she had experienced almost daily before the ischemic stroke did not return.

Because of her poor clinical condition, she was transferred to a nursing home about 3 weeks after onset of the ischemic stroke. Supplementary diagnostics were not performed, as, due to her physical condition, the results of these investigations would not have had any further consequences. The patient died in the nursing home 1 week later, presumably of pneumonia and heart failure. Permission for autopsy was not obtained.

## Discussion

Cardiac complications frequently occur after a stroke. In general, about 2% of patients who are admitted with an ischemic stroke are reported to suffer myocardial infarctions during hospitalization [5].

A noteworthy feature of this patient was the lack of pain radiating to the left arm while she suffered an acute myocardial infarction with specific ECG changes and increased troponin T and creatine kinase levels. The only signs she experienced were dyspnea and nausea, and these could be attributed to complicated heart failure. Before the ischemic stroke, she had daily experienced radiating pain accompanied by dyspnea or nausea. We speculate that she did not feel or was not aware of the pain radiating to her left arm because of the hemisensory loss or a hemi-inattention to the left side, respectively.

In this case, one can assume that the patient went through a silent myocardial ischemic episode; however, she did experience uncomfortable sensations such as dyspnea and nausea. By definition, any symptoms of cardiac ischemia must be absent in order to make the diagnosis of silent ischemia [6]. However, elderly people without a history of cerebral infarction often present with atypical symptoms of myocardial infarction, i.e. without anginal pain, but, for example, nausea or syncope only [7]. The most likely explanation of this phenomenon is an altered pain threshold; disruption of the autonomic neural system, by repetition of ischemic episodes, has also been mentioned [7]. In the literature, however, the combination of a silent myocardial infarction and an ischemic stroke is not mentioned in relation to silent myocardial ischemia. Referred pain in angina is explained by the convergence-projection theory, which states that visceral and somatic afferents converge upon the same spinothalamic tract cells in the anterolateral quadrant of the spinal cord. Angina is referred to the corresponding dermatomes that supply afferent nerves to the same segments as the heart [2].

With positron emission tomography scanning, regional cerebral blood flow changes have been investigated in patients with painful and silent myocardial ischemia, by

means of dobutamine-induced angina accompanied by ischemic ECG changes [8]. During angina, increased regional cerebral blood flow is seen in the hypothalamus, thalamus and hippocampal gyrus, and bilaterally in the lateral basal frontal, mesial orbitofrontal and ventral cingulate cortices. Silent ischemia has been associated with the absence of activation of the basal frontal, anterior and ventral cingulate cortices and the left temporal pole, when compared to angina [8]. After stopping the infusion, and with the disappearance of angina, only thalamic activation could be seen. These findings may suggest that the involvement of some of the cortical structures is necessary to experience cardiac or referred pain.

Hemispatial neglect is a common finding, after, for example, cerebral infarction, especially of the right hemisphere. Hemispatial neglect is characterized by reduced attention to stimuli, where patients fail to be aware of objects or parts of their own body on their contralesional side [9]. Normally, the right cerebral hemisphere is involved with attention to both the right and left hemisphere equally, while the left cerebral hemisphere attends to the right hemisphere [10]; therefore, lesions of the right hemisphere can cause contralesional neglect. The posterior parietal cortex, frontal lobe, cingulate gyrus and thalamus are involved in the coordination of spatial attention, in which the cingulate gyrus is the limbic component of the network [10]. The putamen is involved in both the acute and chronic phases of spatial neglect caused by stroke [11]. It is supposed that the neglect is caused by secondary reduced cortical metabolism due to ischemia or by disrupted connections from the subcortical structures to the cortices involved in spatial neglect [12]. The cingulate gyrus is involved in identifying the motivational relevance, and is, according to positron emission tomography studies, less activated in silent myocardial ischemia. We suggest that in this patient an ischemic lesion of the putamen and subsequent disruption of the limbic circuit that projects to the cingulate gyrus contributed to either spatial neglect or to not feeling the angina. Our patient demonstrates that silent ischemia may not only be explained by the mechanism of disruption of the autonomic neural system, but also by cerebral changes. As far as we know, this is the first description of a patient who, due to an ischemic stroke, no longer felt or experienced referred cardiac pain.

## Conflict of Interest

The authors have none to declare.

## References

- 1 Tanne D, Shotan A, Goldbourt, et al: Severity of angina pectoris and risk of ischemic stroke. *Stroke* 2002;33:245–250.
- 2 Foreman RD: Mechanisms of cardiac pain. *Annu Rev Physiol* 1999;61:143–167.
- 3 The Criteria Committee of the New York Heart Association: Nomenclature and Criteria for the Diagnosis of Diseases of the Heart and Great Vessels, ed 9. Boston, Little, Brown, 1994.
- 4 Medical Research Council: Aids to the Examination of the Peripheral Nervous System. Memorandum No. 45. London, Her Majesty's Stationery Office, 1981.
- 5 Liao J, O'Donnell MJ, Silver FL, et al, Investigators of the Registry of the Canadian Stroke Network: In-hospital myocardial infarction following acute ischemic stroke: an observational study. *Eur J Neurol* 2009;16:1035–1040.
- 6 Gutterman DD: Silent myocardial ischemia. *Circ J* 2009;73:785–797.
- 7 Mehta RH, Rathore SS, Radford MJ, et al: Acute myocardial infarction in the elderly: differences by age. *J Am Coll Cardiol* 2001;38:736–741.
- 8 Rosen SD, Paulesu E, Nihoyannopoulos P, et al: Silent ischemia as a central problem: regional brain activation compared in silent and painful myocardial ischemia. *Ann Intern Med* 1996;124:939–949.
- 9 Parton A, Malhotra P, Husain M: Hemispatial neglect. *J Neurol Neurosurg Psychiatry* 2004;75:13–21.
- 10 Mesulam MM: Spatial attention and neglect: parietal, frontal and cingulate contributions to the mental representation and attentional targeting of salient extrapersonal events. *Philos Trans R Soc Lond B Biol Sci* 1999;354:1325–1346.
- 11 Karnath HO, Rennig J, Johannsen L, et al: The anatomy underlying acute versus chronic spatial neglect: a longitudinal study. *Brain* 2011;134:903–912.
- 12 Hillis AE, Wityk RJ, Barker PB, et al: Subcortical aphasia and neglect in acute stroke: the role of cortical hypoperfusion. *Brain* 2002;125:1094–1104.