

Dysmorphic features, cognitive disability, chronic inflammation, and predisposition to vascular disease in two sisters: a new autosomal recessive disorder?

Milen Velinov^a, Natalia Dolzhanskaya^a, Prema Ramaswamy^b, Laura Barinstein^b, R. Morgan Stuart^c, Philip Kahn^d, Neil Feldstein^c, and Ricardo E. Madrid^a

A 20-year-old woman presented with mental retardation and a history of stroke related to moyamoya disease at the age of 8 years. She had cognitive impairment which became more pronounced after the stroke. This patient's parents were first cousins and six close family relatives had strokes in their 60s or 70s. The patient's 16-year-old sister had learning disability, chronic muscle pain, and an ECG suggestive of previous hypoxemic heart injury. The two sisters had similar dysmorphic facial appearance including a prominent philtrum, bulbous nose, and severe acne. They both had increased subcutaneous tissue in their faces, whereas their bodies were slim. Both sisters were found to have elevated levels of rheumatoid factor, C-reactive protein, and erythrocyte sedimentation rate on repeat measurements. Partial autoimmunity screening in one of the patients was negative. Chromosome analysis and array comparative genomic hybridization analyses were also normal. Nerve conduction findings in the younger sister were consistent with distal, predominantly motor,

demyelinating neuropathy localized to the lower extremities. We propose that these two sisters suffer from a new autosomal recessive syndrome. Carrier status for this condition may predispose to later onset stroke. *Clin Dysmorphol* 21:8–10 © 2011 Wolters Kluwer Health | Lippincott Williams & Wilkins.

Clinical Dysmorphology 2012, 21:8–10

Keywords: autosomal recessive, inflammation, learning disabilities, moyamoya stroke, muscle weakness, new syndrome, predisposition to stroke

^aNew York State Institute for Basic Research in Developmental Disabilities, Staten Island, ^bMaimonides Medical Center, Brooklyn, ^cColumbia Presbyterian Hospital Center and ^dNew York University, New York, New York, USA

Correspondence to Dr Milen Velinov, MD, PhD, New York State Institute for Basic Research in Developmental Disabilities, 1050 Forest Hill Road, Staten Island, NY 10314, USA
Tel: +1 718 494 5219; fax: +1 718 494 1072;
e-mail: milen.velinov@opwdd.ny.gov

Received 24 February 2011 Accepted 24 August 2011

Introduction

Moyamoya disease is an uncommon cerebrovascular disorder, characterized by progressive stenosis or occlusion of the terminal internal carotid arteries and consequent formation of collateral vascular pathways (Takahashi and Miyamoto, 2010).

Two sisters with consanguineous parents presented with laboratory abnormalities indicative of chronic inflammation in addition to cognitive impairment and dysmorphic features. The older sister had a moyamoya type of stroke at the age of 8 years. Stroke due to moyamoya disease has previously been reported in families or observed as part of various genetic syndromes (Kuroda and Houdin, 2008; Herve *et al.*, 2010; Munot *et al.*, 2011). Our family presents with a unique and previously unreported combination of manifestations.

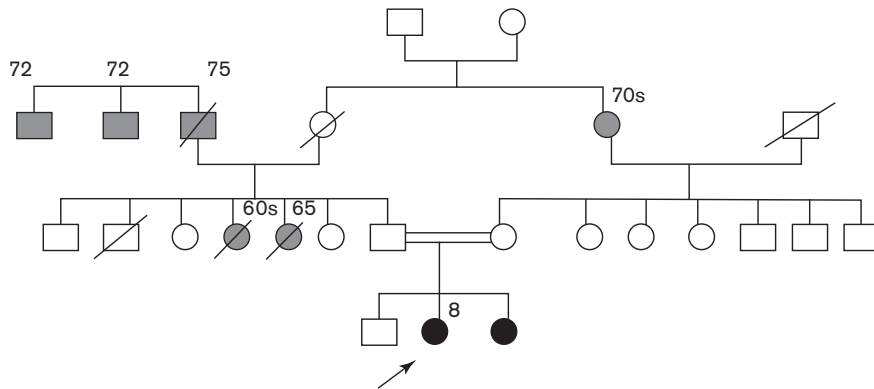
Clinical cases

Patient 1

A 20-year-old woman presented with severe developmental delay. Her parents were first cousins. Two paternal aunts, the paternal grandfather, and two of his brothers had strokes in their 60s or 70s. The maternal grandmother also had a stroke in her 70s (see family

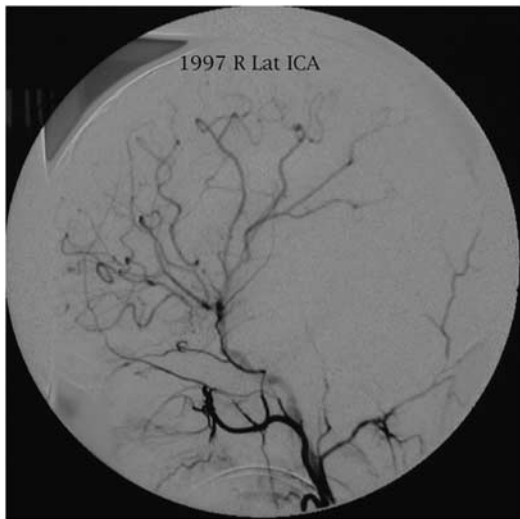pedigree, Fig. 1). The pregnancy was uncomplicated. The baby was born at full term. Her birth weight was 3350 g. Her early cognitive development was reportedly normal, but she was found to have learning disability at school age and received extra help in school. At the age of 8 years she had an episode of acute hemiparesis and loss of speech. Her cerebral angiogram demonstrated diffuse constriction of the vasculature consistent with moyamoya disease (Fig. 2). She underwent two surgical procedures on her brain at that time. After the surgical interventions she had partial motor recovery, but her cognitive skills did not progress after this episode. A Vineland II adaptive test at the age of 20 showed standard scores for communication of 64 ± 6 and daily living skills of 38 ± 8 that were roughly equivalent to 3–6 years of age. This patient had very delayed gross and fine motor skills. She was unable to take a shower or dress herself without assistance. She had limited ambulation with a slow, wide-based gait. On physical examination the patient's height was on the fifth percentile, weight on the 17th percentile, and head circumference on the 40th percentile for her age. She had dysmorphic facial features with a bulbous nose, prominent philtrum, and a round face with increased subcutaneous fat tissue (Fig. 3a). She had abundant acne and hirsutism. Her body was slim and generalized muscle

Fig. 1



Family pedigree. The symbols of the discussed patients are shown in black. The symbols of the relatives that experienced strokes are shown in gray. The age in years they experienced the strokes are indicated on top of individual symbols.

Fig. 2



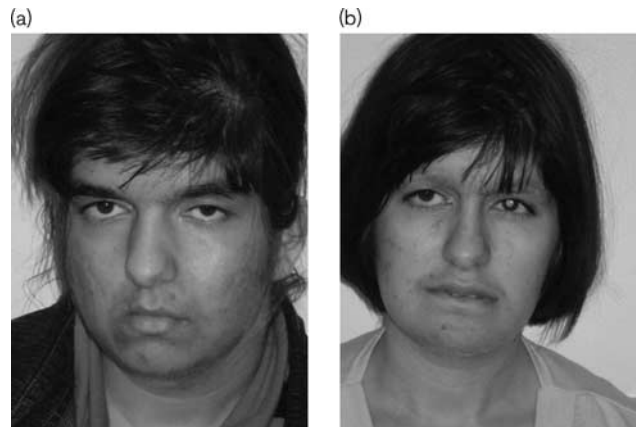
Digital subtraction angiography of the right internal carotid artery demonstrates characteristic moyamoya appearance of the cerebral vasculature.

weakness was noted. Her deep tendon reflexes were normal and symmetric.

Patient 2

The proband's 16-year-old sister presented with severe learning disability and muscle pain in her lower extremities. She was born postmature, after uncomplicated pregnancy. Her birth weight was 3175 g. Her early development was apparently normal but she was noted to have learning disability in school. Testing by the board of education at the age of 14 concluded that her reading and math skills correspondent to I–II grade (6–7 years of age). She also had hyperactivity. At the age of 16 the

Fig. 3



The 20-year-old proband (a) and her 16-year-old sister (b).

Vineland II adaptive test showed standard average scores for communication: 87 ± 7 , and for daily living skills: 93 ± 9 , that were scattered and equivalent to 11–22 years of age. Her gross and fine motor skills were most affected and were equivalent to 2.5–6 years of age. She complained of long-standing but intermittent chest pain. Her ECG showed evidence of mild intraventricular conduction delay with a QRS duration of 100 ms with T wave changes suggestive of myocardial damage. Her ECG showed that her ventricular systolic function was at the lower end of normal. This patient also complained of chronic muscle weakness and pain. On physical examination her height, weight, and head circumference were at the 10th, third, and 10th percentiles, respectively. She had dysmorphic features similar to her sister (Fig. 3b). She also had acne and hirsutism and a slim body habitus. She had bilateral pes planus and prominent ankle fat pads

reminiscent of xanthomas. On neurological examination her muscle tone, bulk, and strength were normal but deep tendon reflexes were hypoactive throughout. Plantar flexor responses were elicited bilaterally. Nerve conduction studies of the upper extremities were normal. In the lower extremities, uniform, bilateral decreased motor conduction velocities of both the peroneal (right: 29 m/s; left: 33 m/s; age-matched controls: > 43 m/s) and tibial (right: 28 m/s; left: 29 m/s; age-matched controls: > 41 m/s) nerves were found. Prolonged distal sensory latency of the right sural (4.5 ms; age-matched control: < 3 ms) and decreased amplitude of the right superficial peroneal nerves was also documented.

Investigations

Patient 1 had an erythrocyte sedimentation rate (ESR) of 80 (normal range 0–20), rheumatoid factor of 91 (normal range < 14), and C-reactive protein of 4 (normal range < 0.8). Patient 2 had an ESR of 118 (0–20), rheumatoid factor of 2992 (< 14), and C-reactive protein of 5.2 (< 0.8). These studies were reported repeatedly abnormal on three different occasions.

Patient 2 had elevated IgM level of 349 mg/dl (normal range 23–259 mg/dl). She also had the following laboratory tests that were all reported normal/negative: Lyme disease serology, lupus anticoagulant complex, celiac disease markers, thyroid function tests, HLA-B27 antigen, antiproteinase, antiscleroderma, angiotensin converting enzyme, antimyeloperoxidase, and complement 3.

Patient 2 also had normal brain and spine MRI. A muscle biopsy done to address her muscle weakness was reported with normal histology. Sural nerve biopsy was unsuccessful.

Both patients had chromosomal analysis and array comparative genomic hybridization analysis using the Agilent Inc., 44K array (Santa Clara, California, USA). These tests were normal.

Discussion

Single gene defects leading to vascular disorders are rare. Heterozygosity for mutations in the smooth muscle α -actin gene, ACTA2 was previously associated with familial predisposition to coronary artery disease, stroke, and moyamoya disease (Guo *et al.*, 2009). Heterozygous mutations in the genes MEF2 (Wang *et al.*, 2003) and LRP6 (Mani *et al.*, 2007) were identified in patients with two distinct familial disorders that include early coronary artery disease. The above-mentioned phenotypes did not include dysmorphic features, learning disabilities, nor immune abnormalities.

Homozygous mutations in the gene SAMHD1 were recently identified in individuals of the Old Order Amish, who presented with early cerebrovascular disease and

elevated ESR and IgG levels (Xin *et al.*, 2011). However the affected individuals also had intrauterine growth retardation, early hypotonia, acrocyanosis, and glaucoma that were not observed in our family. Moreover, the SAMHD1-associated phenotypes did not include dysmorphic features similar to our patients. Single cases of individuals with moyamoya type of strokes and immune abnormalities including elevated rheumatoid factor were previously reported (Yanagawa *et al.*, 2007). Moyamoya strokes were also reported in association with lupus and other autoimmune disorders (Sasaki *et al.*, 2006; Jeong *et al.*, 2008). Finally, moyamoya strokes were reported in association with Down syndrome and neurofibromatosis. These conditions were ruled out in our patients.

To our knowledge the phenotype observed in our patients has not been previously reported and we propose that our patients' manifestations are part of a new autosomal recessive condition. Furthermore, it may be speculated that the six family relatives, who suffered strokes in their 60s and 70s, may be carriers of the same gene mutation that predisposed them to later onset vascular accidents. In conclusion, the gene defect in the reported family may be an important stroke predisposing factor that deserves further investigation.

Acknowledgements

Conflicts of interest

There are no conflicts of interest.

References

- Guo DC, Papke CL, Tran-Fadulu V, Regalado E, Avidan N, Jay Johnson R, *et al.* (2009). Mutation in smooth muscle alpha-actin (ACTA2) cause coronary artery disease, stroke, and moyamoya disease, along with thoracic aortic disease. *Am J Hum Genet* **84**:617–627.
- Herve D, Touraine P, Verloes A, Miskinyte S, Krivosic V, Logeart D, *et al.* (2010). A hereditary moyamoya syndrome with multisystemic manifestations. *Neurology* **75**:259–264.
- Jeong HC, Kim YJ, Yoon W, Joo SP, Lee SS, Park YW (2008). Moyamoya syndrome associated with systemic lupus erythematosus. *Lupus* **17**: 679–682.
- Kuroda S, Houdin K (2008). Moyamoya disease: current concepts and future perspectives. *Lancet Neurol* **7**:1056–1066.
- Mani A, Radhakrishnan J, Wang H, Mani A, Mani MA, Nelson-Williams C, *et al.* (2007). LRP6 mutation in a family with early coronary disease and metabolic risk factors. *Science* **315**:1278–1281.
- Munot P, Crow Y, Ganesan V (2011). Pediatric stroke: genetic insights into disease mechanisms and treatment targets. *Lancet Neurol* **10**:264–274.
- Sasaki T, Nogawa S, Amano T (2006). Co-morbidity of moyamoya disease with graves' disease. Report of three cases and a review of the literature. *Intern Med* **45**:645–653.
- Takahashi JC, Miyamoto S (2010). Moyamoya disease: recent progress and outlook. *Neurol Med Chir (Tokyo)* **50**:824–832.
- Wang L, Fan C, Topol SE, Topol EJ, Wang Q (2003). Mutation of MEF2A in an inherited disorder with features of coronary artery disease. *Science* **302**:1578–1581.
- Xin B, Jones S, Puffenberger EG, Hinze C, Bright A, Tan H, *et al.* (2011). Homozygous mutation in SAMHD1 gene causes cerebral vasculopathy and early onset stroke. *Proc Natl Acad Sci USA* **108**:5372–5377.
- Yanagawa Y, Sugiura T, Suzuki K, Okada Y (2007). Moyamoya disease associated with positive findings for rheumatoid factor and myeloperoxidase-anti-neutrophil cytoplasmic antibody. *West Indian Med J* **56**:282–284.