

# Endovascular treatment of a pial arteriovenous fistula of a posteroinferior cerebellar artery with a double origin

Leopoldo Guimaraens,<sup>1</sup> Alfredo Casasco,<sup>2</sup> Teresa Sola,<sup>1</sup> Hugo Cuellar,<sup>3</sup> Salvador Miralbes,<sup>4</sup> Francisco Jose Cambra<sup>5</sup>

<sup>1</sup>Department of Therapeutic Neuroangiography, Hospital General de Cataluña, Sant Cugat del Valles, Spain

<sup>2</sup>Department of Terapia Endovascular y Percutanea, Clínica Nuestra Señora del Rosario, Madrid, Spain

<sup>3</sup>Department of Neurosurgery, Louisiana State University Health Sciences Center, Shreveport, Louisiana, USA

<sup>4</sup>Department of Interventional Neuroradiology, Hospital Son Dureta, Palma de Mallorca, Spain

<sup>5</sup>Department of Pediatric Intensive Care Unit, Hospital Sant Joan de Deu, Barcelona, Spain

## Correspondence to

Dr L Guimaraens, Department of Therapeutic Neuroangiography, Hospital General de Cataluña, C/Pedro i Pons, 1, 08195 Sant Cugat del Valles, Spain; guimaraens@mimsl.es

Received 27 August 2010

Revised 21 October 2010

Accepted 26 October 2010

Published Online First

6 January 2011

## ABSTRACT

Pial arteriovenous fistulas (pAVF) of the posterior fossa are rare and may present with symptoms secondary to mass effect, venous hypertension or hemorrhage, among others. A case is presented of a previously healthy 2-year-old boy with neurological deficit arising from pAVF of the posteroinferior cerebellar artery. The pAVF was successfully treated with endovascular occlusion.

## INTRODUCTION

Pial arteriovenous fistulas (pAVF) are rare lesions characterized by the presence of a direct communication of one or several arterial feeders into a dilated vein. Presenting symptoms include mass effect, especially if a venous pouch is associated, hemorrhage, seizures, cardiac failure and/or venous hypertension.<sup>1,2</sup> Posterior fossa pAVF are even rarer entities with only a few cases reported.<sup>3,4</sup> They may be associated with hereditary hemorrhagic telangiectasias or trauma. The natural history of these arteriovenous shunts is not well known.<sup>5-7</sup>

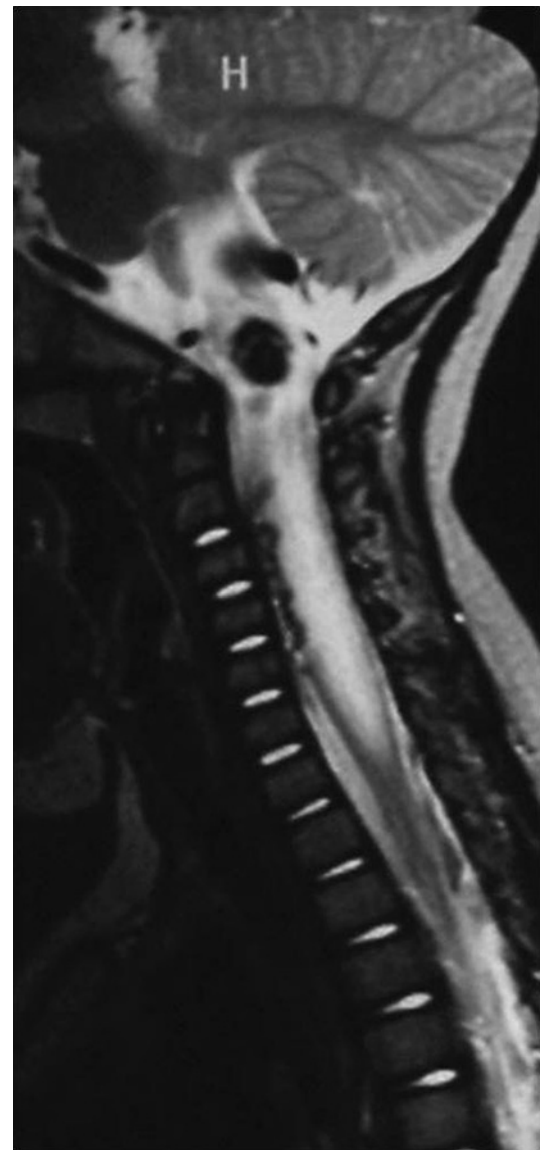
We present the case of a 2-year-old boy with a single channel pAVF of the posterior fossa treated by an endovascular approach.

## Case report

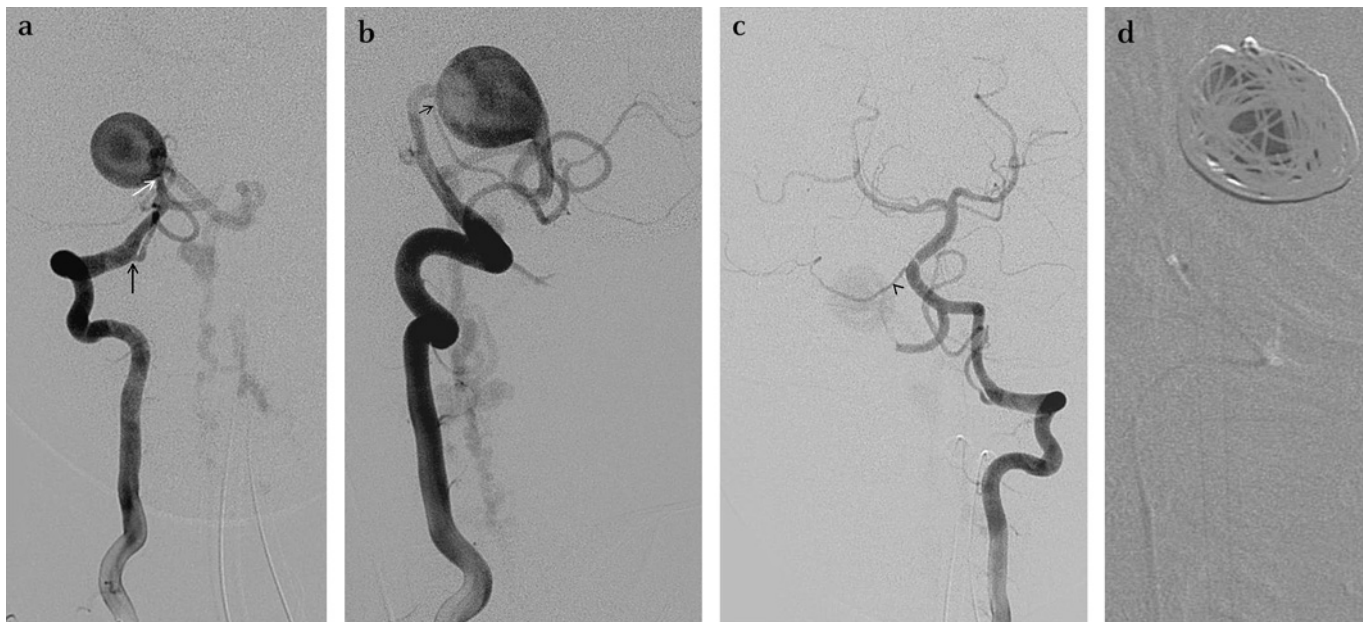
A previously healthy 2-year-old male with no family or personal history of any disease had a gradual onset of frequent falls and reduced appetite. One month after symptom onset, the patient presented to an emergency room with additional frequent vomiting, cervical pain and paresis of the left upper extremity. An MRI of the brain revealed a giant vascular dilatation compressing the pontomedullary junction with dilated perispinal vessels and edema of the brainstem and spinal cord down to C7 (figure 1). Initial medical management took place in the pediatric intensive care unit with high dose steroids. Despite the intensive treatment, the patient developed new onset plegia in the left upper extremity and paresis of the left lower extremity. Given the localization and age of the patient, a giant AVF was suspected, and definitive treatment by an endovascular approach was planned. The treatment was performed 5 days after the initial presentation.

Under general anesthesia, a 5 F introducer was placed in the right femoral artery and a diagnostic angiogram revealed a duplicated origin of the right posteroinferior cerebellar artery (PICA) at V3 and the upper segment at V4. The upper branch formed a single hole pial fistula draining into a giant venous

pouch and into the dilated perispinal veins and cervical epidural plexus. The normal appearing lower branch had a communication with the proximal portion of the dilated upper segment, providing a security margin for a safe embolization (figure 2). With the guiding catheter in the right vertebral artery, a microcatheter was placed in the venous pouch and embolization was performed



**Figure 1** Pretreatment sagittal MR T2 WI showing high signal intensity and enlargement of the brainstem and spinal cord associated with dilated vessels with flow voids.

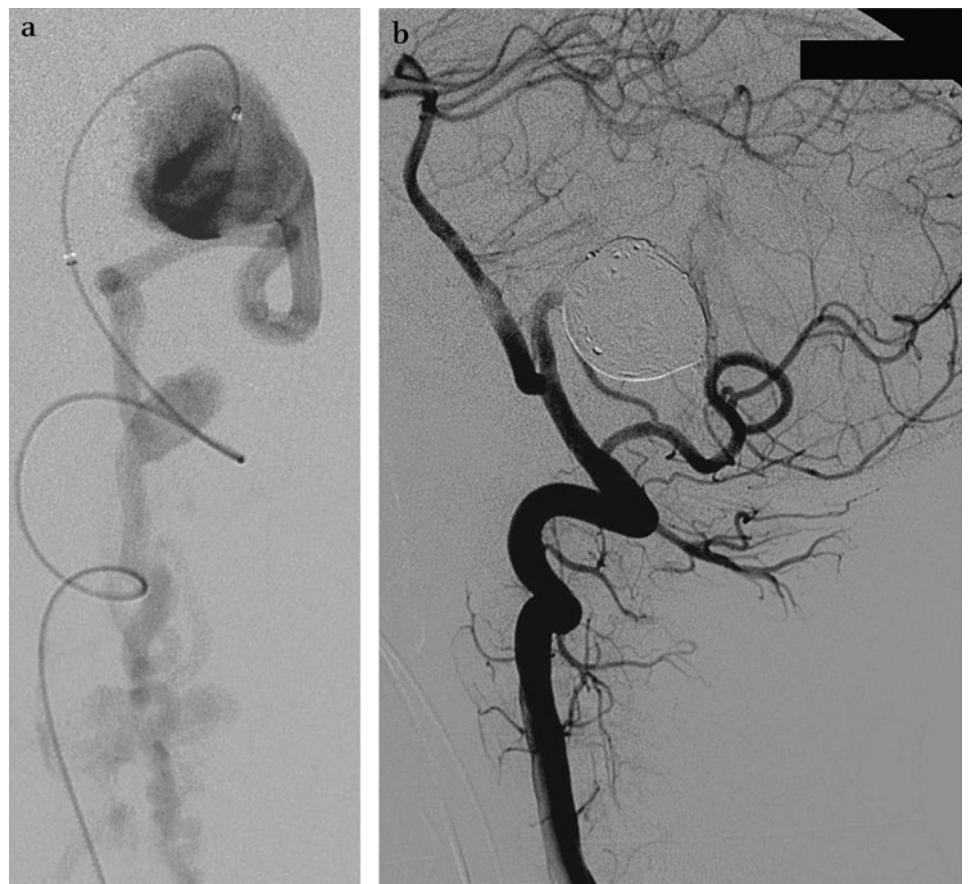


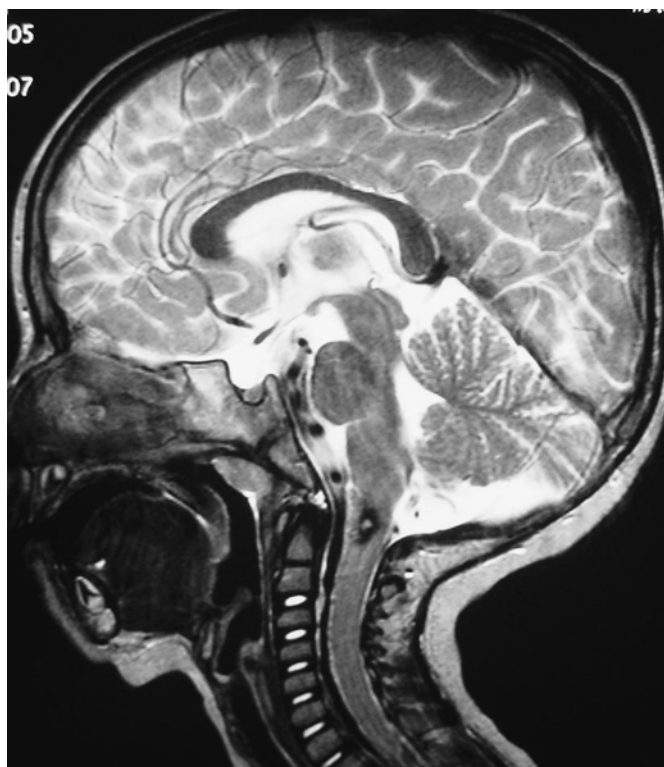
**Figure 2** (A) Digital subtraction angiography (DSA) in anteroposterior (AP) view of the right vertebral artery showing a single hole pial fistula (white arrow) of the posteroinferior cerebellar artery (PICA). Note also the lower segment originating at V3 (black arrow). (B) DSA in lateral view of the right vertebral artery showing the dilated upper origin of the PICA draining into a giant venous varix that drains downwards towards perispinal veins. Note the site where the two origins of the artery join proximal to the shunt (black arrow). (C) DSA in AP view of the left vertebral artery showing a normal right anterior inferior cerebellar artery (black arrowhead). (D) Roadmapping during embolization with N-butyl cyanoacrylate showing the mesh of coils inside the venous pouch and no migration of glue during injection.

using coils to reduce flow and avoid migration of glue towards the venous side. After flow reduction, N-butyl cyanoacrylate (NBCA) was safely injected to achieve complete occlusion of the fistula (figure 3). On the final angiographic control we observed

that normal cerebellar circulation was preserved and venous drainage had returned to normal. The patient was transferred to the pediatric intensive care unit where he recovered for a week with a regimen of steroids and low molecular weight heparin.

**Figure 3** (A) Digital subtraction angiography (DSA). Lateral view of the microcatheter inside the venous pouch showing downward drainage towards perispinal veins and the cervical epidural plexus. (B) Post-embolization DSA of the right vertebral artery showing complete occlusion of the shunt with patency of both origins of the posteroinferior cerebellar artery.





**Figure 4** MR control 3 months after treatment. Sagittal T2 WI showing the disappearance of the dilated vessels with normal size and signal intensity of the brainstem and spinal cord.

Clinical and MR control at 3 months showed the complete thrombosis and reduction of the venous pouch and disappearance of the dilated perispinal veins. The brainstem and spinal cord signal intensity also normalized (figure 4). At the time of the last follow-up, the patient was completely asymptomatic without any residual neurological deficit. The patient will be followed-up clinically and if no symptoms reappear, MR imaging will be obtained at 5 years to assess the stability of the treatment.

## DISCUSSION

Our patient presented with signs and symptoms of a posterior fossa mass effect from a dilated venous pouch at the ponto-medullary junction and additional myelopathy at the brainstem and spinal cord due to venous hypertension. Posterior fossa AVF are very rare lesions in children and adults with a slight male preponderance.<sup>7</sup> In children, pAVF are usually diagnosed by 3.5 years of age. Neurological deficits are usually secondary to mass effect, steal phenomenon or venous hypertension.<sup>1 8–12</sup> Patients with posterior fossa pAVF may present with intracranial hemorrhage.<sup>13</sup> In our patient, a combination of mass effect and venous hypertension secondary to reflux to perispinal veins resulted in a clinical presentation. Similar venous hypertension results in myelopathy in adults with type V dural fistulas. An association of pAVF with hereditary hemorrhagic telangiectasias (in up to 27% of patients) has been noted in the literature.<sup>4 5 14</sup>

Management of posterior fossa AVF, either by surgical or endovascular therapy, is mandatory in all symptomatic cases. Conservative therapy leads to a high mortality and hemorrhage rates.<sup>13</sup> The goals of therapy are to preserve normal neuro-cognitive maturation and provide protection from hemorrhage and progressive neurologic deficits.<sup>7</sup> Treatment options for this type of arteriovenous malformation have evolved towards

endovascular therapy. This is best accomplished by transarterial embolization when possible. NBCA alone or in combination with coils may be used for embolization; high density Onyx embolization is another option for high flow fistulas. We decided to use NBCA in our patient due to our vast experience using this material (over 25 years); in our experience NBCA has better occlusion rates and it can be managed quite easily. The aim of endovascular therapy is to occlude, either in one or multiple sessions, the shunting zone(s) with preservation of the distal vasculature.<sup>2–4 6 7 14</sup>

Myelopathy secondary to venous congestion is reversible if treated early, as was the case in our patient.<sup>12</sup> Potential complications of endovascular therapy include the increase in mass effect due to swelling of the thrombosed varix, hemorrhage or acute cardiac decompensation; these may be minimized using staged procedures.<sup>2 7 15</sup> Our patient tolerated complete occlusion in one session and had no signs of increased mass effect after embolization. Immediate improvement seen in our patient was probably due to a reduced mass effect to the brainstem; as the fistula was closed, the pulsatile effect of the venous varix disappeared. Without the pulsatile effect, the mass of coils and glue did not present any additional compression to the brainstem. We found a rare variant duplicated origin of the right PICA, with a normal caliber lower segment arising at the level of C1 and a dilated upper segment arising from intracranial vertebral artery (V4).<sup>16</sup> The duplicated branches united proximal to the shunting zone allowing us to safely embolize the pAVF. A final angiogram showed that both origins and distal branches of the PICA were patent, and normal venous drainage of the posterior fossa was restored.

## CONCLUSION

We have presented an interesting case of a giant posterior fossa pAVF that was treated successfully using endovascular embolization with NBCA. Successful occlusion of the lesion led to complete resolution of both symptoms and abnormal imaging findings.

**Competing interests** None.

**Patient consent** Obtained.

**Provenance and peer review** Not commissioned; externally peer reviewed.

## REFERENCES

1. Vinuela F, Drake CG, Fox AJ, *et al*. Giant intracranial varices secondary to high-flow arteriovenous fistulae. *J Neurosurg* 1987;**66**:198–203.
2. Vinuela F, Fox AJ, Kan S, *et al*. Balloon occlusion of a spontaneous fistula of the posterior inferior cerebellar artery. *J Neurosurg* 1983;**58**:287–90.
3. Boet R, Poon WS, Chan MS, *et al*. Childhood posterior fossa pial-dural arteriovenous fistula treated by endovascular occlusion. *Childs Nerv Syst* 2001;**17**:681–4.
4. Coubes P, Humbertclaude V, Rodesch G, *et al*. Total endovascular occlusion of a giant direct arteriovenous fistula in the posterior fossa in a case of Rendu-Osler-Weber disease. *Childs Nerv Syst* 1996;**12**:785–8.
5. Garcia-Monaco R, Taylor W, Rodesch G, *et al*. Pial arteriovenous fistula in children as presenting manifestation of Rendu-Osler-Weber disease. *Neuroradiology* 1995;**37**:60–4.
6. Liu JK, Decker D, Tenner MS, *et al*. Traumatic arteriovenous fistula of the posterior inferior cerebellar artery treated with endovascular coil embolization: case report. *Surg Neurol* 2004;**61**:255–60.
7. Yoshida Y, Weon YC, Sachet M, *et al*. Posterior cranial fossa single-hole arteriovenous fistulae in children: 14 consecutive cases. *Neuroradiology* 2004;**46**:474–81.
8. Aoki N, Sakai T, Oikawa A. Intracranial arteriovenous fistula manifesting as progressive neurological deterioration in an infant: case report. *Neurosurgery* 1991;**28**:619–22.
9. Barnwell SL, Ciricillo SF, Halbach VV, *et al*. Intracerebral arteriovenous fistulas associated with intraparenchymal varix in childhood: case reports. *Neurosurgery* 1990;**26**:122–5.
10. Suh DC, Alvarez H, Bhattacharya JJ, *et al*. Intracranial haemorrhage within the first two years of life. *Acta Neurochir (Wien)* 2001;**143**:997–1004.

11. **Garcia Monaco R**, Alvarez H, Goulao A, *et al*. Posterior fossa arteriovenous malformations. Angioarchitecture in relation to their hemorrhagic episodes. *Neuroradiology* 1990;**31**:471–5.
12. **Masuoka J**, Sakata S, Maeda K, *et al*. Intracranial pial single-channel arteriovenous fistula presenting with significant brain edema. *J Neurosurg* 2008;**109**:497–501.
13. **Passacantilli E**, Pichiéri A, Guidetti G, *et al*. Surgical treatment of pial cerebellar arteriovenous fistulas with aneurysm of the main feeding artery. *Surg Neurol* 2006;**65**:90–4.
14. **Weon YC**, Yoshida Y, Sachet M, *et al*. Supratentorial cerebral arteriovenous fistulas (AVFs) in children: review of 41 cases with 63 non choroidal single-hole AVFs. *Acta Neurochir (Wien)* 2005;**147**:17–31.
15. **Day AL**, Friedman WA, Sybert GW, *et al*. Successful treatment of the normal perfusion pressure breakthrough syndrome. *Neurosurgery* 1982;**11**:625–30.
16. **Siclari F**, Burger IM, Fasel JH, *et al*. Developmental anatomy of the distal vertebral artery in relationship to variants of the posterior and lateral spinal arterial systems. *AJNR Am J Neuroradiol* 2007;**28**:1185–90.

# JOURNAL OF Family Planning and Reproductive Health Care

BMJ Group are proud to announce that they will be publishing the **Journal of Family Planning and Reproductive Health Care** on behalf of the Faculty of Sexual and Reproductive Healthcare from 2011.

## A fresh perspective

Our aim is to further develop this highly regarded title, which publishes quality research and information relevant to clinical care, service delivery, training and education in the field of contraception and reproductive/sexual health.


The journal has an exciting new look and JFPRHC Online has been enhanced to provide useful resources and interactive features such as:

- Editor's choices
- Top 10 articles
- Podcasts
- Email alerts
- Online archive

BMJ Journals

Visit [jfprhc.bmj.com](http://jfprhc.bmj.com)  
to view the new site  
and to register for a

**FREE 30  
DAY TRIAL**



Copyright of Journal of NeuroInterventional Surgery is the property of BMJ Publishing Group and its content may not be copied or emailed to multiple sites or posted to a listserv without the copyright holder's express written permission. However, users may print, download, or email articles for individual use.