

Endovascular Angioplasty before Resection of a Sphenoidal Meningioma with Vascular Encasement

N. CHIVORET¹, D. FONTAINE¹, S. LACHAUD², Y. CHAU³, J. SEDAT³

¹ Department of Neurosurgery, ² Department of Neurology, ³ Department of Neuroradiology, Centre Hospitalier Universitaire de Nice; Nice, France

Key words: angioplasty, carotid artery, meningioma, stenosis, stroke, surgery

Summary

We describe a case of sphenoid wing meningioma presenting with cerebral infarction due to extended vascular encasement in which endovascular angioplasty was performed before surgery to avoid perioperative ischemia. A severe stenosis involved the intracranial internal carotid artery and the proximal segments of the middle and anterior cerebral arteries. Endovascular dilatation was followed by complete surgical resection. Preoperative mild aphasia and hemiparesia resolved completely after surgery. Endovascular angioplasty of arterial trunks and their branches can be proposed before the resection of skull base meningiomas encasing these arteries to decrease the risk of perioperative brain ischemia related to their surgical manipulation or vasospasm.

Case Report

Objective and importance

Resection of skull base meningiomas can be particularly challenging when they invade or encase arterial trunks and/or their branches¹. We describe a case of sphenoid wing meningioma presenting with cerebral infarction due to extended vascular encasement in which endovascular angioplasty has been performed before surgery in order to avoid perioperative ischemia.

Clinical presentation

A 44-year-old right-handed woman displayed acute right hemiparesia and aphasia. The National Institute of Health Stroke Score (NIHSS) score was 5. She had insulin-dependant diabetes with severe peripheral vascular complications (transmetatarsal amputation of the right foot two months earlier).

Brain magnetic resonance imaging (MRI) showed a recent ischemia (Figure 1A) in the territory of left middle (MCA) and anterior (ACA) cerebral arteries, a left meningioma (50×50×42 mm) inserted on the medial third of the sphenoid wing (Figure 1B,C). This meningioma encased and elongated the terminal segment of the internal carotid artery (ICA), the proximal segments of the MCA and ACA. The ischemia was probably directly related to the stenosis of these vessels.

Cerebral angiography (Figure 2A) confirmed the severe stenosis of the terminal segment of internal carotid artery (ICA), the A1 segment of ACA and the M1 segment of MCA, and showed a mild stenosis of the proximal segments of both temporal and frontal MCA division branches. The anterior communicating artery was permeable. Ethmoidal arteries fed the internal part of the meningioma and meningeal branches fed the external part. Aphasia and hemiparesia partially recovered within several days with treatment (antiplatelet agents, blood pressure monitoring and rehabilitation).

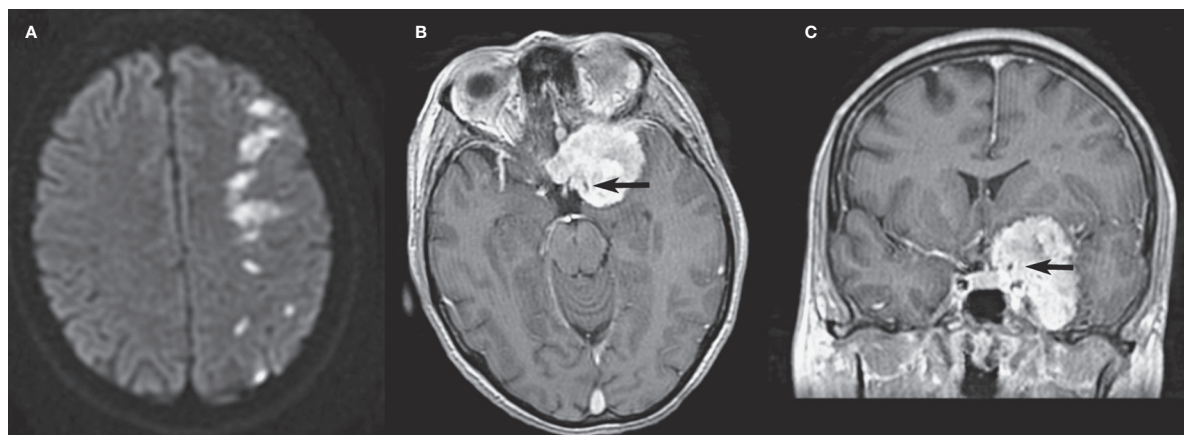


Figure 1 MRI at presentation. A) Axial diffusion-weighted image showing multiple hyperintense signals consistent with ischemia of the junction of middle cerebral artery (MCA) and anterior cerebral artery territories. B,C) Preoperative T1-weighted images after gadolinium injection in axial (B) and coronal (C) planes showing the sphenoid meningioma encasing the supraclinoid portion of the internal carotid artery (arrow) and the MCA.

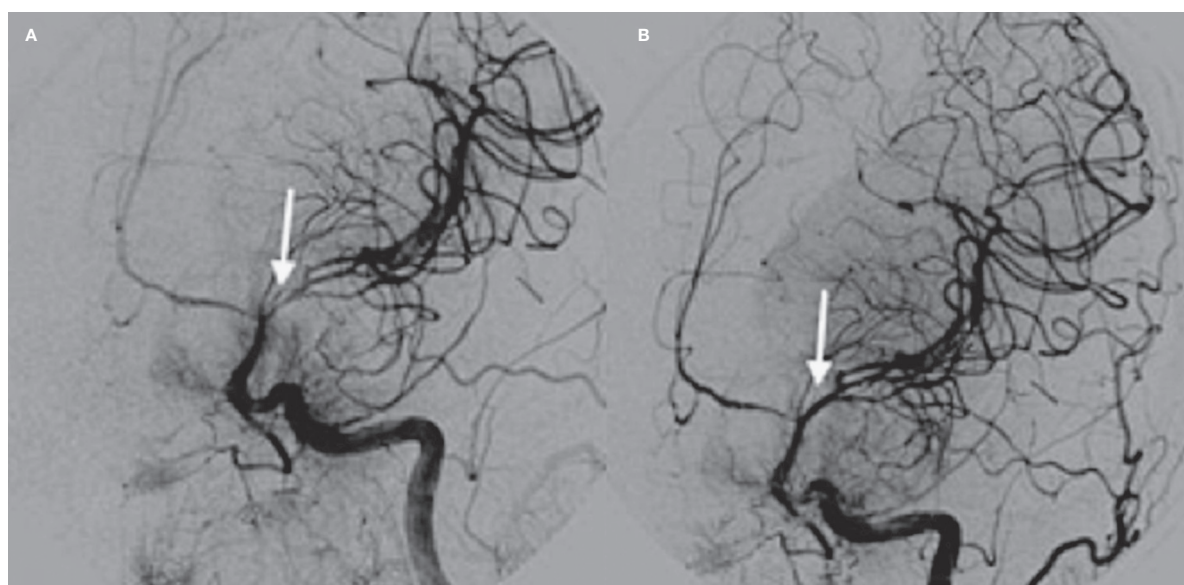


Figure 2 Left primitive carotid artery angiography (face view) before (A) and after (B) angioplasty. Before angioplasty, there is a severe stenosis of the terminal segment of internal carotid artery (ICA), the M1 segment of left middle cerebral artery (MCA) and the A1 segment of anterior cerebral artery (ACA). The post-treatment angiography confirmed the satisfactory dilatation of the MCA and ICA. ACA stenosis was unchanged.

Intervention

As the meningioma was symptomatic, a surgical resection was planned. In order to avoid perioperative ischemia due to surgical manipulation, elongation or vasospasm of the stenosed arteries, we performed a preoperative endovascular angioplasty. Three weeks after presentation, an 8F guiding catheter was introduced into the left ICA through the right femoral artery. The ICA and MCA stenoses (8 mm long) were dilated with a balloon catheter (Gateway

Boston Scientific®) (Figure 2B). No stent was placed because a satisfactory dilatation was obtained. After this procedure, the patient was treated with two antiplatelet agents (aspirin and clopidogrel) for three weeks. At that time, a new angiogram confirmed the persistence of the post angioplasty dilatation, allowing stopping the antiplatelet agents and performing the resection in good conditions. During this procedure, the meningeal arteries were embolized. Ten days later, the patient underwent a complete resection (Simpson II) of this sphenoid

meningioma (WHO grade I). No damage to vascular and/or nervous structures was observed. A left visual deficit and oculomotor nerve paresia occurred during the early postoperative period but both recovered completely within one month. Three months later, the postoperative MRI confirmed the complete resection (Figure 3).

Conclusion

Surgery of medial sphenoid wing meningiomas can be associated with significant nervous and vascular complications (morbidity rate 18%)². Severe stenosis of ICA and/or its branches, related to elongation, encasement or invasion by the meningioma, is thought to be predictive of a poor surgical outcome³. Although encasement of the ICA by a skull base meningioma is not rare, stroke related to this encasement is very rare. Two cases were published in 1983 for the first time and the estimated incidence is 0.19%⁴. In our case, we performed a preoperative angioplasty to reduce the risk of perioperative cerebral ischemia, because we estimated that this risk was particularly high due to i) the severity of the stenosis, ii) the poor vascular conditions related to the diabetes and iii) the fact that a stroke had previously occurred spontaneously.

To our knowledge, this is the first reported case where endovascular angioplasty of intracranial ICA and MCA stenosis, related to tumor compression, has been used to help the tumor resection. Several techniques are routinely proposed to treat atherosclerotic stenosis of the intracranial ICA or its branches, including angioplasty, stenting and extra-intracranial arterial bypass, but few reports concerned the treatment of vascular stenosis related to tumor compression. Heye et al.⁵ reported a case of stenosis of the intracavernous segment of the ICA, due to a meningioma, treated by endovascular stent placement. In this case, a stent was

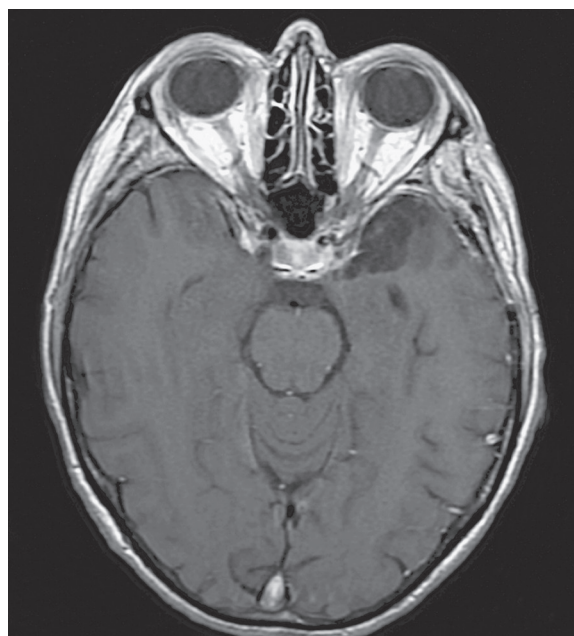

Figure 3 Postoperative MRI 4 months after surgery: T1-weighted sequence after gadolinium injection, showing complete resection of the meningioma.

implanted to avoid a re-stenosis after endovascular dilatation, because the meningioma was not removable. In our case, we did not implant a stent because immediate dilatation was satisfactory and maintained, and because the tumor compression was supposed to be removed quickly. Furthermore, the duration of the antiplatelet agents treatment needed after angioplasty is shorter than after stenting, which allows to perform surgery in a shorter delay. Extra-intracranial bypass was not considered in our case because the stenosis extended over to the two temporal and frontal MCA branches.

Endovascular angioplasty of intracranial arterial trunks and their branches (proximal segments) can be proposed before the resection of a skull base meningioma encasing these arteries. This management could decrease the risk of perioperative brain ischemia related to the surgical manipulation or vasospasm of the stenosed arteries.

References

- 1 Diluna ML, Bulsara KR. Surgery for petroclival meningiomas: a comprehensive review of outcomes in the skull base surgery era. *Skull Base*. 2010; 20: 337-342.
- 2 Russel SM, Benjamin V. Medial sphenoid ridge meningiomas: Classification, microsurgical anatomy, operative nuances, and long-term surgical outcome in 35 consecutive patients. *Oper Neurosurg*. 2008; 62 (Suppl 1): 38-50.
- 3 Ishikawa M., Nishi S., Aoki T, et al. Predictability of internal carotid artery dissectability in cases showing ICA involvement in parasellar meningioma. *J Clin Neurosci*. 2001; 8 (Suppl 1): 22-25.
- 4 Komotar R., Keswani S, Wityk R. Meningioma presenting as stroke: report of two cases and estimation of incidence. *J Neurol, Neurosurg Psych*. 2003; 74: 136-137.
- 5 Heye S, Maleux G, Van Loon J, et al. Symptomatic stenosis of the cavernous portion of the internal carotid artery due to an irresectable medial sphenoid wing meningioma: treatment by endovascular stent placement. *Am J Neuroradiol*. 2006; 27: 1532-1534.

Denys Fontaine, MD
Service de Neurochirurgie, Hôpital Pasteur
30 Avenue de la Voie Romaine
06000 Nice, France
Tel.: +33 492038528
Fax: +33 492038450
E-mail: fontaine.d@chu-nice.fr