

Sporadic Creutzfeldt–Jakob disease presenting as a stroke mimic

Introduction

Creutzfeldt–Jakob disease is a rare neurodegenerative disease in which there is an abnormal accumulation of prion protein. It occurs with an incidence of approximately 1 per million per year. Sporadic Creutzfeldt–Jakob disease occurs in approximately 85% of cases, with familial, variant and iatrogenic forms less common. Typically sporadic Creutzfeldt–Jakob disease presents with a rapidly progressive dementia, but sub-variants include the Heidenhain and Oppenheimer–Brownell variants. The former presents with visual disturbance and the latter with ataxia. This article describes a 75-year-old man with a Heidenhain variant of sporadic Creutzfeldt–Jakob disease who presented with a sudden onset of homonymous hemianopia mimicking a stroke.

Discussion

Sporadic Creutzfeldt–Jakob disease typically presents in patients aged 50–75 years, with prodromal symptoms of depression, apathy, paranoia or self neglect. These are often followed by a progressive dementia, myoclonus, ataxia and visual disturbance. The Heidenhain variant refers to a subgroup of patients with sporadic Creutzfeldt–Jakob disease who present with prominent visual symptoms at onset. It was first described by Heidenhain in 1929.

The exact definition of the Heidenhain variant is unclear. Although all agree that there is visual disturbance at onset, some suggest this has to be in isolation (Cooper et al, 2005) whereas others include those with visual disturbance and other neurological deficits such as dementia (Appleby et al, 2009; Kher et al, 2009). Using the definition of purely visual onset in the absence of cognitive, behavioural and physical symptoms for at least 2 weeks the Heidenhain variant made up only 3.7% of cases of sporadic Creutzfeldt–Jakob dis-

ease (Cooper et al, 2005). However, others report Heidenhain variant features in 20% of cases of sporadic Creutzfeldt–Jakob disease (Kropp et al, 1999).

The visual disturbance can be present for a few weeks before the onset of further neurological deficits. As the illness progresses features such as myoclonus, ataxia and pyramidal signs commonly occur (Cooper et al, 2005).

In one study of patients with the Heidenhain variant 86.7% presented with cortical blindness or oculomotor dys-

function and 13.3% with visual hallucinations (Appleby et al, 2009). However, disturbed colour perception, field restriction, blurred vision or visual neglect can occur (Kropp et al, 1999).

It is thought that patients with this clinical phenotype have a significantly shorter disease duration than classical sporadic Creutzfeldt–Jakob disease (Kropp et al, 1999). The majority of patients display periodic sharp waves on electroencephalogram and often magnetic resonance imaging shows increased signal in the basal gan-

Case Report

A 75-year-old male presented with a 2-week history of blurred vision and had a right homonymous hemianopia on visual field testing (*Figure 1*). Following this he started to develop unsteadiness and was seen in the transient ischaemic attack clinic. His past medical history consisted of hypertension, chronic obstructive pulmonary disease, gastro-oesophageal reflux disease and a cholesteatoma and mastoidectomy in 1984. There was no significant family history. Examination at this time was normal apart from the right homonymous hemianopia. A computed tomography brain scan and carotid Dopplers were unremarkable. He was started on stroke secondary prevention and discharged with a diagnosis of probable stroke.

He re-presented 4 weeks later with a progressive worsening of vision, difficulty with speech and increasing confusion which had been noticed by his family over the past few weeks. He described oscillopsia and that objects all appeared green in colour (xanthopsia). He had developed some expressive dysphasia and confusion. His wife had noticed some personality change. He had become aggressive, paranoid and anxious. The speech and language therapist noted fluctuating comprehension, perseveration and word-finding difficulties with word substitutes. Eight days after admission he became increasingly agitated and aggressive. The following day he was responding to visual hallucinations and trying to catch medicine tablets that he thought were floating around the room. At this time he also developed generalized myoclonus. A magnetic resonance imaging scan of his brain showed subtle hyperintensity within the cortical gyri in the left occipital and parietal region on fast fluid attenuated inversion recovery sequence and diffusion weighted imaging showed striking hyperintensity within the corresponding area (*Figure 2*). An electroencephalogram showed persistent lateralized periodic sharp waves, 205–300 ms in duration over the left hemisphere at rate of 1–2.5 Hz. These were also present over the right hemisphere to a lesser degree, otherwise background rhythm was preserved (*Figure 3*). A lumbar puncture was performed. Owing to lack of patient cooperation this was blood stained and therefore protein 14-3-3 was unable to be tested, but protein, glucose and cell counts were all normal.

He rapidly became cortically blind, incoherent and bed bound. Examination at this point revealed a Glasgow coma score of 9/15, pupils were equal and reactive but there was no response to visual menace and dolls eye movements were normal. Upper limb gegenhalten, a right grasp reflex and brisk reflexes with spontaneous myoclonus were noted. He continued to decline rapidly and died 3 weeks after his admission and 2 months after symptom onset. A post mortem was performed and revealed generalized spongiform degeneration particularly present in the parietal and occipital cortex, with a prion protein deposition of the synaptic type consistent with a diagnosis of Creutzfeldt–Jakob disease. There was also evidence of neurofibrillary tangles that were characteristic for Alzheimer's disease. The PRNP genotyping on brain tissue did not show any mutations which ruled out any possibility of an inherited prion disease. A definite diagnosis of sporadic Creutzfeldt–Jakob disease was therefore made.

Dr Claire L Hirst is Specialist Registrar in Neurology in the Department of Neurology, Morriston Hospital, Swansea SA6 6NL
(clairehirst_uk@yahoo.co.uk)

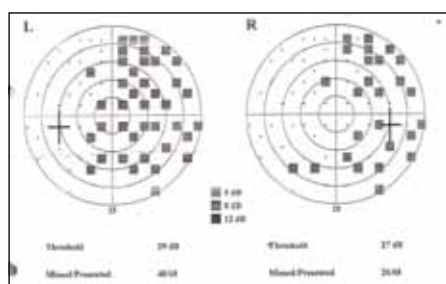


Figure 1. Visual fields showing a right homonymous hemianopia.

glia or hyperintensities in the occipital and visual cortices (Kropp et al, 1999). In some patients magnetic resonance imaging can be normal but abnormalities may be detected on diffusion weighted imaging (Lee et al, 1998; Zeidler and Green, 2004). While in this patient the abnormalities are seen on magnetic resonance imaging they are more marked on diffusion weighted imaging.

CSF examination often reveals the presence of protein 14-3-3 and a review has suggested that this has a sensitivity of 86%. Other CSF markers include s100b (an

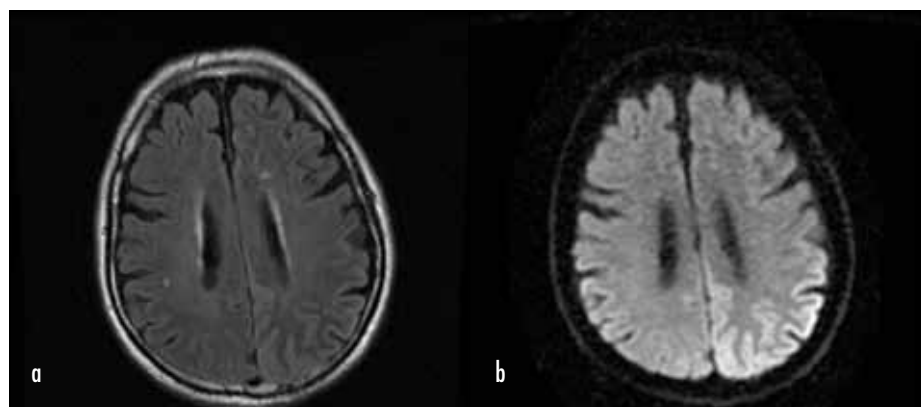


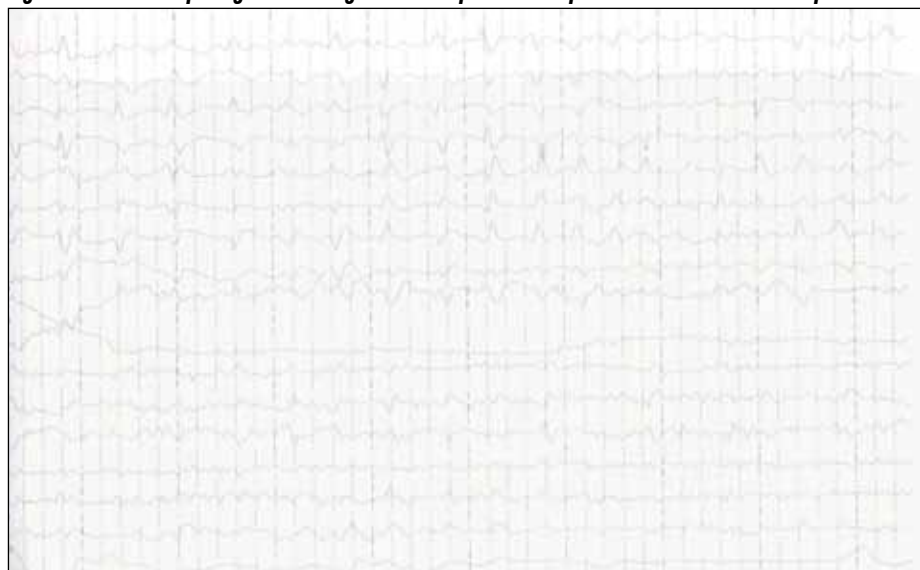
Figure 2. Magnetic resonance imaging of the brain. a. Fluid-attenuated inversion recovery sequence showing subtle hyperintensity in the cortical gyri of the left parietal and occipital lobe. b. Diffusion weighted imaging showing hyperintensity involving the left temporal lobe, the occipital lobe and the parietal lobe.

astrocyte marker) and tau (a neuronal marker). It has been suggested that the combination of a positive CSF 14-3-3 or an elevated tau protein with a raised S100b had the highest positive predictive power for sporadic Creutzfeldt–Jakob disease (Chohan et al, 2010). This patient did not have CSF 14-3-3 measured as the sample

was blood stained and it was felt that there was enough evidence without it to diagnose Creutzfeldt–Jakob disease.

The most common cause of an isolated homonymous hemianopia is stroke, accounting for 70% of cases. Other non-stroke causes include head injury, tumour and rarely neurosurgical procedures or multiple sclerosis. Infarction of the occipital lobe frequently may not produce other neurological manifestations and so can be confused with an early case of Heidenhain variant sporadic Creutzfeldt–Jakob disease. **BJHM**

Figure 3. Electroencephalogram showing lateralized periodic sharp waves over the left hemisphere.



LEARNING POINTS

- Creutzfeldt–Jakob disease is a rare neurodegenerative disease in which there is abnormal accumulation of prion protein. The Heidenhain variant presents with prominent visual symptoms at onset.
- Most patients display periodic sharp waves on electroencephalogram and magnetic resonance imaging often shows increased signal in the basal ganglia or hyperintensities in the occipital and visual cortices.
- Sporadic Creutzfeldt–Jakob disease can occasionally present as a stroke mimic and should be considered in a patient presenting with a possible stroke who goes on to have a progressive course.
- Sporadic Creutzfeldt–Jakob disease should be considered in a patient presenting with isolated visual disturbance in whom a cause cannot be found, particularly if there is subsequent neurological impairment.

- Appleby BS, Appleby KK, Crain BJ, Onyike CU, Wallin MT, Rabins PV (2009) Characteristics of established and proposed sporadic Creutzfeldt–Jakob disease variants. *Arch Neurol* **66**: 208–15
- Chohan G, Pennington C, Mackenzie JM et al (2010) The role of cerebrospinal fluid 14-3-3 and other proteins in the diagnosis of sporadic Creutzfeldt–Jakob disease in the UK: a 10-year review. *J Neurol Neurosurg Psychiatry* **81**: 1243–8
- Cooper SA, Murray KL, Heath CA, Will RG, Knight RS (2005) Isolated visual symptoms at onset in sporadic Creutzfeldt–Jakob disease: the clinical phenotype of the "Heidenhain variant". *Br J Ophthalmol* **89**: 1341–2
- Heidenhain A (1929) Klinische und anatomische Untersuchungen über eine eigenartige organische Erkrankung des Zentralnervensystems im Praesensium. *Z Ges Neurol und Psychiatr* **118**: 49–114
- Kher M, Rao MY, Acharya PT, Mahadevan A, Shankar SK (2009) Heidenhain variant of Creutzfeldt–Jakob disease: An autopsy study from India. *Ann Indian Acad Neurol* **12**: 48–51
- Kropp S, Schulz-Schaeffer WJ, Finkenstaedt M et al (1999) The Heidenhain variant of Creutzfeldt–Jakob disease. *Arch Neurol* **56**: 55–61
- Lee KE, Loh NK, Tan AK, Lee WL, Tjia HT (1998) Creutzfeldt–Jakob disease presenting with visual blurring, diplopia and visual loss: Heidenhain's variant. *Ann Acad Med Singapore* **27**: 854–6
- Zeidler M, Green A (2004) Advances in diagnosing Creutzfeldt–Jakob disease with MRI and CSF 14-3-3 protein analysis. *Neurology* **63**: 410–11