

Case Reports

A Case Of Utilization Behavior and Hyperorality Following Bilateral Anterior Cerebral Artery Infarct Partially Responsive to Carbamazepine: Can Both Behaviors Be Attributed To Lesions In Different Frontal Lobe Circuits?

David R. Spiegel, M.D., Kevin Lamm, M.D.

Case Report

Lhermitte (1983) coined the term “utilization behavior” (UB) to define a neurobehavioral syndrome in which the visuo-tactile presentation of objects compels patients to grasp and use them, despite the fact that they have not been instructed to do so. The author suggested that UB was the consequence of frontal lobe damage.¹ There are various interpretations as to the pathophysiology that brings about UB. Authors have described UB as an executive function deficit,¹ intimating impairment in dorsolateral frontal-subcortical circuits.² Yet, others have proposed disconnection between frontal and parietal lobe circuits or intra-frontal lobe pathology.³

Hyperorality and “bulimic type eating” (BTE) are symptoms of Kluver-Bucy Syndrome (KBS).⁴ While typically occurring after bilateral amygdala lesions/removal, others have suggested that symptoms of KBS may develop due to selective neurotoxicity in the basolateral amygdala and its cortical connections.⁵ Furthermore, the circuit between amygdala and cortex are reciprocal.⁶ Thus, disruption of a frontal-amygdalar circuit, with the latter projecting to the hypothalamus,⁷ may result in the production of Kluver-Bucy symptoms.⁸

We present a case of a woman with a bifrontal craniotomy and subsequent anterior cerebral artery cerebrovascular accident who developed manifestations of UB and Kluver-Bucy symptoms of hyperorality and BTE. We treated this patient with carbamazepine (CBZ), with the latter symptoms significantly improving, but the former essentially unchanged. We suggest that it is possible that this result may have occurred because while UB may not improve with CBZ, both bulimic type eating⁹ and symptoms of KBS have been reported to respond to treatment with CBZ.¹⁰

Ms. A, a 29-year-old female was admitted to the physical medicine and rehabilitation service of our hospital after treatment of a bifrontal parafalcine meningioma. She had no significant past medical/psychiatric/substance abuse history and initially presented after two episodes of altered mental status. Magnetic resonance image (MRI) was performed that revealed a large anterior fossa mass. She underwent embolization of two blood vessels supplying her meningioma, followed by a bifrontal craniotomy for resection of the meningioma. After 4 hours, she became nonverbal and stopped moving all extremities. MRI of the head showed bilateral anterior cerebral artery distribution infarct involving the parasagittal frontal lobes and left caudate nucleus. After a 7-week hospital stay, Ms. A was transferred to our hospital for further rehabilitation services.

Four days after transfer, the psychiatric consultation and liaison team was consulted for “difficult behavior and having periods of significant agitation.” Additionally, the staff reported that they had begun feeding her because when left alone with her meal tray she would eat so ravenously that she would choke. On our initial consultation, Ms. A was fully awake, though oriented only to person. She had significantly constricted affect and in-

Received December 8, 2010; revised January 9, 2011; accepted January 10, 2011. From Dept. of Psychiatry and Behavioral Sciences, Eastern Virginia Medical School, Norfolk, VA. Send correspondence and reprint requests to David R. Spiegel, M.D., Dept. of Psychiatry and Behavioral Sciences, Eastern Virginia Medical School, 825 Fairfax Avenue, Norfolk, VA 23507. e-mail: spiegedr@evms.edu

© 2011 The Academy of Psychosomatic Medicine. Published by Elsevier Inc. All rights reserved.

Case Reports

creased speech latency, and during the interview she would bite a stuffed animal she was holding. While testing for grasp and rooting reflexes the patient pinched the examiner and tried to bite the examiner's hand. Her Mini Mental State Examination (MMSE)¹¹ score was 19. When asked specific questions she would often look around the room for answers. For example, when asked who the president was, she would read the interviewer's badge or point to people in the room. Despite not knowing these answers, she seemed unconcerned. Further, she would take a pen and write on paper if it was in front of her, but would continue to attempt to write even after the paper was taken away. Ms. A made several attempts to drink from any empty cup if it was within reach. She scored 3 on severity for the following subsections on Neuropsychiatric Inventory Questionnaire (NPI-Q)¹²: apathy/indifference (A/I), disinhibition (D), and appetite/eating (A/E), while scoring a 1 on the agitation/aggression (A) and irritability/lability (I) subsections. Her laboratory work-up was unremarkable, but an electroencephalogram showed continuous slowing over the frontal region, consistent with lesions.

Ms. A was started on, and titrated to, CBZ 400 mg BID (blood level of 9 mcg/mL) in an attempt to treat disinhibited behaviors. While her MMSE remained the same, A/E and D subscales decreased to 1, A/I score remained at 3 and A, I subscales continued to score 1. Interestingly, improvement in eating behavior occurred such that staff no longer had to feed her for her protection; however, her previously mentioned behavior with the pen and empty cup did not attenuate. Eventually Ms. A was discharged to hospice care due to formation of deep vein thrombosis/pulmonary emboli and she expired within 1 month of discharge.

Discussion

Phenomenology. Our case report seems to demonstrate two groups of symptoms, which, in part, may be interconnected: UB and hyperorality and bulimic-type eating. Various frontal-subcortical circuit syndromes are known to include apathy, disinhibition, and executive function deficits, including impersistence and stimulus-bound behavior. Lhermitte introduced the term "utilization behavior," which he observed among patients affected with left or right unilateral, or bilateral, frontal lesions. He explained it as an extension of bilateral manual grasping behavior ("magnetic apraxia"), and believed that UB is the auto-

matic elicitation of instrumentally correct, yet highly exaggerated and/or inappropriate motor responses to environmental cues/objects.¹³

For clarity's sake, a further delineation of hyperorality, pathologic grasp (reflex), and BTE, will be defined. Hyperorality describes nonselective placing of edible or inedible objects to a person's mouth.⁴ Pathologic grasp (i.e., reflex) may be described as the automatic tendency to grip objects or other stimuli. Additionally, attempts to withdraw the stimulating object may result in strengthening of the grasp.¹³ Finally, BTE is described as eating an amount of food in a discrete time that is considered excessive in view of the situational context, with the associated feature of eating more rapidly than normal.¹⁴

Patients with frontal lobe damage often appear to be easily distracted and strongly influenced by irrelevant external stimuli, such that they have difficulty behaving in accordance with the plans or intentions that they have created. Theoretically, UB is explained as resulting from a loss of frontal inhibitory control over more automatic behaviors, i.e., an imbalance between frontal (internally generated) and parietal (externally or environmentally driven) systems. Abnormal behaviors may be triggered by externally oriented systems responsive to environmental input, if there is a loss of frontally-based inhibitory controls that mediate more purposeful, volitional, and internally generated behavior.

Certain behaviors of Ms. A may be attributed to UB, such as her persistent attempts to drink from an empty cup and continued writing movements when the paper was removed. Interestingly, neuropathologic observations by Lhermitte and others reported that lesions of the orbital surface of the frontal lobe, and sometimes the head of the caudate nucleus, were involved in UB. Thus, our patient's UB is supported, in part, by structural findings on MRI.

The target symptoms that responded to CBZ treatment were the hyperorality and BTE, with near choking episodes. Certainly, hyperorality and BTE could be attributed to UB, i.e., rapid unrestrained eating of food present in the environment. However, hyperorality and BTE are also Kliver-Bucy symptoms. Typically associated with temporal lobe pathology, the entire syndrome has been described elsewhere.⁵ Nonetheless, Ms. A did not have identified temporal lobe pathology on MRI. We propose a potential different pathophysiologic explanation for her hyperorality and BTE, based upon the lack of response of all other UB symptoms to CBZ.

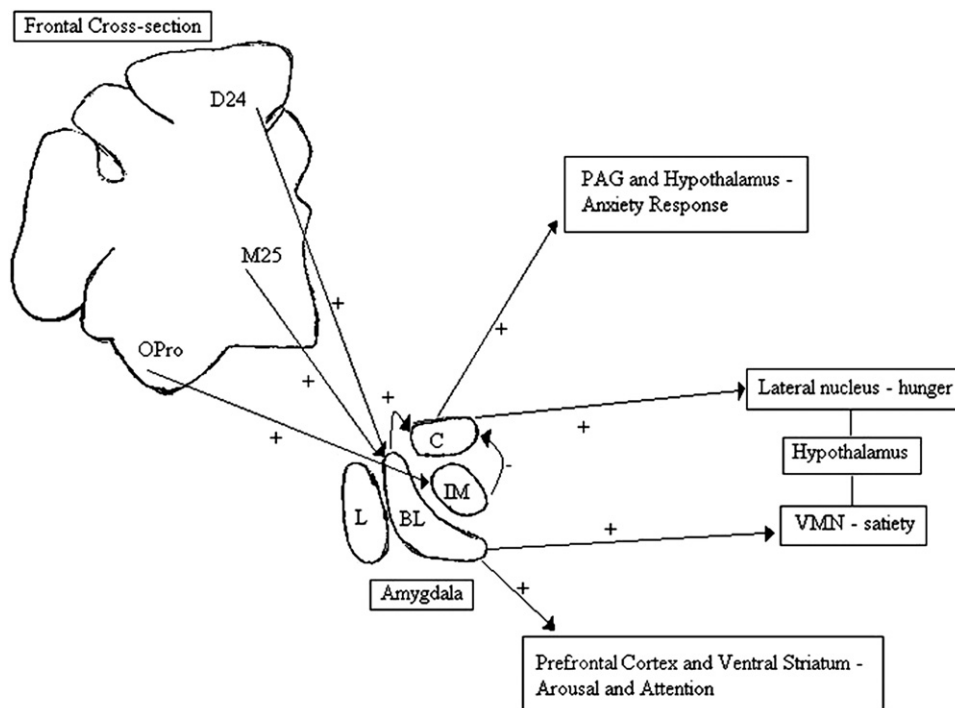
Anatomy/Physiology. Neuroanatomically, it has been reported that stereotypic behavior and change in behavior

related to food, reflects the involvement of a common network—namely, the orbitofrontal cortex, temporal pole, and amygdala.¹⁵ Additionally, neural projections exist from distinct amygdalar nuclei and orbitofrontal cortex to the lateral hypothalamus, a key center for the initiation of feeding. What is being encoded by the projections from amygdala and orbitofrontal cortex to the hypothalamus remains to be established. It has been proposed that these connections may convey a nonspecific reward signal that blindly increases appetitive behaviors.¹⁶

Both the temporal pole and amygdala are heavily interconnected with the orbitofrontal lobe with the amygdala having reciprocal connections with both orbitofrontal and anterior cingulate cortex.¹⁵ The orbitofrontal cortex has long been associated with regulating inhibitory control and damage leads to a failure to inhibit inappropriate responses.² Additionally, lesion studies in rats demonstrate that efferent projections from the posterodorsal amygdala to the hypothalamus leads to BTE, obesity, and sexual dysregulation.¹⁷ Thus, while amygdalofugal connectivity may be a final common pathway leading to hyperorality/BTE, amygdala dysregulation can be precipitated by frontal lobe lesions, the latter occurring in our patient.

Treatment. We chose CBZ because of past reports of its utility for the treatment of disinhibition in neuropsychiatric patients¹⁸ and BTE⁹—our “a priori target symptoms.” One of several possible mechanisms of action of CBZ is as an augmenter of the gamma amino butyric acid (GABA) system, which is primarily inhibitory in function.¹⁸ Additionally, cortical neurons project glutamatergic efferents to the amygdala (and visa-versa). It is tempting to speculate that a frontal lobe lesion could result in decreased excitatory transmission to the amygdala, resulting in a hypofunctioning amygdala with resultant hyperorality/BTE. Thus, increasing inhibitory transmission via CBZ could inhibit inhibitory transmission resulting in successful treatment of our patient’s altered eating behavior. However, it is unclear if transmission between “amygdalofrontal” or amygdalofugal circuits are mono- or polysynaptic in nature. Thus, a direct effect of CBZ on this circuit can only be speculative.¹⁹ Furthermore, the prefrontal cortex has direct projections to the lateral hypothalamus. Thus, it is also possible that amygdala/medial temporal lobe is completely bypassed and that CBZ might directly affect prefrontal-hypothalamic pathways.¹⁶ (see Figure 1).

FIG. 1. Schematic of the Discussed Interactions Between Frontal Cortex, Amygdala, and Hypothalamus.



OPro = orbitofrontal area; D24 = dorsal area 24; M25 = medial area 25; L = lateral nucleus; BL = basolateral nucleus; IM = intercalated masses; C = central nucleus; PAG = periaqueductal gray matter; (+) = excitatory; (-) = Inhibitory; VMN = ventromedial nucleus.

Case Reports

CBZ had no effect on apathy or Ms. A's UB. While an explanation for this is beyond the scope of this manuscript, in the frontal-subcortical circuits, the corticostriatal information processing is modulated by different neurotransmitter systems. Dopaminergic neurons from the substantia nigra/midbrain, project to the striatum and affect all frontal-subcortical functions. There are nigral connections with the limbic circuits, which are rich in dopamine (DA) (DA₃ and DA₄) receptor subtypes. This allows the interaction between emotional input and motor activity and motivation. This anatomical structure forms the basis for multiple actions of dopaminergic agents including effects on motivation and behavior. As one of the roles of anterior cingulate circuit is to subserve motivation, lesions in this circuit can cause apathy; hence, the role potential of DA agonists, not medications that facilitate GABA transmission, for the treatment of apathy.

Additionally, certain studies indicate high levels of UB in approximately one-half of the children with Attention Deficit/Hyperactivity Disorder (ADHD), whereas almost no such behavior was observed in controls. Levels of UB were statistically associated with the severity of hyperactivity.²⁰ Positron emission tomography studies of DA receptor binding have implicated abnormality of DA at the level of the midbrain in adolescents, and at the level of frontal lobe in adults, with ADHD. These findings have been interpreted as suggesting that the frontal dopaminergic abnormality seen in adults with ADHD occurs secondary to a subcortical

dopaminergic deficit interacting with neurodevelopmental changes. Thus, medications that enhance dopaminergic transmission might be more suitable for treating UB,²¹ which, in our patient, was unaffected by CBZ.

In conclusion, we propose that both UB and certain Kluver-Bucy symptoms, such as hyperorality and BTE, can develop as a result of frontal lobe pathology. It would certainly seem that our patient's hyperorality/BTE did not occur due to direct medial temporal cortex/amygdalar lesions. However, the frontal lobes are a complex and highly interconnected area of the brain with five known parallel frontal-subcortical neuronal circuits.² Thus, since there are demonstrated reciprocal frontal-amygdalar circuits as well as amygdalofugal pathways, indirect involvement of the amygdala through frontal lobe pathology (with the latter occurring in Ms. A), and subsequent involvement of lateral hypothalamus, could also result in hyperorality and BTE. Similarly, with bidirectional frontal-hypothalamic circuits, frontal lobe lesions can also directly affect lateral hypothalamus, potentially resulting in BTE. Therein lies the major limitation of our case report, in that while these multiple circuits do exist, whether lesions in any/all of these circuits do result in hyperorality (or other Kluver-Bucy symptoms) would require further research, perhaps with functional rather than structural scans. Furthermore, we believe that larger scale randomized trials are warranted in treating frontal-hypothalamic or frontal-amygdalo-hypothalamic circuit-induced Kluver-Bucy symptoms, such as hyperorality, or BTE with anticonvulsants, such as CBZ.

References

1. Besnard J, Allain P, Aubin G, et al: Utilization behavior: clinical and theoretical approaches. *J Int Neuropsychol Soc* 2010;16: 453–462
2. Tekin S, Cummings JL: Frontal-subcortical neuronal circuits and clinical neuropsychiatry: an update. *J Psychosom Res* 2002; 53:647–654
3. Eslinger PJ: The anatomic basis of utilisation behaviour: a shift from frontal-parietal to intra-frontal mechanisms. *Cortex* 2002; 38:273–276
4. Mendez MF, Foti DJ: Lethal hyperoral behaviour from the Kluver-Bucy syndrome. *J Neurol Neurosurg Psychiatry* 1997; 62: 293–294
5. Hayman LA, Rexer JL, Pavol MA, et al: Kluver-Bucy syndrome after bilateral selective damage of amygdala and its cortical connections. *J Neuropsychiatry Clin Neurosci* 1998; 10:354–358
6. Stalnaker TA, Roesch MR, Calu DJ, et al: Neural correlates of inflexible behavior in the orbitofrontal-amygdalar circuit after ter cocaine exposure. *Ann N Y Acad Sci* 2007; 1121:598–609
7. Petrovich GD, Setlow B, Holland PC, et al: Amygdalo-hypothalamic circuit allows learned cues to override satiety and promote eating. *J Neurosci* 2002; 22:8748–8753
8. Winstanley CA, Theobald DE, Cardinal RN, et al: Contrasting roles of basolateral amygdala and orbitofrontal cortex in impulsive choice. *J Neurosci* 2004; 24:4718–4722
9. McElroy SL, Guerdjikova AI, Martens B: Role of antiepileptic drugs in the management of eating disorders. *CNS Drugs* 2009; 23:139–156
10. Stewart JT: Carbamazepine treatment of a patient with Kluver-Bucy syndrome. *J Clin Psychiatry* 1985; 46:496–497
11. Folstein MF, Folstein SE, McHugh PR: "Mini-Mental State." A practical method for grading the cognitive state of patients for the clinician". *J Psychiatr Res* 1975;12:189–198
12. Kaufer DI, Cummings JL, Ketchel P, et al: Validation of the NPI-Q, a brief clinical form of the Neuropsychiatric Inventory. *J Neuropsychiatry Clin Neurosci* 2000;12:233–239
13. Archibald SJ, Mateer CA, Kerns KA: Utilization behavior: clinical manifestations and neurological mechanisms. *Neuropsychol Rev* 2001; 11:117–130

14. Treasure J, Claudino AM, Zucker N: Eating disorders. *Lancet* 2010; 375:583–593
15. Ghashghaei HT, Hilgetag CC, Barbas H: Sequence of information processing for emotions based on the anatomic dialogue between prefrontal cortex and amygdala. *Neuroimage* 2007; 34: 905–923
16. Seymour B: Carry on eating: neural pathways mediating conditioned potentiation of feeding. *J Neurosci* 2006; 26:1061–1062
17. Kile SJ, Ellis WG, Olichney JM, et al: Alzheimer abnormalities of the amygdala with Kluver-Bucy syndrome symptoms: an amygdaloid variant of Alzheimer disease. *Arch Neurol* 2009; 66:125–129
18. Spiegel DR, Qureshi N: The successful treatment of disinhibition due to a possible case of non-human immunodeficiency virus neurosyphilis: a proposed pathophysiological explanation of the symptoms and treatment. *Gen Hosp Psychiatry* 2010; 32:221–224
19. Cohen MX, Elger CE, Weber B: Amygdala tractography predicts functional connectivity and learning during feedback-guided decision-making. *NeuroImage* 2008; 39:1396–1407
20. Archibald SJ, Kerns KA, Mateer CA, et al: Evidence of utilization behavior in children with ADHD. *J Int Neuropsychol Soc* 2005 ;11:367–375
21. Roth RM, Saykin AJ: Executive dysfunction in attention-deficit/hyperactivity disorder: cognitive and neuroimaging findings. *Psychiatr Clin North Am* 2004; 27:83–96, ix