

# Direct Thrombectomy Using the Penumbra Thromboaspiration Catheter for the Treatment of Cerebral Venous Sinus Thrombosis

Gregory J. Velat<sup>1</sup>, Christopher J. Skowlund<sup>1</sup>, Michael F. Waters<sup>2</sup>, J Mocco<sup>1</sup>, Brian L. Hoh<sup>1</sup>

## Key words

- Cerebral venous sinus thrombosis
- Coagulopathy
- Superior sagittal sinus
- Thrombectomy
- Thromboaspiration

## Abbreviations and Acronyms

CT: Computed tomography

CVST: Cerebral venous sinus thrombosis

MRV: Magnetic resonance venography

SSS: Superior sagittal sinus



From the Departments of <sup>1</sup>Neurological Surgery and <sup>2</sup>Neurology, McKnight Brain Institute, University of Florida, Gainesville, Florida, USA

To whom correspondence should be addressed:

Gregory J. Velat, M.D.

[E-mail: [gregory.velat@neurosurgery.ufl.edu](mailto:gregory.velat@neurosurgery.ufl.edu)]

Citation: *World Neurosurg.* (2012) 77, 3/4:591.e15-591.e18.

DOI: 10.1016/j.wneu.2011.02.020

Journal homepage: [www.WORLDNEUROSURGERY.org](http://www.WORLDNEUROSURGERY.org)

Available online: [www.sciencedirect.com](http://www.sciencedirect.com)

1878-8750/\$ - see front matter © 2012 Elsevier Inc.

All rights reserved.

## INTRODUCTION

Cerebral venous sinus thrombosis (CVST) is a rare disease that accounts for less than 1% of all strokes (20). Both genetic and environmental factors are believed to contribute to intracranial dural sinus thrombosis, including hereditary coagulopathies, infection of cranial sinuses, trauma, smoking, and use of oral contraceptives. Systemic thrombolysis with the use of heparin with conversion to oral warfarin is the most widely accepted treatment for CVST. Direct mechanical thrombolysis is typically reserved for thrombi refractory to pharmacologic management or for patients with acute neurological deterioration. Recent advances in neurointerventional devices have expanded endovascular treatment modalities for CVST. We describe the successful use of the Penumbra thromboaspiration catheter (Alameda, California, USA) in the management of a young woman who pre-

■ **OBJECTIVE:** Cerebral venous sinus thrombosis (CVST) is a rare cause of stroke. A 21 year-old female presented to our institution in a rapidly deteriorating neurological state following failed systemic heparin therapy for treatment of superior sagittal sinus (SSS) thrombosis.

■ **METHODS:** The patient underwent emergent mechanical thrombectomy of the thrombosed SSS using the 0.054-inch Penumbra catheter. No adjuvant direct pharmacologic and/or mechanical thrombectomy was performed.

■ **RESULTS:** Successful venous recanalization was achieved using the Penumbra system. The patient improved symptomatically following the intervention, and she made a complete neurological recovery within 30 days. At 6-month follow-up, the patient had returned to work and school and remained neurologically intact. A repeat MRV showed complete sinus recanalization.

■ **CONCLUSION:** Direct mechanical thrombectomy using the Penumbra system provided rapid sinus recanalization for the treatment of symptomatic cerebral venous sinus thrombosis. This device is a valuable addition to the neurointerventional armamentarium.

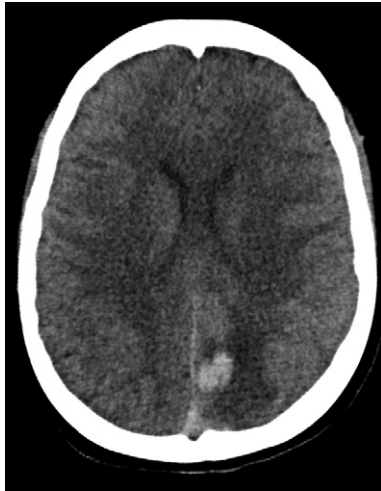sented to our institution in a rapidly deteriorating neurological state secondary to superior sagittal sinus (SSS) thrombosis.

## CASE PRESENTATION

A 21-year-old right-handed woman presented to an outside hospital in January of 2010 with complaints of severe, progressively worsening headaches. The patient had been dehydrated for several weeks before presentation secondary to a gastrointestinal illness. Initial laboratory testing revealed an elevated creatinine level ( $>4.0$ ). The patient denied any previous history of coagulopathy or tobacco product use but was taking daily oral contraceptives. She remained neurologically intact at the time of admission to the outside hospital. A contrasted computed tomography (CT) scan of the head revealed an "empty delta sign" with thrombus filling the posterior SSS and early edema in the left parietal and occipital lobes. No evidence of hemorrhagic transformation was noted. She was started on an intravenous heparin drip for treatment of

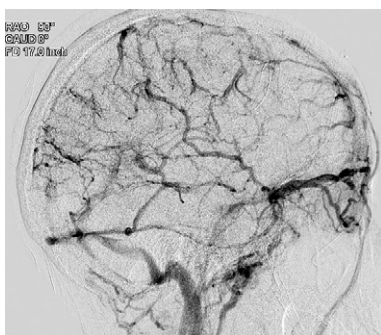the SSS thrombus. The patient experienced a rapid decline in her neurological status on the morning of her third hospital day with subsequent right-sided hemiparesis (1/5 strength in the arm and leg) and obtundation. She was transferred to our hospital and admitted to the neurointensive care unit. A repeat noncontrasted head CT revealed hemorrhagic venous infarctions involving the left frontoparietal and occipital lobes as well as the right orbitofrontal region (**Figure 1**). On the basis of the patient's rapidly declining clinical status despite anticoagulation therapy, she was taken emergently to the endovascular suite. Her obtundation improved somewhat following a bolus of mannitol. A 6-Fr sheath was placed into the right common femoral artery and a cerebral angiogram was performed with a 5-Fr diagnostic catheter.

The posterior third of the SSS was occluded with retrograde filling of contrast into several large cortical veins (**Figure 2**). A 6-Fr sheath was then placed into the right femoral vein. A 5-Fr diagnostic catheter was then advanced over an angled glide wire

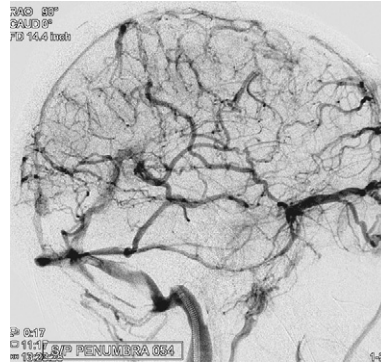


**Figure 1.** Noncontrasted head CT obtained following the patient's rapid neurological decline revealing hemorrhagic conversion of a venous infarction involving the left parieto-occipital region. Note the persistent hyperdense thrombus in the posterior superior sagittal sinus (SSS) despite systemic heparinization. A small right orbitofrontal hemorrhagic venous infarction was observed on a higher axial cut (not pictured).

(Terumo, Somerset, New Jersey, USA) into the left transverse sinus. A Cook exchange-length wire (Bloomington, Indiana, USA) was then navigated into the left transverse sinus, and the 5-Fr guide catheter was exchanged for a 6-Fr Terumo destination sheath (Somerset, New Jersey, USA). The 0.054-inch Penumbra thromboaspiration catheter was then navigated over an Agility 14 microwire (Cordis Neurovascular, Miami, Florida, USA) through the thrombus



**Figure 2.** Lateral digital subtraction angiogram illustrating thrombosis of the posterior superior sagittal and proximal transverse sinuses. Note delayed contrast filling of multiple cortical veins consistent with venous hypertension.



**Figure 3.** Lateral digital subtraction angiogram after thrombolysis using the 0.054-inch Penumbra thromboaspiration catheter. There is improved venous flow through the SSS.

into the anterior portion of the SSS. Suction was then applied through the Penumbra catheter ( $-25$  inches of Hg) and mechanical thrombectomy was performed over 5 minutes with use of the Penumbra separator wire in an anterior to posterior direction. Brisk venous blood was aspirated after breaking up several large pieces of clot.

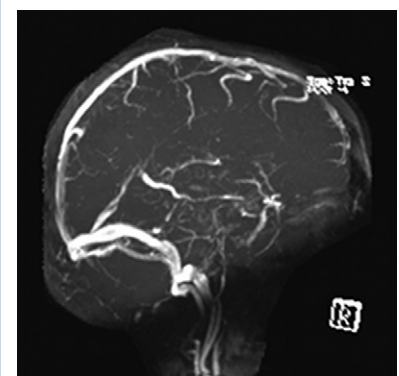
An angiogram was then performed, which demonstrated subtotal, but successful recanalization of the SSS (**Figure 3**). Repeat angiography was performed after 10 minutes confirming blood flow through the affected sinus. The patient's obtundation improved within 20 minutes of mechanical thrombectomy; thus, no additional thrombolytic agents were administered and no additional passes with the Penumbra catheter were attempted. All catheters were then removed, and the patient returned to the neurointensive care unit for frequent neurological checks. She remained on intravenous heparin after the procedure. Less than 12 hours after the intervention, the patient's level of consciousness significantly improved to following complex commands bilaterally. She regained orientation to self and would open her eyes to verbal cues. Her right-sided strength improved to 3/5 in the arm and leg. A hematology consultation was obtained, and the patient was started on therapeutic twice-daily subcutaneous fractionated heparin with discontinuation of the intravenous heparin drip.

She experienced several generalized tonic-clonic seizures after recanalization that were aggressively managed with several an-

tiepileptic medications administered by the neurology service. The patient's neurological status normalized on postprocedure day 4 with the exception of 4/5 strength in the right arm and leg. She was transferred to the general neurosurgery ward and discharged to a rehabilitation facility shortly thereafter on warfarin and valproic acid for seizure prophylaxis. By 30-day follow-up, the patient's right-sided hemiparesis had completely resolved, and she returned to her baseline neurological status. Her coagulopathy panel revealed a heterozygous mutation of the prothrombin gene for which she was prescribed a 12-month regimen of warfarin per hematology recommendations. At 6-month follow-up, the patient had returned to work and continued her undergraduate studies without additional seizures. Her valproic acid was tapered off, and she abstained from taking oral contraceptives. A follow-up magnetic resonance venography (MRV) revealed complete sinus recanalization (**Figure 4**).

## DISCUSSION

CVST is an infrequent cause of stroke. The exact incidence of CVST is unknown but ranges from 0.03% to as high as 9% on autopsy series (5, 12, 15, 26). Various factors are believed to contribute to CVST, such as hypercoagulable states, infection of cranial sinuses and otitis, as well as the use of oral contraceptives and tobacco products. Interestingly, as high as 40% of cases are thought to be idiopathic (6). CVST is more common in young women, particularly during puerperium (3, 6). Headache is



**Figure 4.** Six-month follow-up magnetic resonance venography (MRV) revealing complete sinus recanalization.

the most common presentation and is estimated to occur in up to 80% of cases (6). Other symptoms related to elevated intracranial pressure are common including nausea with or without emesis and visual disturbances. Focal neurological deficits and/or seizures may occur in conjunction with venous hypertension or related cerebral infarction and/or hemorrhage (22). The goal of therapy is to recanalize the affected venous sinus(es) to improve clinical signs and symptoms. Patients with rapid neurological decline secondary to venous hypertension and/or intracranial hemorrhage should be considered for direct thrombolysis.

Several publications have described the use of chemical thrombolytics, including intravenous heparin (14) and low molecular weight heparin (11) with varying clinical results. The International Study on Cerebral Vein and Dural Sinus Thrombosis was a multinational, prospective observational study that enrolled 624 adult patients diagnosed with CVST (16). Although the choice of therapy was not regimented, 520 (83%) of the patients were anticoagulated acutely with either intravenous heparin (64%) or low-molecular-weight heparin (35%). At a median follow-up time of 16 months, 57% of patients were asymptomatic, and approximately 32% of patients had mild or moderate impairments. Patient factors predictive of worse outcome on multivariate analysis included coma at the time of presentation, thrombosis of deep cerebral veins, cancer, and central nervous system infection. Patients are then typically transitioned over to oral warfarin and maintained on anticoagulation with a goal international normalized ratio between 2 and 3 for 6 months. Prolonged anticoagulation is recommended for patients with hereditary thrombophilias or recurrent CVST (13).

Direct thrombolysis may be performed with the use of pharmacologic agents and thrombectomy via mechanical techniques. The earliest published reports involved prolonged local infusions of urokinase into the superior sagittal sinus through direct sinus cannulation following either midline craniotomy (23) or percutaneous transcranial puncture (17). Direct mechanical thrombectomy also has been described in the treatment of CVST. Balloon catheter thrombectomy (7, 24, 25), rheolytic therapy with the AngioJet catheter system (Possis Medi-

cal, Minneapolis, Minnesota, USA) (2, 4, 9, 10, 27), and snare devices (21) have been successfully used to achieve sinus recanalization. The AngioJet system, which was designed for use as a thromboaspiration catheter in cardiovascular applications, is relatively rigid and difficult to navigate through the intracranial circulation.

Recently, technological innovations have yielded mechanical devices with improved handling properties and navigability for the treatment of acute arterial stroke. The Merci clot retriever (Concentric Medical, Mountain View, California, USA) is a snare-type device that removes thrombus in a corkscrew fashion using a series of coiled wires. This device was used in combination with local recombinant tissue plasminogen activator infusion by Khan et al. (18) to restore flow in the SSS of a middle-aged woman. She required repeat mechanical thrombectomy with a 5-Fr Pronto V3 catheter (Vascular Solutions, Incorporated, Minneapolis, Minnesota, USA) for a decline in neurological status on postprocedure day 1.

The Penumbra system achieves mechanical clot lysis using a separator wire under vacuum suction. Kulcsar et al. (19) recently performed serial mechanical thrombectomies (at 0, 24, and 48 hours) using the 0.041-inch Penumbra device in combination with a 60-hour infusion of local urokinase (50,000 U/h) to successfully recanalize a thrombosed SSS in a 16-year-old female patient. Follow-up one-year MRV revealed complete patency of the superior sagittal and right transverse sinuses with persistent occlusion of the left transverse and sigmoid sinuses. Choulakian and Alexander (8) recently described four adult patients with CVST who underwent mechanical thrombectomy using the 0.041-inch Penumbra system. Three patients received adjuvant balloon angioplasty to achieve satisfactory flow. No direct pharmacologic thrombolysis was performed, but three patients received postprocedural systemic anticoagulation. Follow-up MRV was available for one patient, which showed sinus patency at 3 months.

This case report details successful recanalization of a thrombosed intracranial sinus in an adult patient using the 0.054-inch Penumbra thromboaspiration catheter without adjuvant local pharmacologic thrombolysis or additional mechanical interventions such as balloon angioplasty. The larger internal

diameter of this catheter allows for stronger thromboaspiration, potentially effecting more rapid sinus recanalization. The patient did not require direct chemical thrombolysis or repeat mechanical interventions, as she showed clinical improvement immediately following mechanical thrombectomy. She had a complete recovery and returned to work less than one month after the procedure. At six-month follow-up, the patient remained neurologically intact without any interval seizures and complete sinus recanalization on MRV. The Penumbra device, which has been shown to be a valuable tool in the management of acute arterial ischemic stroke (1), may prove effective in the rapid recanalization of thrombosed intracranial dural sinuses.

## REFERENCES

1. The Penumbra Pivotal Stroke Trial: safety and effectiveness of a new generation of mechanical devices for clot removal in intracranial large vessel occlusive disease. *Stroke* 40:2761-2768, 2009.
2. Agner C, Deshaies EM, Bernardini GL, Popp AJ, Boulos AS: Coronary angiojet catheterization for the management of dural venous sinus thrombosis. Technical note. *J Neurosurg* 103:368-371, 2005.
3. Ameri A, Bousser MG: Cerebral venous thrombosis. *Neurol Clin* 10:87-111, 1992.
4. Baker MD, Opatowsky MJ, Wilson JA, Glazier SS, Morris PP: Rheolytic catheter and thrombolysis of dural venous sinus thrombosis: a case series. *Neurosurgery* 48:487-493; discussion 493-484, 2001.
5. Barnett HJM, Hyland HH: Non-infective intracranial venous thrombosis. *Brain* 76:36, 1953.
6. Bousser MG, Chiras J, Bories J, Castaigne P: Cerebral venous thrombosis—a review of 38 cases. *Stroke* 16:199-213, 1985.
7. Chaloupka JC, Mangla S, Huddle DC: Use of mechanical thrombolysis via microballoon percutaneous transluminal angioplasty for the treatment of acute dural sinus thrombosis: case presentation and technical report. *Neurosurgery* 45:650-656; discussion 656-657, 1999.
8. Choulakian A, Alexander MJ: Mechanical thrombectomy with the penumbra system for treatment of venous sinus thrombosis. *J NeuroIntervent Surg* 2:153-156, 2010.
9. Chow K, Gobin YP, Saver J, Kidwell C, Dong P, Vinuela F: Endovascular treatment of dural sinus thrombosis with rheolytic thrombectomy and intra-arterial thrombolysis. *Stroke* 31:1420-1425, 2000.
10. Curtin KR, Shaibani A, Resnick SA, Russell EJ, Simuni T: Rheolytic catheter thrombectomy, balloon angioplasty, and direct recombinant tissue



- plasminogen activator thrombolysis of dural sinus thrombosis with preexisting hemorrhagic infarctions. *AJNR Am J Neuroradiol* 25:1807-1811, 2004.
11. de Bruijn SF, Stam J: Randomized, placebo-controlled trial of anticoagulant treatment with low-molecular-weight heparin for cerebral sinus thrombosis. *Stroke* 30:484-488, 1999.
12. Ehler H, Courville CB: Thrombosis of cerebral veins in infancy and childhood: review of literature and report of five cases. *J Pediatr* 8:600, 1936.
13. Einhaupl K, Bousser MG, de Bruijn SF, Ferro JM, Martinelli I, Masuhr F, Stam J: EFNS guideline on the treatment of cerebral venous and sinus thrombosis. *Eur J Neurol* 13:553-559, 2006.
14. Einhaupl KM, Villringer A, Meister W, Mehraein S, Garner C, Pellkofer M, Haberl RL, Pfister HW, Schmiedek P: Heparin treatment in sinus venous thrombosis. *Lancet* 338:597-600, 1991.
15. Erez N, Babuna C, Uner A: Low incidence of thromboembolic disease: an evaluation of obstetric and gynecologic patients in Istanbul. *Obstet Gynecol* 27: 833, 1966.
16. Ferro JM, Canhao P, Stam J, Bousser MG, Barinagarrementeria F: Prognosis of cerebral vein and dural sinus thrombosis: results of the International Study on Cerebral Vein and Dural Sinus Thrombosis (ISCVT). *Stroke* 35:664-670, 2004.
17. Higashida RT, Helmer E, Halbach VV, Hieshima GB: Direct thrombolytic therapy for superior sagittal sinus thrombosis. *AJNR Am J Neuroradiol* 10: S4-6, 1989.
18. Khan SN, Adeoye O, Abruzzo TA, Shutter LA, Ringer AJ: Intracranial dural sinus thrombosis: novel use of a mechanical thrombectomy catheter and review of management strategies. *Clin Med Res* 7:157-165, 2009.
19. Kulcsar Z, Marosfoi M, Berentei Z, Szikora I: Continuous thrombolysis and repeated thrombectomy with the Penumbra System in a child with hemorrhagic sinus thrombosis: technical note. *Acta Neurochir (Wien)*, 2009.
20. Masuhr F, Mehraein S, Einhaupl K: Cerebral venous and sinus thrombosis. *J Neurol* 251:11-23, 2004.
21. Newman CB, Pakbaz RS, Nguyen AD, Kerber CW: Endovascular treatment of extensive cerebral sinus thrombosis. *J Neurosurg* 110:442-445, 2009.
22. Paciaroni M, Palmerini F, Bogousslavsky J: Clinical presentations of cerebral vein and sinus thrombosis. *Front Neurol Neurosci* 23:77-88, 2008.
23. Scott JA, Pascuzzi RM, Hall PV, Becker GJ: Treatment of dural sinus thrombosis with local urokinase infusion. Case report. *J Neurosurg* 68:284-287, 1988.
24. Soleau SW, Schmidt R, Stevens S, Osborn A, MacDonald JD: Extensive experience with dural sinus thrombosis. *Neurosurgery* 52:534-544; discussion 542-534, 2003.
25. Stam J, Majoie CB, van Delden OM, van Lienden KP, Reekers JA: Endovascular thrombectomy and thrombolysis for severe cerebral sinus thrombosis: a prospective study. *Stroke* 39:1487-1490, 2008.
26. Towbin A: The syndrome of latent cerebral venous thrombosis. *Stroke* 4:419, 1973.
27. Zhang A, Collinson RL, Hurst RW, Weigle JB: Rheolytic thrombectomy for cerebral sinus thrombosis. *Neurocrit Care* 9:17-26, 2008.

*Conflict of interest statement: The authors declare that the article content was composed in the absence of any commercial or financial relationships that could be construed as a potential conflict of interest.*

*received 10 August 2010; accepted 04 February 2011*

*Citation: World Neurosurg. (2012) 77, 3/4:591.e15-591.e18. DOI: 10.1016/j.wneu.2011.02.020*

*Journal homepage: [www.WORLDNEUROSURGERY.org](http://www.WORLDNEUROSURGERY.org)*

*Available online: [www.sciencedirect.com](http://www.sciencedirect.com)*

*1878-8750/\$ - see front matter © 2012 Elsevier Inc. All rights reserved.*