

# Remifentanil use for cesarean section in a patient with intracranial re-ruptured arteriovenous malformation

Eiko Onishi · Akiko Kojima · Toshio Saishu · Shin Kurosawa

Received: 19 May 2010 / Accepted: 21 November 2011 / Published online: 11 December 2011  
© Japanese Society of Anesthesiologists 2011

**Abstract** We describe the successful administration of remifentanil as part of the anesthetic technique used for cesarean section performed under general anesthesia in a 24-year-old woman with intracranial re-hemorrhage caused by re-ruptured arteriovenous malformation. A low dose of remifentanil was useful to obtund the hypertensive response during induction and maintenance of anesthesia without neonatal respiratory depression.

**Keywords** Remifentanil · Re-ruptured arteriovenous malformation · Cesarean section

## Introduction

Intracranial hemorrhage from an arteriovenous malformation (AVM) in pregnancy is an uncommon but severe event for both the mother and fetus [1, 2]. The clinical occurrence of AVM during pregnancy is usually the result of hemorrhage following rupture [3]. The most important complication following the rupture of an AVM during pregnancy is subsequent re-hemorrhage [3]. Therefore, elective cesarean section is performed to avoid the hemodynamic changes associated with vaginal delivery.

Remifentanil is an esterase-metabolized opioid with an extremely short duration of action [4]. Recent reports have

suggested that remifentanil provides maternal hemodynamic stability and excellent neonatal outcomes [5–7]. However, few case reports in English describe the use of remifentanil for cesarean section in patients with intracranial hemorrhage.

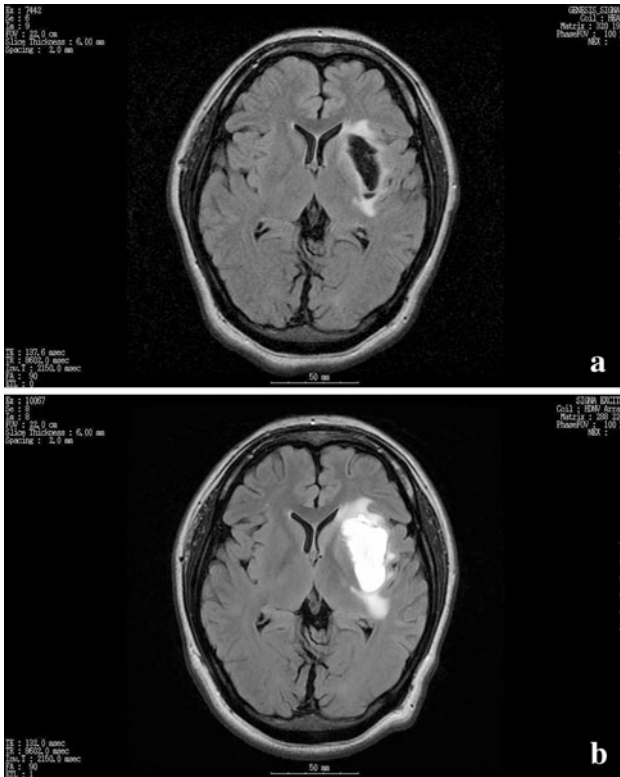
This report describes the use of remifentanil for cesarean section, performed under general anesthesia in a parturient following a re-ruptured AVM.

## Case report

A 24-year-old woman at 20 weeks' gestation presenting with right facial palsy and weakness of right-side extremities was admitted to our hospital. She had no history of hypertension or features that were suggestive of pre-eclampsia. She was conscious and alert. Her blood pressure was 127/57 mmHg. Her pulse rate was regular at 71 beats/min. Magnetic resonance imaging (MRI) of the brain revealed a left putamen hemorrhage caused by an AVM rupture (Fig. 1a). Although the MRI showed re-hemorrhage and cerebral edema at 22 weeks' gestation (Fig. 1b), she remained stable hemodynamically. Her neurological symptoms disappeared without medication. Following consultations among neurosurgeons, obstetricians, anesthesiologists, and pediatricians, the decision was made to perform an elective cesarean section to prevent the increase of intracranial pressure and hemodynamic instability that would occur during vaginal labor. At 37 weeks' gestation, a physical examination revealed her weight as 109 kg and height as 164 cm (body mass index 40.5). An airway examination showed adequate mouth opening with Mallampati score II and good neck movement. We chose general anesthesia, but not continuous spinal and epidural anesthesia (CSEA), for the following reasons: (1) because

E. Onishi · A. Kojima · T. Saishu  
Department of Anesthesiology, South Miyagi Medical Center,  
Ohgawara, Miyagi, Japan

S. Kurosawa (✉)  
Department of Anesthesiology and Intensive Care,  
Tohoku University Hospital, 1-1 Seiryō-cho, Aoba-ku,  
Sendai, Miyagi 980-8574, Japan  
e-mail: s-kurosawa@umin.ac.jp

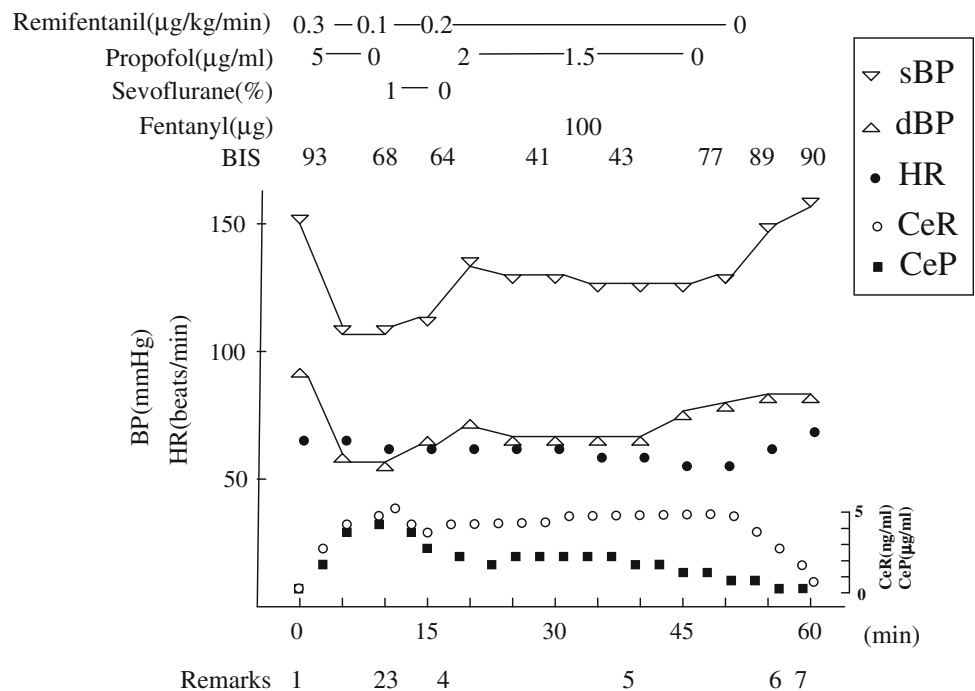


**Fig. 1** Fluid-attenuated inversion recovery (FLAIR) brain magnetic resonance image showing a left putamen hemorrhage caused by arteriovenous malformation (AVM) rupture at 20 weeks' gestation (a) and re-hemorrhage with edema caused by re-ruptured AVM at 22 weeks' gestation (b)

of the body mass index of 40.5, a longer time might have been required to perform CSEA, which would give the patient psychological and physiological stress and hemodynamic instability, and (2) intrathecal puncture by spinal anesthesia might influence the cerebrospinal pressure in this patient with an intracranial re-ruptured AVM. We regarded the prevention of hemodynamic changes in the mother during anesthesia as more important than the baby's respiratory condition, which would be managed by neonatal resuscitation and/or the use of naloxone. Therefore, we decided to use remifentanyl for general anesthesia.

At 38 weeks' gestation, elective cesarean section was performed under general anesthesia. In the operating room, the monitoring equipment included an electrocardiogram (ECG), non-invasive blood pressure, pulse oximetry, a bispectral (BIS) index monitor, and capnography. The BIS sensor was applied at the left side of her forehead to monitor a left putamen re-hemorrhage. Before the induction of anesthesia, the patient's blood pressure was 150/90 mmHg. Her heart rate was regular at 70 beats/min. Her BIS index was 93. For tracheal intubation, we selected a standard Macintosh laryngoscope, although a ProSeal (LMA, San Diego, CA) laryngeal mask and fiberoptic bronchoscopy were prepared for difficult intubation. In addition, we did not employ rapid sequence induction in this patient because there was a possibility that it might have increased her blood pressure. After denitrogenation, performed by the administration of oxygen at 6 L/min by face mask over 5 min, as presented in Fig. 2, remifentanyl

**Fig. 2** Timing of administrations of anesthetic agents; changes of blood pressure, heart rate, and bispectral index; and other information during anesthesia. HR heart rate, BP blood pressure, sBP systolic blood pressure, dBP diastolic blood pressure, BIS bispectral index, CeR effect-site concentration of remifentanyl, CeP effect-site concentration of propofol. 1 Induction of anesthesia, 2 tracheal intubation, 3 start of cesarean section, 4 delivery, 5 completion of cesarean section, 6 tracheal extubation, 7 transfer to intensive care unit



infusion was started, at 0.3 µg/kg/min (based on an estimated ideal body weight of 60 kg). At 1 min after the start of the remifentanyl infusion, anesthesia was induced using propofol target-controlled infusion (TCI) set at a blood concentration of 5 µg/ml. Cricoid pressure and manual ventilation were applied during anesthetic induction. Rocuronium bromide (75 mg) was administered 5 min after the start of the propofol infusion. She was intubated with a 7.5-mm cuffed tracheal tube at 10 and 9 min after starting remifentanyl and propofol, respectively. The patient showed a Cormack and Lehane grade of 2. Laryngoscopy and intubation were performed with no increase in blood pressure or heart rate. The effect-site concentration of remifentanyl simulated by Rugloop II® software (Demed Engineering, Temse, Belgium) was 5.10 ng/ml when intubation was done (Fig. 2). She was ventilated mechanically to an end-tidal CO<sub>2</sub> concentration of 30–35 mmHg. Anesthesia was maintained with oxygen in air (1:1), 1.0% sevoflurane, and 0.1–0.2 µg/kg/min remifentanyl infusion. Following tracheal intubation, the propofol TCI was stopped, and it was restarted after delivery, at 2 µg/ml.

A live 2800-g neonate was delivered 5 min subsequent to the skin incision. The neonate was born free of respiratory depression. Its Apgar score was 9 at 1 min and 10 at 5 min. The effect-site concentrations of remifentanyl and propofol simulated by Rugloop II® software were, respectively, 4.13 ng/ml and 2.04 µg/ml when the neonate was delivered (Fig. 2). Shortly before the end of surgery, 0.1 mg fentanyl was given to provide adequate analgesia before extubation. The anesthesia and surgery were completed uneventfully. The patient was extubated immediately after surgery; the pain was minimal. Postoperatively, she appeared stable hemodynamically without neurological disorder, and was given 15 mg pentazocine intramuscularly with subsequent oral nonsteroidal anti-inflammatory drugs. An interview conducted after surgery revealed the patient had had no incidence of awareness during the anesthesia. The patient and neonate were later discharged uneventfully with no medication.

## Discussion

Intracranial hemorrhage from an AVM in pregnancy is rare, but it can engender exceedingly high maternal and fetal morbidity and mortality [1, 2, 8]. The clinical occurrence of an AVM during pregnancy is usually the result of hemorrhage following rupture [3]. It remains controversial whether pregnancy is a risk factor for hemorrhage from an AVM. A recent study revealed that women with an AVM face a 3.5% risk of hemorrhage during pregnancy, which is similar to the hemorrhage rate for non-pregnant age-matched women [3]. Once hemorrhage

occurs, it accounts for 5–12% of all maternal deaths and accounts for a large percentage of maternal morbidity [3]. The management of a ruptured AVM during pregnancy should be based primarily on neurosurgical rather than obstetric considerations [9]. In most neurosurgical practices, patients with unruptured AVMs and those who are stable after hemorrhage of an AVM are allowed to reach term with elective postpartum excision of the AVMs [5]. Additionally, pregnant women with hemorrhage from an AVM appear to be at high risk for re-bleeding [10], which is the most important complication that occurs following rupture during pregnancy. Therefore, appropriate management should be based on a team approach involving obstetricians, neurosurgeons, and anesthesiologists. In our case, the neurosurgeons, following a discussion with obstetricians, anesthesiologists, and pediatricians, adopted conservative management for the patient with re-bleeding at 22 weeks' gestation.

The best mode of delivery in patients with untreated AVMs remains controversial. However, cesarean section tends to be selected to avoid the physical and psychological stress that occurs during vaginal delivery. The choice of the anesthetic technique for cesarean section in patients with AVMs is influenced by the need to maintain a stable cardiovascular system and is determined on a case-by-case basis [9]. In our patient, we inferred that perioperative hemodynamic stability was extremely important. Therefore, we selected general anesthesia to avoid the increase of intracranial pressure and the change of hemodynamics that might have occurred during regional anesthesia.

Remifentanyl seems to be suited for use in obstetrics because of its rapid metabolism by non-specific blood and tissue esterases in both the mother and neonate [5]. The use of remifentanyl for cesarean section under general anesthesia has been reported in various clinical situations [7, 11–15], including those related to cardiac disease [7, 11–13], liver disease [14], and neurologic disease [15]. Most of these reports noted that the maternal hemodynamic changes associated with laryngoscopy and surgical incision could be managed with remifentanyl without prolonged neonatal depression. However, remifentanyl crosses the placenta [4]. Consequently, brief neonatal respiratory depression has occurred in several cases [5, 16]. van de Velde et al. [17] reviewed the literature of remifentanyl for obstetric analgesia and anesthesia. They reported that remifentanyl produced mild neonatal respiratory depression in 67% of neonates and that 47% required brief mask ventilation. However, the neonatal respiratory depression was apparently transient. Spontaneous respiration was established rapidly by mask ventilation or naloxone [5, 6, 16, 17].

The safety of remifentanyl in neonatal outcomes has been investigated in several prospective studies to

determine the optimal technique for cesarean section under general anesthesia [5, 6, 18]. van de Velde et al. [6] evaluated the maternal and neonatal effects of a propofol/remifentanyl-based anesthesia technique in 10 patients undergoing cesarean section under general anesthesia. They used a bolus dose of 0.5  $\mu\text{g}/\text{kg}$  remifentanyl followed by an infusion of 0.2  $\mu\text{g}/\text{kg}/\text{min}$ . Although neonatal respiratory depression occurred in six babies and assisted mask ventilation was required briefly, recovery was rapid without naloxone or tracheal intubation. Ngan Kee et al. [5] compared the maternal and neonatal effects of a single intravenous bolus of 1  $\mu\text{g}/\text{kg}$  remifentanyl with those of saline control given at induction of general anesthesia for cesarean section. Their report noted that the respiratory conditions of two neonates in the remifentanyl group ( $n = 20$ ) were clinically depressed at birth and the neonates were given a single bolus of naloxone, although a bolus of remifentanyl attenuated the maternal stress of tracheal intubation. Therefore, the dose that Ngan Kee et al. used might have been excessive. However, they also stated that neonate respiratory depression could be minimized through avoidance of a bolus injection of remifentanyl. Further investigation is needed in relation to this point.

In addition, Draisci et al. [18] investigated the effect of low-dose remifentanyl infusion on maternal neuroendocrine response and neonatal wellbeing. In that study, 42 patients undergoing cesarean section under general anesthesia were randomized to receive either fentanyl after delivery ( $n = 21$ ) or remifentanyl bolus 0.5  $\mu\text{g}/\text{kg}$  before induction with subsequent continuous infusion at 0.15  $\mu\text{g}/\text{kg}/\text{min}$  until peritoneal incision, then restarted after delivery ( $n = 21$ ). They noted that remifentanyl partially reduced maternal stress hormone secretion related to surgery. However, Apgar scores were significantly lower in the remifentanyl group. Three neonates in the remifentanyl group required temporary tracheal intubation. The data reported by Draisci et al. show that remifentanyl can cause neonatal respiratory depression, even at low doses. Consequently, the remifentanyl dose is an important determinant of the degree of neonatal respiratory depression.

In our patient, hemodynamic stability during surgery was necessary because the patient had suffered intracranial re-hemorrhage caused by the re-ruptured AVM at 22 weeks' gestation. We chose low doses of remifentanyl (0.3 and 0.1–0.2  $\mu\text{g}/\text{kg}/\text{min}$ , respectively, during induction and maintenance of anesthesia) to attenuate the hemodynamic changes and to avoid neonatal respiratory depression. A report of a previous study noted that an effect-site concentration of remifentanyl of 5 ng/ml was necessary to blunt sympathetic responses to tracheal intubation [19]. In our patient, a dose of 0.3  $\mu\text{g}/\text{kg}/\text{min}$  of remifentanyl infusion for 10 min during induction led to a simulated effect-site concentration of 5.10 ng/ml, and intubation was

performed with no increase of blood pressure or heart rate. With the doses of remifentanyl we chose, the patient had stable hemodynamics during surgery without respiratory depression of the neonate. The simulated effect-site concentration of remifentanyl was 4.13 ng/ml when the neonate was delivered. No information is available about the rate constant of remifentanyl traveling from mother to fetus. However, it has been demonstrated that, in neonates, remifentanyl has pharmacokinetic properties similar to those in older children and adults [20]. Therefore, respiratory depression was expected to be transitory at this simulated effect-site concentration because of the rapid clearance of remifentanyl from the neonate. Indeed, in our patient, the neonate was delivered without respiratory depression, which seems to confirm these theoretical considerations.

We restarted propofol TCI at 2  $\mu\text{g}/\text{ml}$  after delivery, although it was reported that the effect-site concentration of propofol for recovery of consciousness ranged from 1.6 to 1.9  $\mu\text{g}/\text{ml}$  [21]. In addition, Ueyama et al. [22] have reported that pregnancy did not enhance the effect of anesthetic, although the minimum alveolar concentration (MAC) was lower in pregnant women. However, because our patient's BIS index was 93 in spite of her consciousness level before anesthetic induction, we considered that the higher-order brain functions of this patient might be slightly suppressed because of intracranial hemorrhage. Therefore, we chose a lower dose for the propofol infusion compared with doses reported before. This lower dose notwithstanding, the patient complained of no incidence of awareness during surgery.

In summary, we have described the use of remifentanyl during general anesthesia for cesarean section in a patient with a re-ruptured AVM. The use of remifentanyl attenuated maternal hemodynamic changes that occurred during surgery without neonatal respiratory depression. Remifentanyl is an attractive short-acting opioid that is useful for cesarean section in high-risk obstetric patients with intracranial vascular disorder necessitating hemodynamic stability.

## References

1. Hatsukari I, Nagasaka H, Tsuchiya M, Taguchi M. The anesthetic management for elective or emergent cesarean section in patients with intracranial arteriovenous malformation (in Japanese with English abstract). *Masui (Jpn J Anesthesiol)*. 2000;24:33–6.
2. Lao HC, Hseu SS, Huang YY, Yu YS, Tsai SK. Anesthetic management of intracranial hemorrhage from huge arteriovenous malformations in late pregnancy—a case report. *Acta Anaesthesiol Sin*. 2003;41:209–14.
3. Trivedi RA, Kirkpatrick PJ. Arteriovenous malformations of the cerebral circulation that rupture in pregnancy. *J Obstet Gynaecol*. 2003;23:484–9.

4. Kan RE, Hughes SC, Rosen MA, Kessin C, Preston PG, Lobo EP. Intravenous remifentanyl: placental transfer, maternal and neonatal effects. *Anesthesiology*. 1998;88:1467–74.
5. Ngan Kee WD, Khaw KS, Ma KC, Wong AS, Lee BB, Ng FF. Maternal and neonatal effects of remifentanyl at induction of general anesthesia for cesarean delivery: a randomized, double-blind, controlled trial. *Anesthesiology*. 2006;104:14–20.
6. van de Velde M, Teunkens A, Kuypers M, Dewinter T, Vandermeersch E. General anaesthesia with target controlled infusion of propofol for planned caesarean section: maternal and neonatal effects of a remifentanyl-based technique. *Int J Obstet Anesth*. 2004;13:153–8.
7. Orme RM, Grange CS, Ainsworth QP, Grebenik CR. General anaesthesia using remifentanyl for caesarean section in parturients with critical aortic stenosis: a series of four cases. *Int J Obstet Anesth*. 2004;13:183–7.
8. Yih PSW, Cheong KF. Anaesthesia for caesarean section in a patient with an intracranial arteriovenous malformation. *Anaesth Intensive Care*. 1999;27:66–8.
9. Sinha PK, Neema PK, Rathod RC. Anesthesia and intracranial arteriovenous malformation. *Neurol India*. 2004;52:163–70.
10. Friedlander RM. Clinical practice arteriovenous malformations of the brain. *N Engl J Med*. 2007;356:2704–12.
11. Macfarlane AJ, Moise S, Smith D. Caesarean section using total intravenous anaesthesia in a patient with Ebstein's anomaly complicated by supraventricular tachycardia. *Int J Obstet Anesth*. 2007;16:155–9.
12. Wadsworth R, Greer R, MacDonald JM, Vohra A. The use of remifentanyl during general anaesthesia for caesarean delivery in two patients with severe heart dysfunction. *Int J Obstet Anesth*. 2002;11:38–43.
13. Manullang TR, Chun K, Egan TD. The use of remifentanyl for Caesarean section in a parturient with recurrent aortic coarctation. *Can J Anaesth*. 2000;47:454–9.
14. Richa F, Yazigi A, Nasser E, Dagher C, Antakly MC. General anesthesia with remifentanyl for Cesarean section in a patient with HELLP syndrome. *Acta Anaesthesiol Scand*. 2005;49:418–20.
15. Imarengiaye C, Littleford J, Davies S, Thapar K, Kingdom J. Goal oriented general anesthesia for Cesarean section in a parturient with a large intracranial epidermoid cyst. *Can J Anaesth*. 2001;48:884–9.
16. Carvalho B, Mirikitani EJ, Lyell D, Evans DA, Druzin M, Riley ET. Neonatal chest wall rigidity following the use of remifentanyl for cesarean delivery in a patient with autoimmune hepatitis and thrombocytopenia. *Int J Obstet Anesth*. 2004;13:53–6.
17. van de Velde M. Remifentanyl for obstetric analgesia and anesthesia: a review of the literature. *Acta Anaesthesiol Belg*. 2005;56:45–9.
18. Draisci G, Valente A, Suppa E, Frassanito L, Pinto R, Meo F, De Sole P, Bossu E, Zanfini BA. Remifentanyl for cesarean section under general anesthesia: effects on maternal stress hormone secretion and neonatal well-being: a randomized trial. *Int J Obstet Anesth*. 2008;17:130–6.
19. Albertin A, Casati A, Federica L, Roberto V, Travaglini V, Bergonzi P, Torri G. The effect-site concentration of remifentanyl blunting cardiovascular responses to tracheal intubation and skin incision during bispectral index-guided propofol anesthesia. *Anesth Analg*. 2005;101:125–30.
20. Ross AK, Davis PJ, Dear DL, Ginsberg B, McGowan FX, Stiller RD, Henson LG, Huffman C, Muir KT. Pharmacokinetics of remifentanyl in anesthetized pediatric patients undergoing elective surgery or diagnostic procedures. *Anesth Analg*. 2001;93:1393–401.
21. Iwakiri H, Nagata O, Matsukawa T, Ozaki M, Sessler DI. Effect-site concentration of propofol for recovery of consciousness is virtually independent of fentanyl effect-site concentration. *Anesth Analg*. 2003;96:1651–5.
22. Ueyama H, Hagihira S, Takashina M, Nakae A, Mashimo T. Pregnancy does not enhance volatile anesthetic sensitivity on the brain: an electroencephalographic analysis study. *Anesthesiology*. 2010;113:557–84.