

“My sister’s hand is in my bed”: a case of somatoparaphrenia

Matteo Pugnaghi · Mariangela Molinari ·
Patrizia Panzetti · Paolo F. Nichelli ·
Giovanna Zamboni

Received: 24 November 2011 / Accepted: 28 November 2011 / Published online: 11 December 2011
© Springer-Verlag 2011

Somatoparaphrenia is a disorder of body representation, usually following right brain lesions, which consists in the delusional belief that the contralesional limbs belong to someone else [1, 2]. We report a new case of somatoparaphrenia in which the patient was remarkably aware of this symptom to the point that she wrote a short poem about it.

An 82-year-old woman, without previous history of neurologic or psychiatric disorders, presented with sudden headache and left side weakness. CT scan showed a right thalamic hematoma extending to the posterior arm of the internal capsule and lenticular nucleus, with surrounding edema spreading into the white matter of the right parietal lobe (Fig. 1a). On admission, she had a decreased level of alertness, mild dysarthria, right gaze preference, and complete left hemiplegia. Language was fluent with intact comprehension. Visual fields were preserved, but there was extinction on the left to simultaneous visual bilateral stimulation. She showed anosognosia for left-sided hemiplegia

and left spatial neglect. Past medical history included high blood pressure and hypo-thyroidism. Before admission, she had been independent and active, took complete care of her invalid husband, had several intellectual interests, including writing poetry and music lyrics.

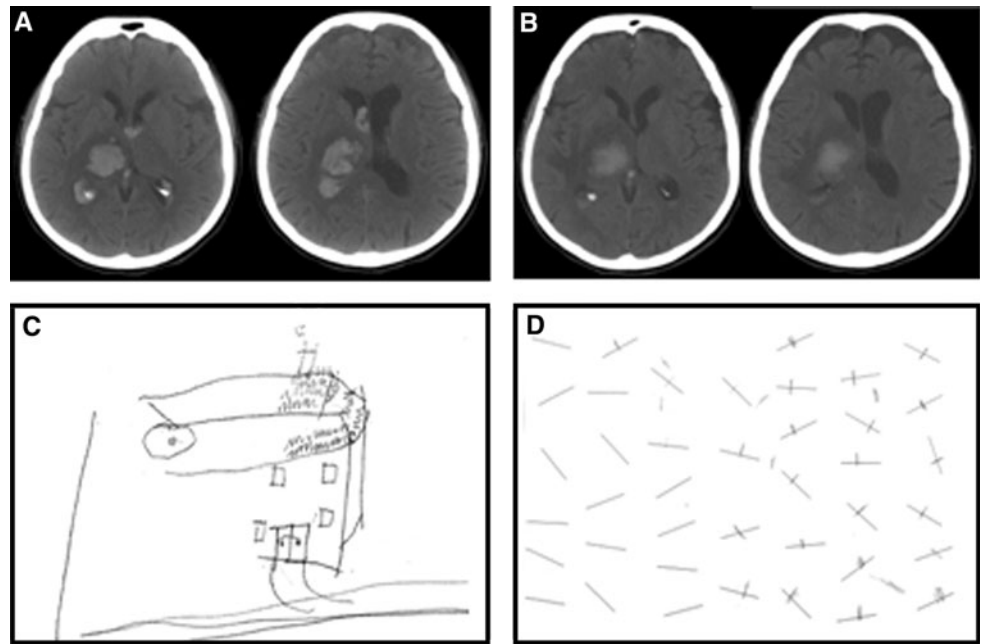
Two days after admission, when her general alertness had improved, she was still unaware of her left hemiplegia (Bisiach Score [3] of anosognosia was 3/3) and had a profound left spatial neglect, as shown by drawing, line bisection, and Albert’s cancellation test (Fig. 1c, d). She reported that her sister’s hand was in her bed and described it as hard, and unable to move. When shown her left arm, she said it was her sister’s arm. She was convinced that this had happened because the day before being admitted to the hospital she had visited her invalid sister (who indeed was in vegetative status) and had touched her unresponsive hand. She neither showed any emotional distress, nor personality or behavioral changes and was aware of the strangeness of the phenomenon. When asked to give a rational explanation, she admitted “strange things can happen to the subconscious mind”. In line with her pre-morbid cheerful personality, she humorously said once “I should ask my sister to pay for the parking of her hand”. Four days after admission, she reported that her sister’s hand was not in her bed anymore, but had been moved to her bed side-table by the nurses earlier in the morning (see video in supplementary material). She recognized the left hand in her bed as her own, but continued to say that her sister’s hand was somewhere in the room. The belief about her sister’s hand “coming to her” at nighttime persisted for another two nights, then resolved. Thereafter, she continued to report and recognize the “hands phenomenon” as real, to the point that she even wrote a short poem addressed to her “little hand” (Fig. 2). A follow-up CT scan performed 10 days after admission and following the

Electronic supplementary material The online version of this article (doi:10.1007/s10072-011-0874-z) contains supplementary material, which is available to authorized users.

M. Pugnaghi · M. Molinari · P. Panzetti · P. F. Nichelli
Clinica Neurologica, Dipartimento di Neuroscienze,
Università di Modena e Reggio Emilia, Nuovo Ospedale C.
Sant’Agostino e Estense, Baggiovara, Modena, Italy

G. Zamboni (✉)
Oxford Project to Investigate Memory and Ageing (OPTIMA) &
Oxford Centre for fMRI of the Brain (FMRIB),
University of Oxford, John Radcliffe Hospital,
Oxford OX3 9DU, UK
e-mail: giovanna.zamboni@ndm.ox.ac.uk

Fig. 1 CT scan of the patient showing the intra-cerebral hematoma in two different axial planes at the time of hospital admission (a) and 10 days after the admission, when the somatoparaphrenic belief was no longer present (b). Neuropsychological assessment showed left spatial neglect when the patient was asked to draw a house (c), or to mark/cancel all the lines in A4 paper- Albert's cancellation test (d)



Io cerco le mie manine
 le cerco, me non le trovo
 chissà dove sarò
 papà papà papà papà
 Sarò con altre mani
 a giocarsi una partita
 me vinci il mio domo
 ni, perché tu appartieni
 a me, fere fere fere fere
 Mai tutti ti aspettiamo
 da noi sarai festonate
 non fare le brichine
 ritorno di mie manine
 porte a noi felicitè
 Papà papà papà papà

◀ **Fig. 2** Poem written by the patient (in her own handwriting) to the hand involved by the somatoparaphrenic delusion. Translated from Italian: “I am looking for my little hand, which I lose every morning, I am looking for it and do not find it, where will it be, *para papa?* It will be with other hands to play their game. Yes, play on your own tomorrow, but your life belongs to me *pere pepe pere pepe* Come back, I wait for you you know the way little hand... unreadable text”

Several features of the present case, including the association with other neuropsychological symptoms (spatial and personal neglect) have been described in previously reported cases of somatoparaphrenia [2, 4–6]. The anatomical localization is also consistent with previous reported cases and with the hypothesis that somatoparaphrenia may be caused by a disconnection between parietal neocortex and subcortical structures [4, 6].

Instead, some other features of this case have not been previously reported, and we believe that they may add on the current understanding of mechanisms underlying body ownership and self-consciousness. First, the somatoparaphrenic belief followed a specific temporal gradient, with an intermediate phase preceding the complete resolution in which the sister's hand “would come” only at nighttime. Second, the left hand was attributed to someone who indeed was paralyzed (patient's sister), with whom the patient has been recently in spatial (and emotional) proximity. This may well have been a coincidence, but might also suggest speculating that the somatoparaphrenic belief may have been somehow evoked by autobiographical experiences of weakness or paralysis. It also suggests that the patient was somehow aware of the physical features of the left hand (stiffness and weakness), supporting further the notion that somatoparaphrenia is not primarily due to

resolution of the somatoparaphrenia showed an unchanged extent of hemorrhage in the right thalamus and internal capsule (Fig. 1b).

an impairment of somatosensory representation [4]. Finally, the level of insight and curiosity that our patient had regarding her own somatoparaphrenic belief was remarkable. She appeared completely aware of the strangeness of this symptom and interested in pursuing possible explanations from doctors. Nevertheless, she persisted in her belief to the point that she even wrote a short poem addressed to her “lost” hand. We believe that this is the first reported case in which the somatoparaphrenic belief reached the level of symbolic representation (in form of a poem) by the patient experiencing it. As such, it can also be interpreted as a case of “meta-somatoparaphrenia” or “awareness of body-unawareness”, as far as artistic representation can be considered as a form of knowledge and awareness of the represented phenomena. From this perspective, we believe that this case offers an important window into current understanding of the mechanisms of embodiment and self-consciousness.

Acknowledgments This study was supported by Italian Ministry of University and Research (MIUR) (M.P., M.A.M., P.P. and P.N.) and Oxford NIHR Biomedical Research Centre (G.Z.)

Conflict of interest The authors report no conflicts of interest.

References

1. Gerstmann J (1942) Problem of imperception of disease and of impaired body territories with organic lesions: relation to body scheme and its disorders. *Arch Neurol Psychiatr* 48:890–913
2. Vallar G, Ronchi R (2009) Somatoparaphrenia: a body delusion. a review of the neuropsychological literature. *Exp Brain Res* 192: 533–551
3. Bisiach E, Vallar G, Perani D, Papagno C, Berti A (1986) Unawareness of disease following lesions of the right hemisphere: anosognosia for hemiplegia and anosognosia for hemianopia. *Neuropsychologia* 24:471–482
4. Bottini G, Bisiach E, Sterzi R, Vallar G (2002) Feeling touches in someone else’s hand. *Neuroreport* 13:249–252
5. Halligan PW, Marshall JC, Wade DT (1995) Unilateral somatoparaphrenia after right hemisphere stroke: a case description. *Cortex* 31:173–182
6. Gandola, Invernizzi, Sedda, Ferrè, Sterzi, Sberna, Paulesu and Bottini (2011) An anatomical account of somatoparaphrenia. *Cortex*. doi:[10.1016/j.cortex.2011.06.012](https://doi.org/10.1016/j.cortex.2011.06.012)