

## A Case of Posterior Cerebral Artery Dissection Presenting with Migraine-Like Headache and Visual Field Defect: Usefulness of Fast Imaging Employing Steady-State Acquisition (FIESTA) for Diagnosis

Koichi Haraguchi, MD, PhD, Kentaro Toyama, MD, PhD, Takeo Ito, MD, Masahiro Hasunuma, MD, and Yasuo Sakamoto, MD

---

We report a 34-year-old woman with sudden onset of unilateral migraine-like headache and right homonymous hemianopsia. Fast imaging employing steady-state acquisition (FIESTA) of the posterior cerebral artery captured an intimal flap and a pseudolumen, leading to a diagnosis of posterior cerebral artery dissection. This case was considered a spontaneous posterior cerebral artery dissection causing migraine-like headache. The treatment of migraine-like headache hinges on correct diagnosis. In this case, FIESTA was very useful in diagnosing an intracranial artery dissection. **Key Words:** Cerebral artery dissection—magnetic resonance imaging—fast imaging employing steady-state acquisition.

© 2012 by National Stroke Association

---

Cerebral artery dissection is diagnosed on the basis of the vascular morphology, which is evaluated by diagnostic angiography, magnetic resonance angiography (MRA), and 3-dimensional computed tomography angiography. The most important evidence of dissection is the presence of an intimal flap and a pseudolumen in the affected artery. However, diagnosis of dissection of a posterior cerebral artery (PCA) is very rare and is made difficult by the very narrow artery. We report a case of PCA dissection that presented with sudden-onset headache and occipital lobe ischemia. Fast imaging employing steady-state acquisition (FIESTA) magnetic resonance imaging (MRI) can

reveal the intimal flap and the pseudolumen in the PCA and are useful in diagnosing cerebral artery dissection.

### Case Report

A 34-year-old woman was admitted to our hospital with sudden onset of unilateral migraine-like headache and deficiency in her right visual field. On admission, her consciousness was clear, and she had no neurologic symptoms except right homonymous hemianopsia. She had no history of migraine and was not taking any oral contraceptives or pills. An electrocardiogram demonstrated normal sinus rhythm. Hematologic evaluation revealed no remarkable abnormal findings.

Diffusion-weighted MRI (DWI) obtained 90 minutes after onset revealed an abnormal hyperintense lesion in the left occipital lobe, and MRA showed left posterior cerebral artery (PCA) occlusion (Figs 1 A and C). The patient was treated with edaravon (3-methyl-1-phenyl-2-pyrazolin-5-one), which has been developed as a neuroprotective agent and approved for treatment of acute cerebral infarction in Japan. DWI performed after 8 hours of admission showed that the hyperintense lesion was

---

From the Department of Neurosurgery, Hakodate Shintoshu Hospital, Hakodate, Japan.

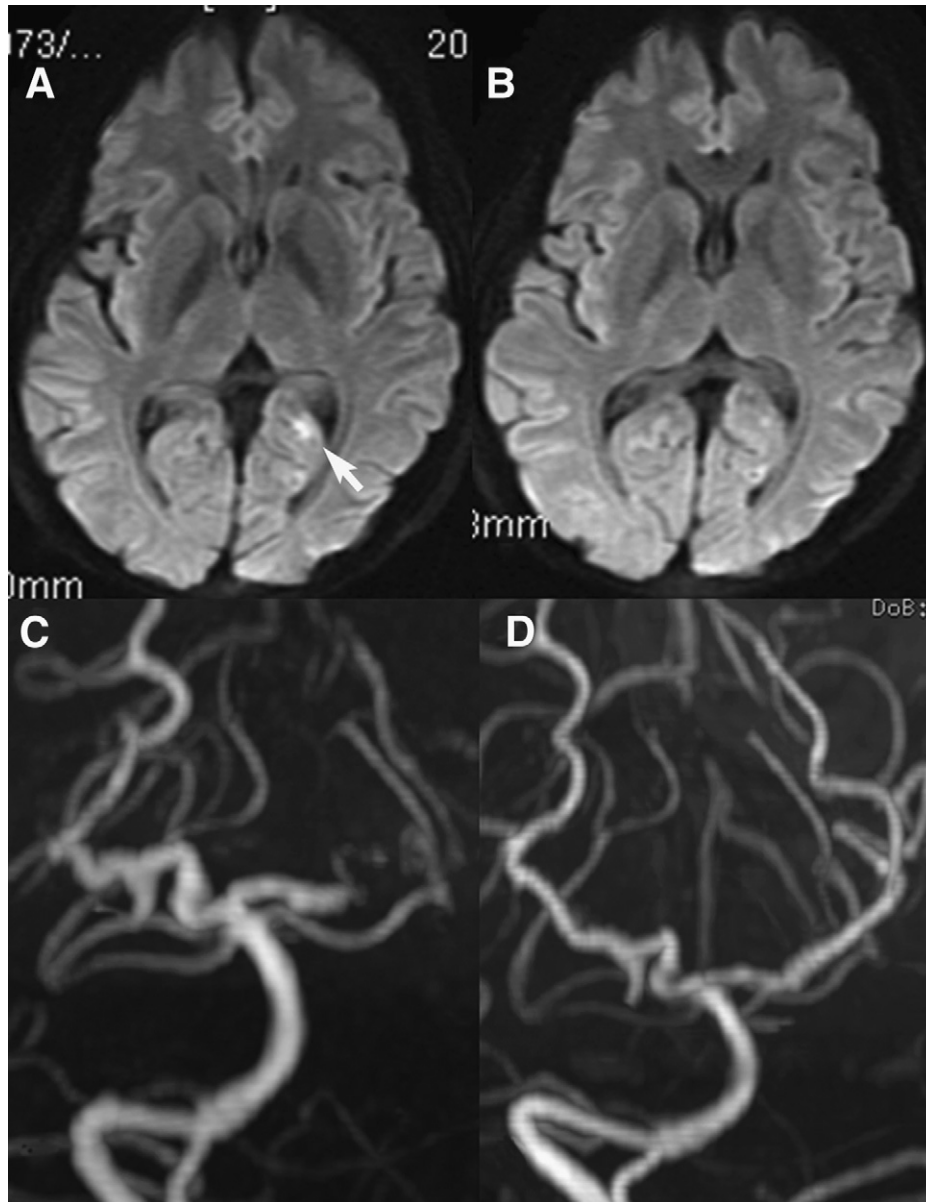
Received January 25, 2011; revision received May 17, 2011; accepted July 14, 2011.

Address correspondence to Koichi Haraguchi, MD, PhD, Department of Neurosurgery, Hakodate Shintoshu Hospital, 331-1, Ishikawa-cho, Hakodate, Hokkaido 041-0802, Japan. E-mail: haraguchi@yushinkai.jp.

1052-3057/\$ - see front matter

© 2012 by National Stroke Association

doi:10.1016/j.jstrokecerebrovasdis.2011.07.012

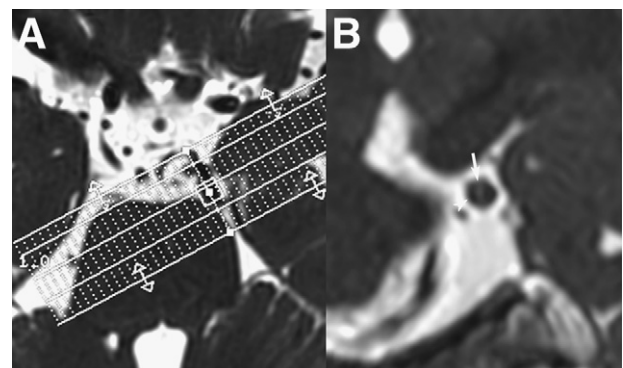


**Figure 1.** (A) DWI image obtained at presentation showing a hyperintense lesion in the left occipital lobe (arrow). (B) DWI image obtained the next day showing a reduction of the hyperintense lesion. (C) MRA showing left PCA occlusion. (D) MRA done the next day of the left PCA showing the pearl and string sign.

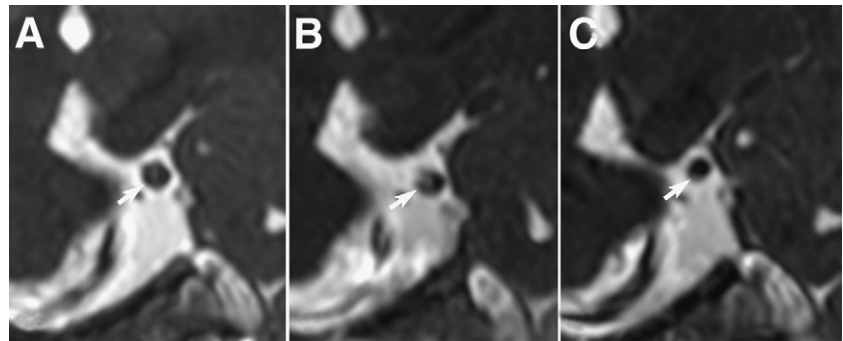
reduced and localized to the subcortical white matter of the left occipital lobe (Fig 1B). MRA demonstrated a recanalization of left PCA (Fig 1D).

At a subsequent examination, we performed FIESTA using a 3.0-T scanner system (Signa EXCITE HD; GE Healthcare, Buckinghamshire, UK) with the following parameters: recovery time, 4.8 ms; echo time, 2.4 ms; flip angle, 40°; field of view, 16 cm; matrix, 256 × 256; thickness, 0.8 mm; and 1 excitation. The FIESTA performed perpendicular to the PCA revealed an intimal flap and a pseudolumen in the PCA (Fig 2), and we were able to diagnose dissection of PCA on the basis of these findings. Homonymous hemianopsia improved spontaneously, and the patient was discharged with no neurologic deficit.

In the follow-up FIESTA images obtained at 2 and 4 months after discharge, the PCA was patent and the pseudolumen was gradually smaller (Fig 3).



**Figure 2.** (A) FIESTA image obtained perpendicular to the PCA during the second examination. (B) Image showing an intimal flap (arrow) and a pseudolumen (arrowhead).



**Figure 3.** Follow up FIESTA images. (A) On admission. (B) At 2-month follow-up. (C) At 4-month follow-up. The pseudolumen gradually reduced in size over time (arrow).

## Discussion

Cerebral arterial dissection is a common cause of juvenile cerebral infarction and is a known cause of sudden-onset headache.<sup>1,2</sup> Most cases of dissection occur in the vertebral and internal carotid arteries;<sup>3,4</sup> however, dissection of a PCA is extremely rare.<sup>5</sup> Clinical manifestations are cerebral infarction or subarachnoid hemorrhage. Common angiographic findings include the “string” or “pearl-and-string” sign, fusiform dilatation, and occlusion of the affected artery. Most cases of ischemic onset are uneventful with conservative therapy. In some cases, proximal ligation or trapping is performed in the acute stage for subarachnoid hemorrhage or in the chronic stage for ischemia.<sup>6-11</sup>

Cerebral artery dissection is diagnosed on the basis of vascular morphological irregularities such as those typical string sign or pearl and string sign on images obtained by MRA, 3-dimensional computed tomography angiography, or diagnostic angiography.<sup>4</sup> MRA is not an invasive examination, and T1-weighted MRI is a sensitive tool for detecting intramural hematoma, which is useful for diagnosis.<sup>4</sup> Regardless of the modality used, however, identification of morphological changes or intramural hematomas in intracranial small arteries, such as the PCA, is difficult.

The most important and reliable indicator for a more definite diagnosis is the presence of an intimal flap and a pseudolumen in the affected artery.<sup>4</sup> Because of its very high resolution, FIESTA is capable of visualizing the tiny structures surrounded by fluid, such as cranial nerves or arteries. It also apparently can visualize an intimal flap surrounded by blood, as observed in the present case.<sup>12</sup>

In our patient, the FIESTA image clearly demonstrated an intimal flap and a pseudolumen. Interestingly, on DWI, the hyperintense lesion reduced and disappeared on the third day. We speculate that the PCA became occluded very quickly and did not lead to cerebral infarction. In follow-up examinations, FIESTA demonstrated reduction of the pseudolumen.

How frequently this clinical and pathological combination is missed in patients with migraine is unknown. Physicians should consider cerebral artery dissection as a cause of sudden-onset migraine-like headaches and cerebral infarction in younger adults.

To the best of our knowledge, there is no previously published report of the utility of FIESTA in diagnosing arterial dissection. We believe that this technique is highly useful for making the diagnosis of intracranial dissection of small arteries, such as PCA. However, this is a case report of only 1 patient, and further studies in a large sample of patients are needed to confirm the diagnostic value of this sequence.

## References

1. Brandt T, Steinke W, Thie A, et al. Posterior cerebral artery infarcts: Clinical features, infarct topography, causes and outcome. Multicenter results and a review of the literature. *Cerebrovasc Dis* 2000;10:170-182.
2. Yamaura A, Watanabe Y, Saeki N. Dissecting aneurysms of intracranial vertebral artery. *J Neurosurg* 1990;72:183-188.
3. Ohkuma H, Suzuki S, Ogane K. Dissecting aneurysms of intracranial carotid circulation. *Stroke* 2002;33:941-947.
4. Yoshimoto Y, Wakai S. Unruptured intracranial vertebral artery dissection: Clinical course and serial radiographic imagings. *Stroke* 1997;28:370-374.
5. Maillou A, Diaz P, Morales F. Dissecting aneurysm of the posterior cerebral artery: Spontaneous resolution. *Neurosurgery* 1991;29:291-294.
6. Horie N, Kawahara I, Kitagawa N, et al. Recanalization after endovascular occlusion of a dissecting aneurysm of the posterior cerebral artery: A case report and review of the literature. *Clin Neurol Neurosurg* 2008;110:411-415.
7. Inoue T, Nishimura S, Hayashi N, et al. Postpartum dissecting aneurysm of the posterior cerebral artery. *J Clin Neurosci* 2007;14:576-581.
8. Kawaguchi S, Sakaki T, Tsunoda S, et al. Management of dissecting aneurysms of the posterior circulation. *Acta Neurochir (Wien)* 1994;131:26-31.
9. Lazinski D, Willinsky RA, Terbrugge K, et al. Dissecting aneurysms of the posterior cerebral artery: Angioarchitecture and a review of the literature. *Neuroradiology* 2000;42:128-133.
10. Sasaki O, Koizumi T, Ito Y, et al. Dissecting aneurysm of the posterior cerebral artery treated with proximal ligation. *Surg Neurol* 1992;37:394-401.
11. Vilela P, Goulão A. Paediatric dissecting posterior cerebral aneurysms: Report of two cases and review of the literature. *Neuroradiology* 2006;48:541-548.
12. Davagnanam I, Chavda SV. Identification of the normal jugular foramen and lower cranial nerve anatomy: Contrast-enhanced 3D fast imaging employing steady-state acquisition MR imaging. *AJNR Am J Neuroradiol* 2008;29:574-576.