

# CASE REPORT

## Modulation of Event-related Desynchronization during Motor Imagery with Transcranial Direct Current Stimulation in a Patient with Severe Hemiparetic Stroke: A Case Report

Takamichi Tohyama,<sup>1</sup> Toshiyuki Fujiwara,<sup>1</sup> Jun Matsumoto,<sup>2</sup> Kaoru Honaga,<sup>1</sup> Junichi Ushiba,<sup>3</sup> Tetsuya Tsuji,<sup>1</sup> Kimitaka Hase<sup>1</sup> and Meigen Liu<sup>1</sup>

<sup>1</sup>*Department of Rehabilitation Medicine, School of Medicine, Keio University, Tokyo, Japan*

<sup>2</sup>*School of Fundamental Science and Technology, Graduate School of Keio University, Kanagawa, Japan*

<sup>3</sup>*Department of Biosciences and Informatics, Faculty of Science and Technology, Keio University, Kanagawa, Japan*

(Received for publication on December 8, 2010)

(Revised for publication on April 25, 2011)

(Accepted for publication on May 19, 2011)

Recently, surface electroencephalogram (EEG)-based brain-machine interfaces (BMI) have been used for people with disabilities. As a BMI signal source, event-related desynchronization of alpha-band EEG (8–13 Hz) during motor imagery (mu ERD), which is interpreted as desynchronized activities of the activated neurons, is commonly used. However, it is often difficult for patients with severe hemiparesis to produce mu ERD of sufficient strength to activate BMI. Therefore, whether it is possible to modulate mu ERD during motor imagery with anodal transcranial direct-current stimulation (tDCS) was assessed in a severe left hemiparetic stroke patient. EEG was recorded over the primary motor cortex (M1), and mu ERD during finger flexion imagery was measured before and after a 5-day course of tDCS applied to M1. The ERD recorded over the affected M1 increased significantly after tDCS intervention. Anodal tDCS may increase motor cortex excitability and potentiate ERD during motor imagery in patients with severe hemiparetic stroke. (Keio J Med 60 (4) : 114–118, December 2011)

**Keywords:** cortical excitability, noninvasive brain stimulation, electroencephalogram, brain-machine interface

### Introduction

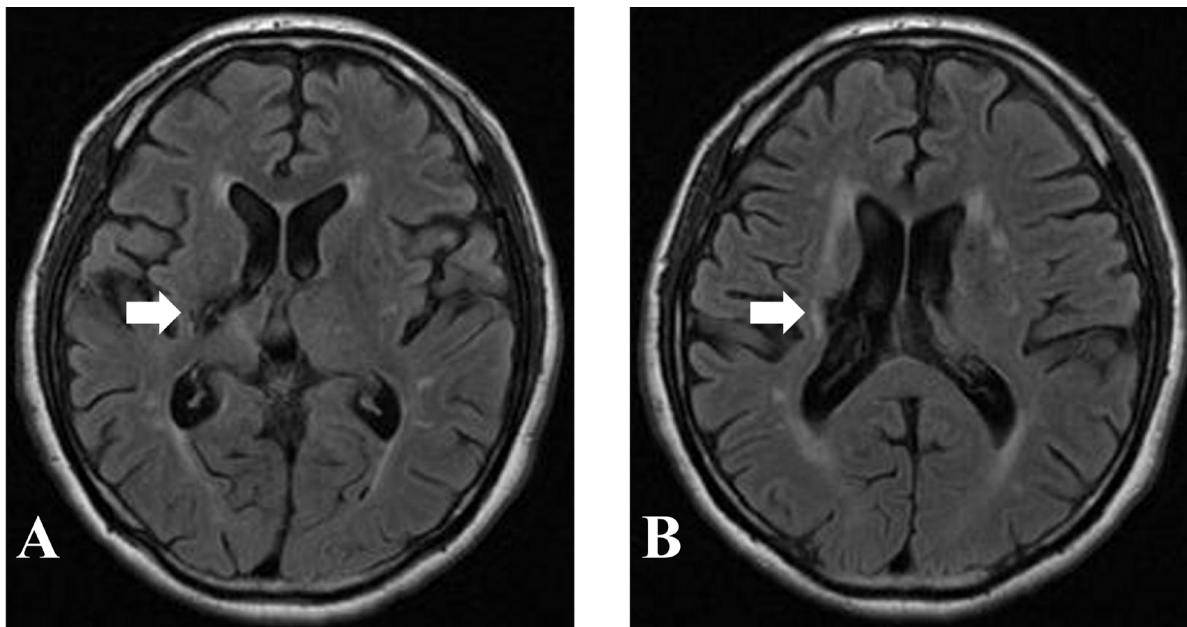
Recently, the usefulness of a brain-machine interface (BMI) that controls external devices based on neural activity of the brain during motor intention and imagery has been reported for people with disabilities.<sup>1</sup> It has been suggested that BMI might be used to restore severely paretic limbs, and its application to rehabilitation is attracting a great deal of attention.<sup>2,3</sup>

The event-related desynchronization of the alpha-band (8–13 Hz) electroencephalogram (EEG) (mu ERD) is interpreted as the desynchronized activities of the activated neurons appearing during motor imagery. It is well rec-

ognized that motor imagery induces an ERD of 8–13 Hz over the motor cortex.<sup>4</sup> This mu ERD, which reflects motor preparation and appears during motor imagery, has been used with BMI to control external devices such as robotic hands and motor-driven orthoses.<sup>5</sup>

It is known that the magnitude of ERD varies among individuals, which means that not all subjects can use ERD-based BMI. In people with brain injuries, it is known that measurement of stable ERD is often difficult;<sup>6</sup> therefore, use of BMI in patients with severe motor disabilities has been limited.

Cortical excitability can be modulated with transcranial direct-current stimulation (tDCS). Anodal tDCS in-



**Fig. 1** MRI (FLAIR) images of the patient.

Each of the arrows shows low-intensity areas in the right posterior limb of the internal capsule (A) and corona radiata (B).

creases excitability of the motor cortex, whereas cathodal tDCS decreases it.<sup>7</sup> If application of tDCS could enhance cortical signals such as mu ERD, it would be beneficial for the use of BMI in persons with severe motor paralysis due to central nervous system injury. In this case report, mu ERD induced by motor imagery was assessed in a patient with severe left hemiparetic stroke, and its modulation with anodal tDCS was examined.

### Case Description

The patient was a 61-year-old man who had suffered left hemiparesis secondary to thalamic hemorrhage due to long-lasting hypertension 3 years earlier. He was able to walk independently with a single cane and an ankle-foot orthosis. He could raise his paretic hand up to nipple height from the knee, and he could flex his paretic fingers but not extend them. His Fugl-Meyer upper extremity motor score was 17. Light touch and position sensation were severely disturbed. The modified Ashworth scale (MAS)<sup>8</sup> score for the finger flexor muscles was 2. He could not use his left upper extremity practically in daily life, except for placing it on a sheet of paper on a desk to hold it in place. He did not exhibit apraxia, aphasia, agnosia, or memory deficit. Fluid-attenuated inversion recovery (FLAIR) magnetic resonance imaging (MRI) showed low-intensity areas in the right posterior limb of the internal capsule and corona radiata (**Fig. 1**).

The protocol of tDCS intervention was approved by the ethical committee of Keio University School of Medi-

cine, and the patient gave his written informed consent to participate in the study. The patient received anodal tDCS for 5 days. The tDCS was applied for 10 min through rectangular, saline-soaked, sponge electrodes ( $50 \times 70 \text{ mm}^2$ ) with a battery-driven stimulator (CX-6650, Rolf Schneider Electronics, Gleichen, Germany) while the patient sat on a chair with his hands placed over the armrests. The stimulation intensity was set at 1 mA. The anodal electrode was placed on C4 according to the international 10–20 system for placement of EEG electrodes. The cathodal electrode was placed on the contralateral supra-orbital area.

### Assessment of ERD

One day before and 1 day after the 5-day tDCS session, mu ERD with finger flexion imagery was measured. To assess the long-term effect of the 5-day tDCS session, we measured mu ERD 1 year later. The patient sat on a chair with his hands placed over the armrests, his shoulders flexed to  $10^\circ$  and elbows flexed to  $90^\circ$ . The patient was asked to imagine flexion of his paretic finger for 5 s initiated with a visual cue on a computer monitor. EEG signals were recorded with 20 Ag/AgCl disc electrodes (1 cm in diameter) with binaural references according to the international 10–20 system of electrodes. To determine the electrode pair showing the largest ERD, all adjacent pairs of bipolar derivations of EEG were used to check for the presence of mu ERD following motor imagery. The selected bipolar EEG showing the largest ERD

**Table 1** Change of mu event-related desynchronization (ERD) value (%) in the affected and unaffected hemispheres during motor imagery

	Motor imagery of paretic fingers		Motor imagery of non-paretic fingers	
	Before (T1)	After (T2)	Before (T1)	After (T2)
Affected hemisphere ERD (SE)	4.1(8.8)	25.1(6.2)**	-4.6 (11.5)	-2.8 (7.2)
Unaffected hemisphere ERD (SE)	32.1(10.1)	13.0 (6.0)*	26.6 (6.5)	19.6 (7.0)

tDCS, transcranial direct-current stimulation; SE, standard error.

Mann-Whitney U test: \*\* $p=0.001$ , \* $p<0.05$  compared with before (T1) value.

was used for further analysis. A surface electromyogram (EMG) was used to check that no activity of bilateral first dorsal interosseous muscles (FDI) appeared during motor imagery.

Event-related trials of 5 s during motor imagery were selected for off-line data processing. All trials were visually assessed, and trials with artifacts (resulting from eye movement), as well as those with increased EMG activity of the right FDI, were excluded. All trials were segmented into successive 1-s windows with 100 overlapping samples, and Fourier transformation with the Hanning window was applied to each segment. The power spectrum densities of each segment were estimated over the trials by Welch's averaged periodogram method.<sup>9</sup>

The mu ERD was expressed as the percentage power decrease in relation to a 1-s reference interval before the patient was notified to be "ready." The ERD was calculated for each time (resolution of 0.1 s) and frequency (resolution of 0.98 Hz) according to Equation (1):

$$\text{ERD}(f, t) = [(R(f) - A(f, t)) / R(f)] \times 100 (\%) \quad (1)$$

Where A is the power spectrum density of the EEG at a certain frequency  $f$  [Hz] and time  $t$  [s] after the imagery task was started, and R is the power spectrum at the same frequency  $f$  [Hz] of the baseline period (a 1-s interval before "Ready" was displayed). The largest power decrease during motor imagery in the alpha band (8–13 Hz) was selected as the value of mu ERD. Before tDCS application, the values of mu ERD were compared in all adjacent pairs of bipolar derivations of the EEG to determine the electrode pair showing the largest value of mu ERD.<sup>10</sup>

## Results

**Table 1** shows the mu ERD changes in both hemispheres during motor imagery of the paretic and non-paretic fingers before (T1) and after (T2) a 5-day tDCS session. Anodal tDCS applied to the affected hemisphere for 5 days increased mu ERD induced by paretic hand imagery in the affected hemisphere and decreased it in the unaffected hemisphere.

One year after the 5-day tDCS session, the mu ERD during motor imagery of the paretic finger flexion was  $25.1 \pm 3.8\%$  in the affected hemisphere and  $26.4 \pm 5.1\%$  in the unaffected hemisphere. Clinically, the MAS score for

the finger flexor muscles decreased from 2 to 1+ and the Fugl-Meyer upper extremity motor score increased from 17 to 20. The patient used his paretic upper extremity for holding a bag, in addition to pressing a sheet of paper on the desk in his daily life. The MAS score, Fugl-Meyer score and his paretic upper extremity function in his daily life had been maintained for 1 year after the 5-day tDCS treatment. The patient did not experience any adverse side effects during the course of the study.

## Discussion

This is the first report demonstrating that anodal tDCS applied to the affected hemisphere can increase mu ERD induced with motor imagery of paretic finger movement. At baseline, mu ERD induced with motor imagery of paretic fingers was low in the affected hemisphere, while it was high in the unaffected hemisphere. We thought it difficult for our patient to imagine paretic finger movement because he had suffered from severe hemiparetic stroke more than 3 years before the time of the study. Furthermore, it has been reported that disuse of the upper extremity reduces cortical excitability during motor imagery.<sup>11</sup>

Anodal tDCS increases motor cortex excitability. Previous studies suggest that cortical excitability changes induced with tDCS are due to modifications of membrane polarization and the synaptic mechanism.<sup>7,12</sup> The ERD mechanism is attributed to a decrease in the synchrony of the underlying neuronal population.<sup>13</sup> Therefore, ERD changes after tDCS may be explained by changes in the oscillatory behavior of cortical neurons, such as membrane potentials in the primary motor area, and the probability of neurons firing according to input signals in response to motor imagery. Matsumoto *et al.* showed that mu ERD significantly increased after anodal tDCS, whereas it significantly decreased after cathodal tDCS in healthy subjects.<sup>14</sup> There was a significant correlation between mu ERD and motor cortex excitability. The ERD is suggested to be generated by the neural interconnection of the feedback loop involving the thalamo-cortical or cortico-cortical loop.<sup>13,15</sup> tDCS seems to activate the intermediate neurons projecting to pyramidal tract neurons (PTN) in the cortex.<sup>16</sup> Therefore it is suggested that mu ERD could be modulated by a change in excitabil-

ity of the intermediate neurons projecting to the PTNs. Increased cortical excitability results in more activated and desynchronized neurons, which results in an ERD increase.

It has been reported that the after effects of tDCS for 10 min at 1 mA continue for 10 min to 1 h.<sup>7,12</sup> Reis et al. showed the existence of a consolidation mechanism susceptible to anodal tDCS.<sup>17</sup> Long-term effects induced by tDCS may include the build up of new synapses, with the mechanism of long-term potentiation and long-term depression critically involved. The glutamatergic system, in particular NMDA receptors,<sup>18</sup> seems to be necessary for induction and maintenance of neuroplastic after-effect excitability enhancement by tDCS.<sup>19</sup> It was supposed, therefore, that 5 days of tDCS intervention resulted in a significant increase of ERD in the affected hemisphere.

We found that anodal tDCS applied to the affected hemisphere for 5 days decreased the ERD in the unaffected hemisphere. Increased motor cortex excitability in the affected hemisphere could increase the inter-hemispheric inhibition from the affected to the unaffected hemisphere and reduce the compensatory activity of the unaffected hemisphere.<sup>20</sup>

Besides modulation of cortical activity, repeated application of tDCS reduced spasticity in paretic fingers in this case. Recently, Roche et al. showed that anodal tDCS increased disynaptic reciprocal inhibition.<sup>21</sup> This might explain the observed decrease in spasticity with tDCS. It was supposed that increased motor cortex excitability and decreased spasticity might induce improvement of upper extremity motor function. The improvement of motor function allowed the patient to use his paretic upper extremity more than before. It has been easier for the patient to imagine paretic finger movement than before. That could be one of the reasons why the change of ERD in the affected hemisphere during imagery has been maintained for 1 year after the 5-day tDCS session.

In this patient with a thalamic lesion, mu ERD with motor imagery was increased after anodal tDCS. Cicinelli et al. suggested that the changes in imagery-induced cortical excitability were not different in respect to the location of the stroke lesion in patients whose primary motor cortex was spared.<sup>22</sup> However, further study should address whether stroke lesion location may influence the ERD change with motor imagery.

If application of tDCS can enhance cortical signals such as mu ERD, it would be beneficial for the use of BMI in patients with severe motor disabilities due to central nervous system injury. However, this present study is a case report, and further larger-scale and more systematic studies are needed to test the usefulness of this approach.

### Acknowledgments

This study was partially supported by the Strategic

Research Program for Brain Sciences (SRPBS) and a Grant-in Aid for Scientific Research (C) (20500465) from the Ministry of Education, Culture, Sports, Science and Technology of Japan.

### References

- Birbaumer N, Weber C, Neuper C, Buch E, Haagen K, Cohen L: Physiological regulation of thinking: brain-computer interface (BCI) research. *Prog Brain Res* 2006; **159**: 369–391. [[Medline](#)] [[CrossRef](#)]
- Pfurtscheller G, Muller GR, Pfurtscheller J, Gerner HJ, Rupp R: ‘Thought’ – control of functional electrical stimulation to restore hand grasp in a patient with tetraplegia. *Neurosci Lett* 2003; **351**: 33–36. [[Medline](#)] [[CrossRef](#)]
- Pfurtscheller G, Neuper C: Future prospects of ERD/ERS in the context of brain-computer interface (BCI) developments. *Prog Brain Res* 2006; **159**: 433–437. [[Medline](#)] [[CrossRef](#)]
- Neuper C, Pfurtscheller G: Event-related dynamics of cortical rhythms: frequency-specific features and functional correlates. *Int J Psychophysiol* 2001; **43**: 41–58. [[Medline](#)] [[CrossRef](#)]
- Kübler A, Birbaumer N: Brain-computer interfaces and communication in paralysis: extinction of goal directed thinking in completely paralysed patients? *Clin Neurophysiol* 2008; **119**: 2658–2666. [[Medline](#)] [[CrossRef](#)]
- Platz T, Kim IH, Pintschovius H, Winter T, Kieselbach A, Villringer K, Kurth R, Mauritz KH: Multimodal EEG analysis in man suggests impairment-specific changes in movement-related electric brain activity after stroke. *Brain* 2000; **123**: 2475–2490. [[Medline](#)] [[CrossRef](#)]
- Nitsche MA, Paulus W: Excitability changes induced in the human motor cortex by weak transcranial direct current stimulation. *J Physiol* 2000; **527**: 633–639. [[Medline](#)] [[CrossRef](#)]
- Bohannon RW, Smith MB: Interrater reliability of a modified Ashworth scale of muscle spasticity. *Phys Ther* 1987; **67**: 206–207. [[Medline](#)]
- Welch PD: The use of fast Fourier transform for the estimation of power spectra: A method based on time averaging over short, modified periodograms. *IEEE Trans Audio Electroacoust* 1967; **15**: 70–73. [[CrossRef](#)]
- Pfurtscheller G, Neuper C: Motor imagery activates primary sensorimotor area in humans. *Neurosci Lett* 1997; **239**: 65–68. [[Medline](#)] [[CrossRef](#)]
- Kaneko F, Murakami T, Onari K, Kurumadani H, Kawaguchi K: Decreased cortical excitability during motor imagery after disuse of an upper limb in humans. *Clin Neurophysiol* 2003; **114**: 2397–2403. [[Medline](#)] [[CrossRef](#)]
- Nitsche MA, Paulus W: Sustained excitability elevations induced by transcranial DC motor cortex stimulation in humans. *Neurology* 2001; **57**: 1899–1901. [[Medline](#)]
- Pfurtscheller G, Lopes da Silva FH: Event-related EEG/MEG synchronization and desynchronization: basic principles. *Clin Neurophysiol* 1999; **110**: 1842–1857. [[Medline](#)] [[CrossRef](#)]
- Matsumoto J, Fujiwara T, Takahashi O, Liu M, Kimura A, Ushiba J: Modulation of mu rhythm desynchronization during motor imagery by transcranial direct current stimulation. *J Neuroeng Rehabil* 2010; **7**: 27. [[Medline](#)] [[CrossRef](#)]
- Lopes da Silva F: Neural mechanisms underlying brain waves: from neural membranes to networks. *Electroencephalogr Clin Neurophysiol* 1991; **79**: 81–93. [[Medline](#)] [[CrossRef](#)]
- Nitsche MA, Nitsche MS, Klein CC, Tergau F, Rothwell JC, Paulus W: Level of action of cathodal DC polarisation induced inhibition of the human motor cortex. *Clin Neurophysiol* 2003; **114**: 600–604. [[Medline](#)] [[CrossRef](#)]
- Reis J, Schambra HM, Cohen LG, Buch ER, Fritsch B, Zarahn E,



- Celnik PA, Krakauer JW: Noninvasive cortical stimulation enhances motor skill acquisition over multiple days through an effect on consolidation. *Proc Natl Acad Sci USA* 2009; **106**: 1590–1595. [[Medline](#)] [[CrossRef](#)]
18. Paulus W: Outlasting excitability shifts induced by direct current stimulation of the human brain. *Suppl Clin Neurophysiol* 2004; **57**: 708–714. [[Medline](#)] [[CrossRef](#)]
  19. Liebetanz D, Nitsche MA, Tergau F, Paulus W: Pharmacological approach to the mechanisms of transcranial DC-stimulation-induced after-effects of human motor cortex excitability. *Brain* 2002; **125**: 2238–2247. [[Medline](#)] [[CrossRef](#)]
  20. Dimyan MA, Cohen LG: Neuroplasticity in the context of motor rehabilitation after stroke. *Nat Rev Neurol* 2011; **7**: 76–85. [[Medline](#)] [[CrossRef](#)]
  21. Roche N, Lackmy A, Achache V, Bussel B, Katz R: Impact of transcranial direct current stimulation on spinal network excitability in humans. *J Physiol* 2009; **587**: 5653–5664. [[CrossRef](#)]
  22. Cicinelli P, Marconi B, Zaccagnini M, Pasqualetti P, Filippi MM, Rossini PM: Imagery-induced cortical excitability changes in stroke: a transcranial magnetic stimulation study. *Cereb Cortex* 2006; **16**: 247–253. [[Medline](#)] [[CrossRef](#)]