
Clinical Investigative Study

Cortical Activation Changes in Patients Suffering from Post-Stroke Arm Spasticity and Treated with Botulinum Toxin A

Zuzana Tomášová, MD, Petr Hlušík, MD, MSc, PhD, Michal Král, MD, Pavel Otruba, MD, Roman Herzig, MD, PhD, Alois Krobot, MD, PhD, Petr Kaňovský, MD, PhD

From the Departments of Neurology (ZT, PH, MK, PO, RH, PK), Rehabilitation (AK) and Radiology (PH), Faculty of Medicine and Dentistry, Palacký University and University Hospital, Olomouc, Czech Republic.

ABSTRACT

BACKGROUND AND PURPOSE

Botulinum toxin (BoNT) treatment relieves focal arm spasticity after stroke, likely acting at several hierarchical levels of the motor system. The central correlate of BoNT-induced spasticity relief may be detected using repeated functional MRI (fMRI) during motor task.

METHODS

Five patients (4 males, 1 female, mean age 67 years) with hemiparesis and distal arm spasticity after chronic ischemic stroke were studied. fMRI was performed while moving the paretic hand in three sessions: before and 4 and 11 weeks after BoNT treatment.

RESULTS

Arm spasticity significantly decreased following BoNT treatment across the group (mean modified Ashworth scale change .6). fMRI prior to BoNT treatment showed extensive bilateral active networks, whereas post-BoNT activation was limited to midline and contralateral sensorimotor cortices, and the third examination, when the toxin effect has worn off, again showed extensive activation similar to pre-BoNT examination. Post-BoNT session 2 compared to sessions 1 and 3 demonstrated a significantly less activation in contralateral frontoparietal areas including inferior frontal, postcentral, and middle frontal gyri as well as transient crossed cerebellar activation.

CONCLUSION

Relief of post-stroke arm spasticity may be associated with changes at several hierarchical levels of the cortical sensorimotor system, including the prefrontal cortex.

Keywords: Stroke, arm spasticity, functional magnetic resonance imaging, finger movement, botulinum toxin.

Acceptance: Received January 4, 2011, and in revised form August 26, 2011. Accepted for publication September 17, 2011.

Correspondence: Address correspondence to Prof. MUDr. Ing. Petr Hlušík, PhD, Department of Neurology, University Hospital, I. P. Pavlova 6, 77520 Olomouc, Czech Republic. E-mail: phlustik@upol.cz.

Conflicts of Interest: There are no conflicts of interest associated with this manuscript, financial or otherwise. The manuscript has been read and approved by all authors.

The paper was presented in part as a lecture at the 60th Annual Meeting of the American Academy of Neurology in Chicago, IL, USA in April 2008 and as a poster at 18th Meeting of the European Neurological Society, Nice, France, in June 2008.

J Neuroimaging 2011;XX:1–8.
DOI: 10.1111/j.1552-6569.2011.00682.x

Introduction

Long-term sequelae of stroke include motor deficits, which are collectively described as the upper motor neuron syndrome, including both negative (eg, weakness) and positive (eg, spasticity) phenomena.^{1,2} Spasticity is a chronic motor disorder and is characterized by a velocity-dependent increase in tonic stretch reflex (muscle tone), with exaggerated tendon jerks resulting from hyperexcitability of the stretch reflex.³

It is generally recognized that spasticity after stroke may interfere with motor and activity performance, cause pain, and lead to secondary complications.⁴ Spasticity therapy has emerged as an important approach to alleviate such symptoms. Botulinum toxin A (BoNT), injected into the spastic muscles, has emerged as the first-line treatment of focal or multifocal spasticity.⁵

BoNT causes a temporary block of neuromuscular transmission by inhibiting acetylcholine release at the neuromuscular junction of both extrafusal and intrafusal muscle fibers. This dual effect of BoNT may also be related to modified spindle afferent discharge that could contribute to the antispastic action and there could be CNS changes involved as well.⁶ BoNT probably alters sensory inputs to the central nervous system with reduction of Ia afferent signals, and thus may indirectly induce secondary central changes in activation at several hierarchical levels of the motor system, presumably including cerebral cortex. This phenomenon has been already described in dystonia⁷⁻⁹ and observations at the CNS level have recently been reported also for cerebral spasticity.¹⁰⁻¹¹

We have previously studied the neuroanatomical correlate of BoNT-related post-stroke spasticity relief using functional

Table 1. Patient Characteristics

Patient No.	Sex	Age (years)	Lesion side	Lesion location	Initial NIHSS	Hand Dominance	Zung SDS		mMRC		Barthel index	Time Post-Stroke (months)
							Index	MMSE	FE	FF		
1	M	54	L	Thalamus, capsule, BG	9	D	31	24	3-4	4	85	15
2	M	60	R	BG, capsule	3	N	41	28	4	4-5	90	9
3	F	64	L	Thalamus, BG, capsule	5	D	50	N/A	3-4	4	65	13
4	M	77	L	Thalamus, capsule, BG	5	D	40	24	2-3	3	70	21
5	M	80	L	Thalamus	5	D	49	N/A	3-4	4	20	12
Summary	4M/1F	67.0 ± 11.1	4L/1R	Heterogeneous	5.4 ± 2.2	4D/1N	42.2 ± 7.7				66.0 ± 27.7	14.0 ± 4.4

Note: L = left; R = right; D = dominant hand impaired; BG = basal ganglia; NIHSS = NIH stroke scale; mMRC = modified MRC scale; FE = finger extensors; FF = finger flexors; N/A = not applicable – the MMSE score could not be interpreted because of the presence of expressive aphasia.

MRI (fMRI).¹¹ A small group of hemiplegic stroke patients exhibited changes in the activation of posterior cingulate related to BoNT spasticity treatment. However, the study presented several limitations: First, in the presence of hemiplegia, the motor task involved mental simulation of movement, which is difficult to monitor. Secondly, the two-session study design did not allow complete separation of the BoNT treatment effect from possible confounding effects of time and rehabilitation.

Our present fMRI study was designed to overcome these limitations studying hemiparetic patients with preserved hand movement and adding a third study session at the time point when BoNT effects diminish. This approach should allow more specific localization of central processes related to BoNT-induced spasticity relief.

Patients and Methods

Patients were studied using previously published protocol.¹¹ The following text summarizes the methodology and highlights differences particular for the present study.

Patients

The patients were recruited in the Stroke Centre at Department of Neurology, University Hospital, Olomouc, Czech Republic. The study was conducted in accordance with the Helsinki Declaration of 1975 (as revised in 2000) and it was approved by the local ethics committee of our hospital.

Study group consisted of 5 patients (4 males, 1 female; aged 67.0 ± 11.1 years, range 54-80). All patients suffered from distal arm paresis and spasticity following ischemic stroke at 1+ and higher of Modified Ashworth Scale, showed ability to cooperate during the performed examinations, and were enrolled after having provided informed consent with their participation in the study. Screening was performed to exclude patients with significant cognitive deficit (MMSE¹²), and depression (Zung Self-rating Depression Scale¹³). Further clinical evaluation included NIH stroke scale at stroke onset (from patients' records), and finger flexor and extensor strength (modified MRC scale¹⁴) and Barthel score at study enrollment.

The stroke in all patients has been diagnosed by clinical history, clinical examination, and brain MRI or brain CT examinations. The time from stroke onset to the study entry ranged from 9 to 21 months, mean was 14.0 months, SD = 4.0 months. In all patients, the infarction was visualized by MRI at the beginning of the study to reveal its size and location.

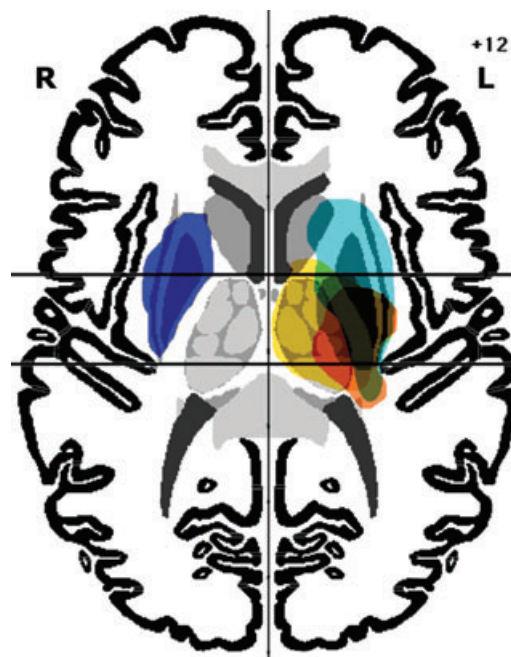

Fig 1. Lesion localization in individual patients displayed on an axial Talairach template ($z = +12$ mm).

The patients' characteristics are listed in Table 1, and the map of lesions is shown in Fig 1.

Behavioral Assessment

Spasticity was evaluated during clinical examination using the Modified Ashworth Scale.¹⁵ The motor function was assessed quantitatively according to a dedicated physiotherapeutic protocol, which tested the functional motor skills and was developed for use in a clinical rehabilitation setting using the Gross Motor Function Measure (GMFM) protocol template.¹⁶ The functional assessment was done by a rehabilitation specialist blinded to the protocol and treatment. The assessments were done at Week 0, when patients were screened, enrolled, and injected with BoNT, then at Week 4, four weeks following the injection of BoNT (when BoNT effect is assumed to be maximal), and at Week 11, eleven weeks after BoNT injection (disappearance of BoNT effect). Since physiotherapy effects are expected to be gradually developing over time, this longitudinal design permits their separation from the transient effect of BoNT, as

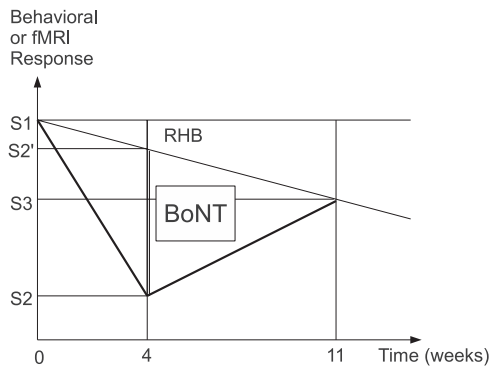


Fig 2. Decomposition of treatment effect at 4 weeks ($S_2 - S_1$) into progressive rehabilitation $RHB = S_2' - S_1$ and transient botulinum toxin $BoNT = S_2 - S_2'$ (vertical double line) components; S_2' is the weighted average of the first (S_1) and third (S_3) sessions. See Methods for additional description and the formula.

illustrated in Figure 2. When a behavioral or imaging parameter changes from session 1 (S_1) to session 2 (S_2) and session 3 (S_3), the treatment effect at session 2 (difference $S_2 - S_1$) may be decomposed into a transient $BoNT$ effect and a progressive effect of time and rehabilitation (RHB) using a specific statistical contrast (see Data Analysis).

Treatment

The patients were treated with botulinum toxin A injections into the muscles of affected arm, and then they underwent intensive rehabilitation treatment (according to the tailored protocol) for the period of 4 weeks. The $BoNT$ injections were done according to the WE MOVE (Worldwide Education and Awareness for Movement Disorders) recommendations, and on the basis of previous clinical experience of ours and other investigators.^{17,18} Botulinum toxin A (BOTOX[®], Allergan Inc., Irvine, CA) was used for the preparation of solution. The flexor carpi radialis, flexor carpi ulnaris, flexor digitorum superficialis, and flexor digitorum profundus muscles were always injected, and the dose used for the injection into one muscle was always 50 U. Injection of $BoNT$ into each muscle in all 5 patients was always performed with the EMG guidance, preferably with electrical stimulation for localization of the muscle intended to be treated. All patients were receiving antiplatelet therapy, so digital compression of the injection site was performed for at least 1 minute after each injection. Fifteen minutes after the injection, the injection sites were inspected.

The rehabilitation treatment, aiming to reduce spasticity in the paretic upper limb, was done during the admittance to the hospital ward and the treatment was started the second day after the injection procedure. Each workday, the patients underwent two sessions of tailored rehabilitation treatment, for a total of 1 hour, using a combination of postural therapy from the Bobath concept and diagonal patterns from PNF (proprioceptive neuromuscular facilitation). Inpatient physiotherapy (4 weeks) was followed by outpatient therapy until the third clinical and fMRI evaluation (total of 11 weeks). The protocol of rehabilitation treatment was set up prior to the start of the study and the proper adherence of rehabilitation treatment to the protocol was repeatedly checked during the sessions.¹⁶

Tasks

One day before the functional brain imaging session, subjects learned and practiced a sequential finger movement (Roland's paradigm¹⁹) with the paretic hand, at the rate of approximately one movement every second. On the following day, a short practice session immediately preceded the imaging session.

In the MRI scanner, hand movements were performed with eyes closed, beginning and end of movement blocks were signaled verbally (start/stop) in MR-compatible headphones. In a block paradigm, sequential finger movement alternated with rest (15 s). Each experimental run consisted of 12 repetitions of the same movement-rest block pairs, for a total of 6 minutes. Each participant had two experimental runs with the impaired hand. Like the behavioral assessments, the fMRI examinations were done at Week 0, Week 4, and Week 11.

Data Acquisition

Magnetic resonance imaging data were acquired on 1.5 Tesla scanners (Avanto and Symphony, Siemens, Erlangen, Germany) with a standard head coil. The MR imaging protocol covered the whole brain with 30 axial slices 5 mm thick, including anatomical T_1 -weighted images to provide an immediate overlay with functional data, fluid-attenuated inversion recovery (FLAIR) images to visualize brain lesions, functional T_2^* -weighted (blood oxygenation level-dependent [BOLD]) images during task performance and rest, and a high-resolution 3D anatomical scan (MPRAGE). BOLD images were acquired with gradient echo EPI, $TR/TE = 2500/40$ ms, FOV 220 mm, to provide $3.4 \times 3.4 \times 5$ mm resolution. 144 volumes were acquired per each 6-minute functional run. Subject's head was immobilized with cushions to assure maximum comfort and minimize head motion. Task performance and the presence of mirror movements were monitored visually. Runs containing errors were aborted and restarted.

Analysis

Prior to fMRI analysis, the imaging data of 1 patient with right-hemispheric lesions were flipped in the left-right direction to allow group analysis of movement with the impaired hand.²⁰ fMRI data processing was carried out using FMRI Expert Analysis Tool (FEAT) Version 5.98, part of FMRIB's Software Library (FSL; www.fmrib.ox.ac.uk/fsl). The following pre-statistics processing was applied; motion correction using MCFLIRT;²¹ slice-timing correction using Fourier-space time-series phase-shifting; non-brain removal using BET;²² spatial smoothing using a Gaussian kernel of full width at half-maximum (FWHM) 10 mm; grand-mean intensity normalization of the entire 4D data set by a single multiplicative factor; high-pass temporal filtering (Gaussian-weighted least-squares straight line fitting, with $\sigma = 15.0$ s). Time-series statistical analysis was carried out using FILM with local autocorrelation correction, including the 6 motion estimate vectors in the model to remove residual signal changes due to motion.²³ Registration to high-resolution structural and/or standard space images was carried out using FLIRT.^{21,24}

Higher-level analysis was carried out using FMRIB's Local Analysis of Mixed Effects (FLAME) stage 1 and 2 with

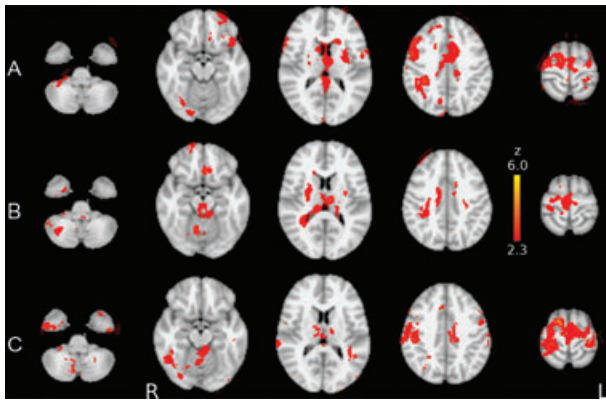


Fig 3. fMRI activation of the motor system during finger movement (A) before BoNT treatment, (B) after BoNT treatment of arm spasticity, and (C) during off-BoNT examination. Group average statistical maps (z-score) are overlaid in color on the MNI anatomical template. Right side of the brain is displayed on the left.

automatic outlier detection.²⁵⁻²⁷ Z (Gaussianized T/F) statistic images were thresholded using clusters determined by $Z > 2.3$ and a (corrected) cluster significance threshold of $P = .05$.²⁸ This analysis produced group mean activation maps for each of the three sessions. Additionally, between-session differences in the magnitude of activation (BOLD response) were tested with post hoc linear contrasts (paired *t*-tests). The effect of BoNT treatment independent of time (see Fig 2) was tested with specific post hoc linear contrasts, comparing the weighted average of sessions 1 and 3 ($S2'$) with session 2, using temporal distance from session 2 as the weights: $S2' = (7*S1 + 4*S3)/11$ versus $S2$.

Results

Behavioral

BoNT treatment caused a reduction in arm spasticity across the group (mean MAS change from baseline .6, $P = .07$, one-sided paired *t*-test) 4 weeks after the BoNT injection. The mean MAS scores were: at Week 0: 2.3 (SD .67), at Week 4: 1.7 points (SD .27), and at Week 11: 2.2 points (SD .45). MAS scores at Week 11 did not significantly differ from Week 0 (MAS change.1, $P = .352$, one-sided paired *t*-test). Visual monitoring did not reveal the presence of significant mirror movements.

Imaging

Group maps of fMRI activation during impaired hand movement prior to BoNT treatment showed an extensive participation of active areas in both hemispheres, including contralateral primary motor cortex, supplementary motor area (SMA), bilateral premotor cortices, superior parietal lobe, and basal ganglia (Fig 3A). Movement-related fMRI changes during hand movement after BoNT treatment were restricted to midline and contralateral sensory and motor cortices (Fig 3B). During session 3 (Week 11), a pattern of extensive activation of sensorimotor cortical areas reappeared, very similar to the pre-BoNT examination (Fig 3C). Whereas visual inspection suggests several areas differing in activation between session 1 (pre-treatment) and

3 (off-BoNT), direct comparison using a paired *t*-test revealed no areas of significantly different activation (BOLD response) magnitude.

Across the patient group, the activation map of average statistical differences between the post-BoNT session (W4) and sessions 1 and 3 manifested a transient crossed cerebellar activation (physiological), absent in pre- and off-BoNT examinations. On the other hand, the complementary contrast revealed a significant decrease ($P < .05$) in activation of the contralateral cortical network including the following areas: dorsolateral prefrontal cortex (DLPFC), inferior parietal lobule, premotor cortex, inferior frontal gyrus (Broca's area), and postcentral gyrus (see Table 2). The strongest hotspot located in the DLPFC is shown in Figure 4.

Discussion

There is extensive and ever growing evidence that the evolution of post-stroke deficits is paralleled by reorganization in multiple brain structures.²⁹ These changes may apparently be both beneficial, such as those underlying recovery,²⁹ and detrimental, ie, may impair residual function (so-called maladaptive plasticity). Examples of maladaptive plasticity in the brain include dystonia, phantom limb pain after amputation, and allodynia,³⁰⁻³² and possibly also the development of pain and spasticity after stroke.

In our present study, analogous to our previous work,³³ we have reviewed functional neuroimaging findings on plasticity phenomena occurring in connection with post-stroke arm spasticity and their relationship to functional improvement induced by BoNT treatment.

Previously, we have studied the cortical correlates of BoNT-related relief of spasticity in a group of hemiplegic stroke patients.³³ However, that study presented several limitations: First, in the presence of hemiplegia, the motor task involved mental simulation of movement, which is difficult to monitor. Secondly, the two-session study design did not allow complete separation of the BoNT treatment effect from possible confounding effects of time and rehabilitation. In view of these limitations, in the present study we assessed the changes in cortical activation in patients with preserved hand movement examined in 3 fMRI sessions, ie, adding a third study session at the time point when BoNT effects diminish. This approach permits decomposition of transient (BoNT) and progressive (rehabilitation, recovery) changes as described in the Methods and illustrated in Figure 2 and should allow more specific localization of central processes related to BoNT-induced spasticity relief.

In each session, finger movements with the paretic hand evoked activation in the well-described frontoparietal sensorimotor system; the most significant regions of activation during movement of the stroke-affected hand were found in the contralateral motor cortex, SMA, bilateral premotor cortices, and the superior and inferior parietal lobe.

The analysis across sessions identified three clusters in which fMRI signal changed significantly with improved post-stroke arm spasticity after BoNT treatment: the standard parts of motor system (primary motor and somatosensory cortex,

Table 2. Regions Showing BOLD Response Changes Related to BTX Treatment

Region (H-O)	Z-max	x	y	z
43% IFG/BA44	6.93	-54	34	8
27% IFG/BA44, 23% IFG/BA45	6.31	-58	22	10
72% PostCG, 5% SMG	6.08	-58	-18	42
52% PostCG, 26% SMG	6.04	-60	-24	42
51% MFG	5.84	-40	14	48
47% MFG, 2% SFG	5.6	-38	14	52

H-O = Harvard-Oxford Cortical Structural Atlas; IFG = inferior frontal gyrus; PostCG = postcentral gyrus; SMG = supramarginal gyrus; MFG = middle frontal gyrus; BA = Brodmann area.

premotor cortex) with decreased fMRI activity, cortical areas participating in cognitive aspects of movement control and planning (DLPFC, Broca's area), and the cerebellum (with transient crossed activation at session 2).

First, BoNT treatment induced a clear reduction in the extent and also more prominent lateralization of the active sensorimotor network (see Fig 2), similar to that shown previously in motor recovery after stroke.^{20,34} A similar effect representing a trend toward normalization of movement-induced brain activation was reported by Manganotti and colleagues¹⁰ in a study similar to ours, involving stroke patients with hemipare-

sis and upper-limb spasticity studied treated with BoNT-A and studied with fMRI. However, there are several methodological differences between Manganotti and colleagues¹⁰ and our study, which limit a more detailed comparison of their results: First, their study involved two examinations and no rehabilitation; our study included three examinations and concomitant rehabilitation. Secondly, their fMRI motor activation was quantified using within-subject analysis, thresholding, and voxel counting. This permits observation of individual effects but thresholding individual data is sensitive to other sources of BOLD signal variability besides the treatment effect even in normal subjects, and even more so in patients. In contrast, our study relied on more common group analysis using a common anatomical space and between-session contrasts implemented as direct statistical comparison of the local BOLD response across sessions, which is considered more robust. Additionally, Manganotti and colleagues included patients with brain hemorrhage, where hemosiderin deposits may contribute to BOLD signal variability, whereas our study selected only brain infarctions. On the other hand, our study lacked within-scanner EMG monitoring, so we could not assess the suggested role of muscle synkinesias and co-contraction in the observed extended recruitment of sensorimotor cortical areas.¹⁰ Still, there are several arguments against a dominant role of this particular factor: extended recruitment of sensorimotor

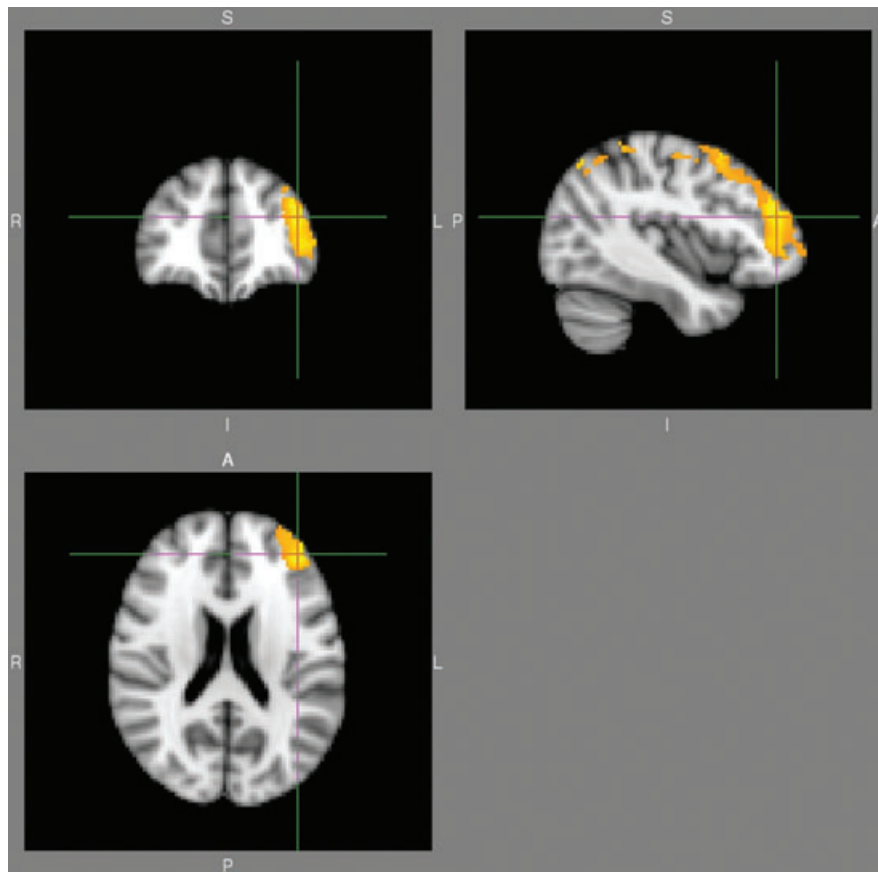


Fig 4. BoNT treatment effect—DLPFC, location of the most significant decrease in motor system activation after BoNT treatment. Group post hoc contrast (z-score) comparing session 2 to the weighted average of sessions 1 and 3 (see Fig 2 and Methods for more detailed description) is overlaid on the MNI anatomical template. Right side of the brain is displayed on the left.

cortices has been reported in stroke hemiparesis even in the absence of significant spasticity and co-contractions, eg, by Ward and colleagues^{20,34} Furthermore, we have observed an analogous extended pattern during motor imagery in stroke patients with hand plegia.¹¹ Finally, such overactivation has been described in other neurological conditions with motor deficit but without manifest synkinesias and co-contractions, such as multiple sclerosis and amyotrophic lateral sclerosis. Hence, enhanced recruitment of sensorimotor cortical areas seems to be a more general compensatory pattern in the presence of motor deficit.

It may be noted that group statistical maps for sessions 1 (pre-treatment; see Fig 3A) and 3 (off-BoNT; Fig 3C) do manifest visible differences in the activation patterns, which contrasts with the absence of significant differences found on direct statistical comparison. Although group statistical maps may suggest general trends for differences and changes, their spatial patterns may exaggerate minor differences through the (albeit necessary) use of thresholding; activation in a particular region may be slightly above threshold in one condition and slightly below threshold in another while the use of thresholding changes this rather small quantitative difference to a conspicuous qualitative active-inactive difference.

Our second regional result and a new finding was the relative treatment-induced decrease of activation in a contralateral frontoparietal network with hotspots including (in the order of decreasing significance) inferior frontal gyrus, postcentral gyrus, and middle frontal gyrus/dorsolateral prefrontal cortex.

As mentioned above, impaired hand movements activated an extensive mostly bilateral network of active areas in primary and non-primary sensorimotor regions during the performance of a motor task. SMA and premotor cortex are both supposed to be involved in higher order motor functions, such as planning of action, coordination, and timing of voluntary action and these regions are highly interconnected within and between hemispheres. Beyond these expected results, we may speculate on the origins of the pre-treatment overactivation of inferior frontal gyrus, postcentral gyrus, and middle frontal gyrus/dorsolateral prefrontal cortex. It is possible that cortical areas which were not previously involved in the specific function become active during the performance of task that utilizes impaired functional areas or networks. It can also signify a general response pattern of the lesioned brain as a maladaptive compensatory mechanism related to a lasting increased pathological proprioceptive afferentation (via Ia fibers) associated with spasticity. BoNT therapeutic alteration or suppression of this form of cortical "plasticity" normalizes temporarily the extensive activation of mentioned cortical areas, while it transiently restores the expected activation of the cerebellum.

The canonical cortical motor network is thought to consist of frontal areas including the primary motor cortex, dorsal and ventral lateral premotor cortex, SMA, and cingulate motor areas (CMA), interconnected at the cortical level and with projections to spinal cord motor neurons.³⁵ Under pathological conditions, such as stroke damaging the motor-related structures, it is assumed that the movement-related functional circuit becomes extended and includes structures outside the classical motor system.³⁶

Dynamic shifts in the strength of preexisting connections across distributed neural networks, changes in task-related cortico-cortical and corticosubcortical coherence, and modifications of the mapping between behavior and neural activity take place in response to changes in afferent input or efferent demand. Such rapid, ongoing changes may be followed by the establishment of new connections through dendritic growth and arborization. However, they harbor the danger that the evolving pattern of neural activation may in itself lead to abnormal behavior. Plasticity is the mechanism for development and learning, as much as a cause of pathology.²⁹

For the treatment-related normalized activation within the contralateral frontoparietal cortical network, we favor the interpretation that BoNT, through blockage of the neuromuscular junction of the γ -motor neurons, induces a reduction of Ia afferent signals and thus indirectly inhibits pre-existing feedback-driven execution mode. In this way, it alters impaired gating of sensory inputs to the central nervous system. This concept is in line with studies investigating the central effects of BoNT treatment in patients with focal dystonia³⁷⁻³⁹ using techniques such as EMG, PET, and fMRI, the results of which suggest central reorganization following botulinum toxin treatment.

One of the aims of our study design was to permit the analysis of BoNT effect independently of possible parallel processes of spontaneous functional recovery and motor rehabilitation-related changes, as described previously. We therefore assume that our observed pattern of change is more likely to be related to relief of spasticity rather than to the concomitant physical therapy.

Brodman areas (BA) 44 and 45 in the left inferior frontal gyrus form Broca's area, classically considered the region of brain responsible for speech production. The presence of Broca's area deactivation after BoNT therapy applied to the arm may thus be surprising. Recently, however, several experiments have shown that Broca's area is involved in many different cognitive and perceptual tasks as well as motor tasks, not necessarily related to speech. Besides language function, one important contribution of BA44 is found in the motor domain and motor-related processes.⁴⁰ Several studies reported significant activation of BA 44 during execution of grasping and manipulation.⁴¹⁻⁴³

The DLPFC is an association area, consisting of BA 9 and 46 with different cytoarchitecture and different connectivity than the more posterior motor areas of the frontal lobe. Although the role of the DLPFC was considered to be limited to only such functions as working memory, executive functions, and decision making, in a few previously published studies DLPFC has also been related to motor performance and motor skill.⁴⁴ In the presence of spasticity, it is possible that the patients adapt their strategy to cope with the required sequential finger movement, engaging the Broca's area and DLPFC. We favor the alternative, although not mutually exclusive, explanation that frontal cortical areas may engage in the programming of movement when the classical motor structures are gated by the abnormal proprioceptive input from the spastic muscles of the paretic extremity.

Lastly, transient (physiological) cerebellar activation appearing at session 2 may result from improvement of motor function

associated with the relative “normalization” of motor system activation at that time. This may relate to the reported cerebellar engagement when motor system activation approaches the normal pattern with successful motor recovery⁴⁵ or intensive rehabilitation⁴⁶ after stroke. In our study, the return of spasticity at session 3 likely dominates over the effects of rehabilitation and so cerebellar activation becomes diminished again.

Another study using a combination of rehabilitation and BoNT for chronic post-stroke arm spasticity⁴⁷ reported fMRI activity increases in the ipsilesional primary sensorimotor cortex and in the contralesional secondary somatosensory area following 14 weeks of repetitive arm cycling. Whereas this is in good agreement with other studies of rehabilitation alone,⁴⁶ the protocol of Diserens and colleagues⁴⁷ did not include fMRI examinations at the time of maximum BoNT effect (our session 2) and thus the (transient) effect of BoNT cannot be evaluated and compared with our study. On the other hand, our study did not find significant fMRI changes due to rehabilitation over the 11 weeks (comparing sessions 1 and 3). This could result from differences in patient characteristics (stroke size and location, degree and character of motor deficit, group size), as well as different duration and character of physiotherapy. A more comprehensive study would be required to properly evaluate both the transient and long-term changes due to BoNT and physiotherapy, applied alone as well as together.

We have to acknowledge the relatively small size of our patient group, which reduces the overall statistical power to detect smaller effects and the selection of subcortical infarcts only, which further limits the possibility to generalize the results to the whole population of patients suffering from arm spasticity after stroke.

Conclusion

The present study suggests that structures both within and outside the classical sensorimotor system may be associated with the relief of post-stroke arm spasticity. Broca’s area and the DLPFC region have been implicated in complex cognitive functions, however, in special circumstances they may participate in modulation of sensorimotor processing as well.

We thank Andrea Bártková, MD, PhD, Martin Nevrlý, MD, and Hana Pírkrylová-Vranová, MD, for patient recruitment. This work was supported by the IGA Ministry of Health Czech Republic grant number NS9920-4/2008.

References

1. Sheean G. Neurophysiology of spasticity. In: Barnes M, Johnson G, eds. *Upper Motor Neuron Syndrome and Spasticity*. Cambridge: Cambridge University Press; 2001:12-78.
2. Burke D. Spasticity as an adaptation to pyramidal tract injury. *Adv Neurol* 1988;47:401-423.
3. Lance JW. The control of muscle tone, reflexes, and movement: Robert Wartenberg Lecture. *Neurology* 1980;30:1303-1313.
4. Collin C, Wade DT, Davies S, et al. The Barthel ADL Index: a reliability study. *Int Disabil Stud* 1988;10:61-63.
5. Simpson DM, Gracies JM, Yablou SA, et al. Botulinum neurotoxin versus tizanidine in upper limb spasticity: a placebo-controlled study. *J Neurol Neurosurg Psychiatry* 2009;80:380-385.
6. Antonucci F, Rossi C, Gianfranceschi L, et al. Long-distance retrograde effects of botulinum neurotoxin A. *J Neurosci* 2008;28:3689-3696.
7. Kaňovský P, Bareš M, Dufek J. *Spasticita: mechanismy, diagnostika a léčba*. Praha: Maxdorf, 2004.
8. Kaňovský P, Streitová H, Daniel P, et al. Long-term remission of cervical dystonia induced by treatment with botulotoxin A—Signal of the possible effect on the central dystonic mechanism? (in Czech). *Ces Slov Neurol Neurochir* 1998;61:123-134.
9. Kaňovský P, Streitová H, Dufek J, et al. Change in lateralization of the P22/N30 cortical component of median nerve somatosensory evoked potentials in patients with cervical dystonia after successful treatment with botulinum toxin A. *Mov Disord* 1998;13:108-117.
10. Manganotti P, Acler M, Formaggio E, et al. Changes in cerebral activity after decreased upper-limb hypertonus: an EMG-fMRI study. *Magn Reson Imaging* 2010;28(5):646-652.
11. Šenkárová Z, Hlušík P, Otruba P, et al. Modulation of cortical activity in patients suffering from upper arm spasticity following stroke and treated with botulinum toxin A: an fMRI study. *J Neuroimaging* 2010;20:9-15.
12. Folstein MF, Folstein SE, McHugh PR. “Mini-mental state”. A practical method for grading the cognitive state of patients for the clinician. *J Psychiatr Res* 1975;12:189-198.
13. Zung WW. A self-rating depression scale. *Arch Gen Psychiatry* 1965;12:63-70.
14. Paternostro-Sluga T, Grim-Stieger M, Posch M, et al. Reliability and validity of the Medical Research Council (MRC) scale and a modified scale for testing muscle strength in patients with radial palsy. *J Rehabil Med* 2008;40:665-671.
15. Bohannon RW, Smith MB. Interrater reliability of a modified Ashworth scale of muscle spasticity. *Phys Ther* 1987;67:206-207.
16. Krobot A, Schusterová B, Tomsová J, et al. Specific protocol of physiotherapy in stroke patients (in Czech). *Ces Slov Neurol Neurochir* 2008;71/104:V74.
17. Kanovsky P, Slawek J, Denes Z, et al. Efficacy and safety of botulinum neurotoxin NT 201 in poststroke upper limb spasticity. *Clin Neuropharmacol* 2009;32(5):259-265.
18. Brashear A, Gordon MP, Elovic E, et al. Intramuscular injection of botulinum toxin for the treatment of wrist and finger spasticity after a stroke. *N Engl J Med* 2002;347:395-400.
19. Roland PE, Larsen B, Lassen NA, et al. Supplementary motor area and other cortical areas in organisation of voluntary movements in man. *J Neurophysiol* 1980;43: 118-136.
20. Ward NS, Brown MM, Thompson AJ, et al. Neural correlates of outcome after stroke: a cross-sectional fMRI study. *Brain* 2003;126:1430-1448.
21. Jenkinson M, Bannister P, Brady M, et al. Improved optimization for the robust and accurate linear registration and motion correction of brain images. *Neuroimage* 2002;17:825-841.
22. Smith SM. Fast robust automated brain extraction. *Hum Brain Mapp* 2002;17:143-155.
23. Woolrich MW, Ripley BD, Brady M, et al. Temporal autocorrelation in univariate linear modeling of FMRI data. *Neuroimage* 2001;14:1370-1386.
24. Jenkinson M, Smith S. A global optimisation method for robust affine registration of brain images. *Med Image Anal* 2001;5:143-156.
25. Beckmann CF, Jenkinson M, Smith SM. General multilevel linear modeling for group analysis in FMRI. *Neuroimage* 2003;20:1052-1063.
26. Woolrich MW, Behrens TE, Beckmann CF, et al. Multilevel linear modelling for FMRI group analysis using Bayesian inference. *Neuroimage* 2004;21:1732-1747.
27. Woolrich M. Robust group analysis using outlier inference. *Neuroimage* 2008;41:286-301.
28. Worsley KJ. Statistical analysis of activation images. In: Jezzard P, Matthews PM, Smith SM, eds. *Functional MRI: An Introduction to Methods*. Oxford: Oxford University Press, 2001:251-270.

29. Pascual-Leone A, Amedi A, Fregni F, et al. The plastic human brain cortex. *Annu Rev Neurosci* 2005;28:377-401.
30. Pujol J, Roset-Llobet J, Rosines-Cubells D, et al. Brain cortical activation during guitar-induced hand dystonia studied by functional MRI. *Neuroimage* 2000;12:257-267.
31. Flor H. Remapping somatosensory cortex after injury. *Adv Neurol* 2003;93:195-204.
32. Maihofner C, Handwerker HO, Birklein F. Functional imaging of allodynia in complex regional pain syndrome. *Neurology* 2006;66:711-717.
33. Dressler D, Adib Saberi F. Botulinum toxin: mechanisms of action. *Eur Neurol* 2005;53:3-9.
34. Ward NS, Brown MM, Thompson AJ, et al. Neural correlates of motor recovery after stroke: a longitudinal fMRI study. *Brain* 2003;126:2476-2496.
35. Strick PL. Anatomical organization of multiple motor areas in the frontal lobe: implications for recovery of function. *Adv Neurol* 1987;47:293-312.
36. Weiller C, Chollet F, Friston KJ, et al. Functional reorganization of the brain in recovery from striatocapsular infarction in man. *Ann Neurol* 1992;31:463-472.
37. Gelb DJ, Yoshimura DM, Olney RK, et al. Change in pattern of muscle activity following botulinum toxin injections for torticollis. *Ann Neurol* 1991;29:370-376.
38. Ceballos-Baumann AO, Sheean G, Passingham RE, et al. Botulinum toxin does not reverse the cortical dysfunction associated with writer's cramp. A PET study. *Brain* 1997;120:571-582.
39. Opavský R, Hluštík P, Otruba P, et al. Sensorimotor network in cervical dystonia and the effect of botulinum toxin treatment: a functional MRI study. *J Neurol Sci* 2011;306:71-75.
40. Fadiga L, Craighero L. Hand actions and speech representation in Broca's area. *Cortex* 2006;42:486-490.
41. Binkofski F, Buccino G, Posse S, et al. A fronto-parietal circuit for object manipulation in man: evidence from an fMRI-study. *Eur J Neurosci* 1999;11:3276-3286.
42. Gerardin E, Sirigu A, Lehericy S, et al. Partially overlapping neural networks for real and imagined hand movements. *Cereb Cortex* 2000;10:1093-104.
43. Grezes J, Armony JL, Rowe J, et al. Activations related to "mirror" and "canonical" neurones in the human brain: an fMRI study. *Neuroimage* 2003;18:928-937.
44. Halsband U, Lange RK. Motor learning in man: a review of functional and clinical studies. *J Physiol Paris* 2006;99:414-424.
45. Small SL, Hlustik P, Noll DC, et al. Cerebellar hemispheric activation ipsilateral to the paretic hand correlates with functional recovery after stroke. *Brain* 2002;125:1544-1557.
46. Johansen-Berg H, Dawes H, Guy C, et al. Correlation between motor improvements and altered fMRI activity after rehabilitative therapy. *Brain* 2002;125:2731-2742.
47. Diserens K, Ruegg D, Kleiser R, et al. Effect of repetitive arm cycling following botulinum toxin injection for poststroke spasticity: evidence from fMRI. *Neurorehabil Neural Repair* 2010;24:753-762.