

The authors thank Shirley McCartney, PhD, for editorial assistance and Andy Rekito, MS, for illustrative assistance.

References

1. Aleksic I, Sommer SP, Kottenberg-Assenmacher E, et al. Cardiac operations in the presence of meningioma. *Ann Thorac Surg* 2009;88:1264–8.
2. Grigore AM, Grocott HP, Newman MF. Anesthetic management of a patient with a brain tumor for cardiac surgery. *J Cardiothorac Vasc Anesth* 2000;14:702–4.
3. Kurisu K, Hisahara M, Ando Y, Tominaga R. An unusual manifestation of brain tumor: development of delayed hemiplegia after cardiopulmonary bypass. *J Card Surg* 2007;22:417–8.
4. Maeda K, Gotoh H, Chikui E, Furusawa T. Intratumoral hemorrhage from a posterior fossa tumor after cardiac valve surgery—case report. *Neurol Med Chir (Tokyo)* 2001;41:548–50.
5. Slavin ML. Acute remitting visual loss after coronary artery bypass surgery caused by a suprasellar meningioma. *Am J Ophthalmol* 1987;104:434–5.
6. Tashiro T, Zaitu R, Nakamura K, et al. Off-pump CABG for a patient with a brain tumor. *Ann Thorac Cardiovasc Surg* 2000;6:193–5.
7. Harris DN, Oatridge A, Dob D, Smith PL, Taylor KM, Bydder GM. Cerebral swelling after normothermic cardiopulmonary bypass. *Anesthesiology* 1998;88:340–5.
8. Ellis JA, D'Amico R, Sisti MB, et al. Pre-operative intracranial meningioma embolization. *Expert Rev Neurother* 2011;11:545–56.

Occlusion of Modified Blalock-Taussig Shunt After Clopidogrel Cessation

Vassilios Spiridon Avlonitis, MD, PhD,
Silvia Planas, MD, Alison M. Hayes, MBBS, FRCP, and
Andrew Parry, FRCS (CTh)

Bristol Heart Institute, and Histopathology Department, Bristol Royal Infirmary, Bristol; and Bristol Royal Hospital for Sick Children, Bristol, United Kingdom

It has been suggested previously that rebound hypercoagulability may be responsible for morbidity and mortality following clopidogrel cessation in adults with acute coronary syndrome. We report a case of acute occlusion of a modified Blalock-Taussig shunt in an infant after clopidogrel discontinuation.

(Ann Thorac Surg 2012;93:656–8)

© 2012 by The Society of Thoracic Surgeons

Acute occlusion of a modified Blalock-Taussig shunt (MBTS) is a potentially catastrophic complication. A recent study showed that patients treated with clopidogrel after acute coronary syndrome are at high risk of acute myocardial infarction and death early after discontinuation of the drug [1]. This finding suggested a possi-

ble rebound effect associated with abrupt clopidogrel cessation. We report a case of acute thrombosis of a MBTS following clopidogrel discontinuation.

A male child was born at 40 weeks' gestation with an antenatal diagnosis of tricuspid and pulmonary atresia and ventricular septal defect. At birth, echocardiography showed several major aortopulmonary collateral arteries (MAPCAs), atrial septal defect, tricuspid atresia, two ventricular septal defects, small right ventricle, pulmonary atresia, and right aortic arch. At 5 days of age, he underwent cardiac catheterization, and at 7 weeks of age he underwent unifocalization of all MAPCAs with augmentation of the central portion using autologous pericardium. A MBTS was performed between the left subclavian artery and the unifocalized arteries using a 3.5-mm polytetrafluoroethylene graft. The operation and postoperative recovery were uneventful, and the patient was discharged 9 days later, receiving aspirin (5 mg/kg) and clopidogrel (0.2 mg/kg). Oxygen saturations at discharge were 75%.

At follow-up, at age 20 weeks, the child exhibited dyspnea with oxygen saturations between 70% and 75%. Echocardiography showed reduced flow in the left pulmonary artery, and cardiac catheterization confirmed stenosis of the left MAPCA as it passed over the left bronchus. The decision was made to perform an additional left MBTS to the left neopulmonary artery. The clopidogrel was discontinued in preparation for surgery, but the operation had to be postponed because the child developed viral conjunctivitis. Aspirin treatment was restarted, but clopidogrel was not because of the imminent surgery.

The child was taken to surgery 7 days later with an oxygen saturation of 75%. After performing a left thoracotomy, he became increasingly cyanotic and the oxygen saturation fell dramatically, leading to bradycardia. The diagnosis of occlusion of the previous MBTS was made. The child was immediately positioned supine, cardiopulmonary resuscitation was performed, and cardiopulmonary bypass was established through cannulation of the left femoral vessels. A repeated sternotomy was performed. The previous shunt was excised and found to be occluded with a white granular clot. A new 3.5-mm central shunt was constructed between the left side of the ascending aorta and the branch pulmonary arteries. Cardiopulmonary bypass was discontinued on low-dose inotropic support, protamine was administered, the femoral vessels were repaired, and the chest was closed.

The patient was transferred to the intensive care unit. During the first 24 hours, he had episodes of desaturation. Because of the preceding arrest, there were concerns regarding neurologic status. Electroencephalography showed nonconvulsive status epilepticus, which was treated with phenytoin. On the fifth postoperative day, the patient developed anisocoria. Magnetic resonance imaging of the brain showed diffuse edema and changes consistent with severe diffuse ischemic damage. The child deteriorated and died on the 12th postoperative

Accepted for publication July 26, 2011.

Address correspondence to Dr Avlonitis, Bristol Heart Institute, Bristol Royal Infirmary, Upper Maudlin St, Bristol, BS2 8HW, United Kingdom; e-mail: avlonitis@hotmail.com.

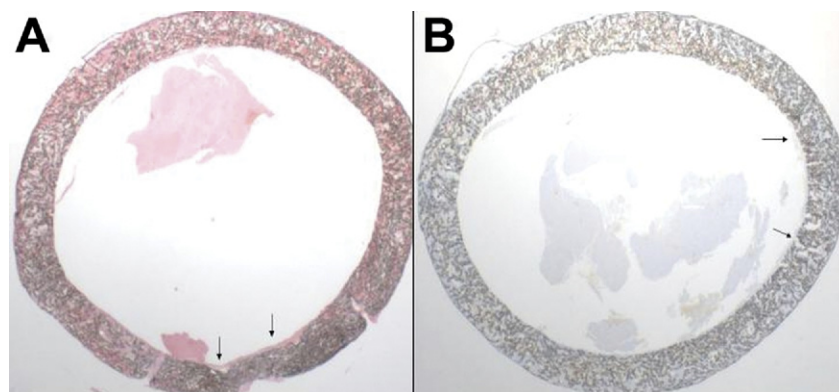


Fig 1. Histologic section of the occluded shunt. (A) Hematoxylin-eosin stain shows eosinophilic material within the lumen, focally attached to the underlying wall (arrows) in keeping with a thrombus. (B) Martius Scarlet Blue trichrome stain, which selectively stains fibrin in red. The stain demonstrates the absence of fibrin within the thrombus (arrows), which is composed of platelets only.

day. Histologic examination of the occluded shunt showed no evidence of fibrin thrombi (Fig 1).

Comment

The MBTS is commonly used in neonates with cyanotic heart disease to achieve palliation and stability until definitive surgical correction can be performed. While many centers are moving away from this method as palliation for two-ventricle circulations, there is no alternative in patients with pulmonary atresia who require single-ventricle palliation.

One of the most lethal complications of MBTS is acute occlusion of the shunt. Li and colleagues [2] reported 1-year Kaplan-Meier event rates for shunt occlusion of 11% and 16% for closed and open (with cardiopulmonary bypass) shunts, respectively. The United Kingdom data show a 30-day and 1-year mortality for arterial shunt of 12.6% and 34%, respectively [3]. Studies have shown that shunts of smaller caliber are more prone to stenosis or occlusion [4, 5].

Although the evidence for the benefits of anticoagulation in preventing MBTS stenosis and occlusion have been conflicting, it is common practice to administer heparin intraoperatively and commence long-term aspirin postoperatively [6]. In a large retrospective study, Li and colleagues [2] showed a lower risk of shunt occlusion and death in infants receiving aspirin. The advantages of other modern antiplatelet agents have not been investigated. Our patient was enrolled in a prospective, randomized controlled trial investigating the effects of best treatment with or without clopidogrel in prevention of MBTS thrombotic occlusion (CLARINET Study). The clopidogrel was discontinued before urgent reoperation, when flow to the left lung was shown to be severely compromised. During surgery, shunt occlusion occurred with catastrophic results. Gross examination of the occluded graft showed a white granular clot. Subsequent histologic examination confirmed absence of fibrin thrombus, suggesting that the clot was predominantly platelet in origin.

The addition of clopidogrel to aspirin has been shown to reduce cardiovascular risk in adult patients with acute coronary syndrome undergoing percutane-

ous coronary intervention (PCI). However, Ho and colleagues [1] reported recently that sudden clopidogrel cessation in a cohort of patients with acute coronary syndrome treated medically or with PCI was followed by a clustering of adverse cardiovascular events. This study has raised the possibility that the early benefit of clopidogrel treatment in these patients may be counterbalanced by a rebound hypercoagulable effect after discontinuation of the drug [7]. This clinical observation may be supported by pharmacologic evidence. An increase in the expression of activation markers in adenosine diphosphate-stimulated platelets has been observed in healthy volunteers after clopidogrel discontinuation [8].

No conclusions regarding cause and effect can be drawn from our case report. However, in light of the observations in the adult literature, patients who require clopidogrel cessation should be carefully managed and followed. This therapy needs to be evaluated with randomized trials extending far beyond clopidogrel cessation in order to determine whether early benefits are counterbalanced by later adverse events associated with hypercoagulability following discontinuation of the drug. This evaluation has already been started by a modification in the CLARINET study, with long-term outcomes being measured.

A.P. was Chief Investigator for United Kingdom for the CLARINET study (<http://clinicaltrials.gov/ct2/show/NCT00833703>), examining the benefits of clopidogrel in addition to aspirin in children after Modified Blalock-Taussig shunt.

References

1. Ho PM, Peterson ED, Wang L, et al. Incidence of death and acute myocardial infarction associated with stopping clopidogrel after acute coronary syndrome. *JAMA* 2008;299:532–9.
2. Li JS, Yow E, Berezny KY, et al. Clinical outcomes of palliative surgery including a systemic-to-pulmonary artery shunt in infants with cyanotic congenital heart disease: does aspirin make a difference? *Circulation* 2007;116:293–7.
3. The Information Centre: Central Cardiac Audit Database. Available at <http://www.ccad.org.uk/congenital>. Accessed June 13, 2011.
4. McKay R, de Leval MR, Rees P, Taylor JF, Macartney FJ, Stark J. Postoperative angiographic assessment of modified Bla-

lock-Taussig shunts using expanded polytetrafluoroethylene (Gore-Tex). Ann Thorac Surg 1980;30:137–45.

5. Tamisier D, Vouhe PR, Vernant F, Leca F, Massot C, Neveux JY. Modified Blalock-Taussig shunts: results in infants less than 3 months of age. Ann Thorac Surg 1990;49:797–801.
6. Ahmad U, Fatimi SH, Naqvi I, et al. Modified Blalock-Taussig shunt: immediate and short-term follow-up results in neonates. Heart Lung Circ 2008;17:54–8.
7. Cundiff DK. Benefit of clopidogrel for acute coronary syndrome and percutaneous coronary interventions in doubt due to rebound adverse events. Am J Cardiol 2008;102:248.
8. Weber AA, Braun M, Hohlfeld T, Schwippert B, Tschöpe D, Schrör K. Recovery of platelet function after discontinuation of clopidogrel treatment in healthy volunteers. Br J Clin Pharmacol 2001;52:333–6.

Modified Starnes Procedure in a Neonate With Severe Tricuspid Regurgitation

Ashok Muralidaran, MD, Richard W. Kim, MD, Gary S. Kopf, MD, Nicholas P. Pietris, MD, Bevin P. Weeks, MD, Vaughn A. Starnes, MD, and Toshiharu Shinoka, MD, PhD

Section of Pediatric Cardiovascular Surgery, Yale University School of Medicine, New Haven, Connecticut; Section of Cardiothoracic Surgery, University of Southern California Keck School of Medicine, Los Angeles, California; and Section of Pediatric Cardiology, Yale University School of Medicine, New Haven, Connecticut

We report a modification of the Starnes technique for palliating severe tricuspid regurgitation associated with a dysplastic right ventricle in a neonate, using a fenestrated pericardial patch allowing for unidirectional flow. The patient eventually underwent a successful Glenn shunt construction with a persistent reduction in right ventricle size at 1 year follow-up.

(Ann Thorac Surg 2012;93:658–9)

© 2012 by The Society of Thoracic Surgeons

Infants born with a dysplastic right ventricle, pulmonary atresia, and severe tricuspid regurgitation present a significant surgical challenge in the neonatal period. This includes patients with Ebstein anomaly as well as a variety of other tricuspid valve and right ventricle (RV) anomalies. Starnes and colleagues [1] described a palliative approach in neonates with Ebstein anomaly in whom the pulmonary blood flow is supplied by a systemic to pulmonary artery shunt and the tricuspid orifice is closed with a pericardial patch [1]. This approach was taken to prevent tricuspid regurgitation into the right atrium. The original technique did not decompress the RV, but a subsequent modification with a fenestrated patch allowed for it [2]. We describe a further modification using a fenestration with a one-way flap valve that

limits RV filling while allowing decompression, thus encouraging shrinkage of the deformed RV.

A full-term female neonate (3.1 kg) with a prenatal diagnosis of severe tricuspid regurgitation, pulmonary atresia, and RV dysplasia was referred for surgical palliation with a ductal dependant pulmonary blood flow. There were no coronary to RV fistulae.

An echocardiogram performed on the day of birth confirmed the severe tricuspid regurgitation with elevated RV pressures. The study also revealed a patent ductus arteriosus with left-to-right shunt, an atrial septal defect and pulmonary atresia with severely hypertrophied outflow portion of a dilated RV. The branch pulmonary arteries were small but confluent. The septal leaflet was noted to be “tacked down” with a restrictive motion. The mitral and aortic valves appeared normal. The chest radiograph revealed a cardiothoracic ratio of 0.95 with a massive right atrium. The baby was hemodynamically stable on prostaglandin infusion with a systemic saturation of 88% on 21% oxygen.

The patient was taken to the operating room on day 6 of life. Upon opening the right atrium on bypass with standard bicaval cannulation, the tricuspid valve was severely deformed with myxomatous leaflets and severe tricuspid regurgitation. The right atrium measured 10 cm.

Fresh autologous pericardium was harvested, sized to the tricuspid orifice, and fenestrated with a 4-mm aortic punch. By suturing a smaller pericardial patch along three sides of the fenestration, we created a one-way flap valve preventing antegrade flow into the right ventricular chamber while allowing retrograde right ventricular decompression (Fig 1). The entire pericardial patch was then sutured to the tricuspid annulus, with the medial portion being sutured to the septal leaflet to avoid the conduction system. In addition, we performed an atrial septectomy, right atrial reduction, transection of the main pulmonary artery followed by PA plasty with a homograft patch, and placement of a right-sided modified Blalock-Taussig (BT) shunt with a 4-mm Polytetrafluoroethylene graft. The patient had an uneventful postoperative course and was discharged home on postoperative

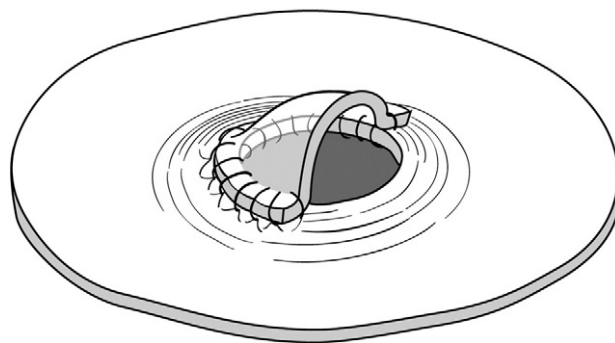


Fig 1. The modified patch with a one-way flap valve covering the 4-mm fenestration.

Accepted for publication July 12, 2011.

Address correspondence to Dr Shinoka, Section of Pediatric Cardiovascular Surgery, Yale University School of Medicine, 333 Cedar St, Rm 204, Boardman 2, PO Box 208039, New Haven, CT 06520; e-mail: toshiharu.shinoka@yale.edu.